

Comparative Evaluation of Remaining Dentinal Thickness in Three Different Conservative Access Preparation Techniques in Mandibular Molars using C.B.C.T.

¹Dr. Abeer Mishra, Dept. of Conservative dentistry and endodontics, Sarad pawar dental collage and hospital, Datta meghe institute of higher education and research.

²Dr. Shweta Sedani, Associate professor, Dept. of Conservative dentistry, and endodontics, Sarad pawar dental collage and hospital, Datta meghe institute of higher education and research.

³Dr. Utkarsh Umre, Dept. of Conservative dentistry and endodontics, Sarad pawar dental collage and hospital, Datta meghe institute of higher education and research.

⁴Dr. Simran kriplani, Dept. of Conservative dentistry and endodontics, Sarad pawar dental collage and hospital, Datta meghe institute of higher education and research.

⁵Dr Sanjana Bhargava, MDS (Pediatric & Preventive Dentistry), Private Practitioner and Consulting Pedodontist, Bhopal (M.P.)

⁶Dr. Madhuri Mahadeo Nikam, Assistant professor department of pediatric and preventive dentistry Tatyasaheb kore Dental College and Research Centre, New Paragon Maharashtra

Corresponding Author: Dr. Abeer Mishra, Dept. of Conservative dentistry and endodontics, Sarad pawar dental collage and hospital, Datta meghe institute of higher education and research.

Citation of this Article: Dr. Abeer Mishra, Dr. Shweta Sedani, Dr. Utkarsh Umre, Dr. Simran kriplani, Dr Sanjana Bhargava, Dr. Madhuri Mahadeo Nikam, “Comparative Evaluation of Remaining Dentinal Thickness in Three Different Conservative Access Preparation Techniques in Mandibular Molars using C.B.C.T.”, IJDSIR- April - 2023, Volume – 6, Issue - 2, P. No. 13 – 23.

Copyright: © 2023, Shreyas Shahid, et al. This is an open access journal and article distributed under the terms of the creative commons’ attribution non-commercial License. Which allows others to remix, tweak, and build upon the work non-commercially, as long as appropriate credit is given and the new creations are licensed under the identical terms.

Type of Publication: Original Research Article

Conflicts of Interest: Nil

Abstract

The study aimed to evaluate the remaining dentin thickness in the peri-cervical region after different access cavity preparations. The study included 30 extracted mandibular molars which were divided into three groups (n=10) based on the access cavity preparation technique. Group I received a conservative access preparation using the Clark and Khademi technique, while Group II and III

received the same treatment with the ninja technique and truss preservation technique, respectively. CBCT scans were taken before and after access cavity preparation to measure the dentin thickness. The data was statistically analyzed using SPSS version 24.0, and one-way ANOVA with post hoc analysis was used to compare the mean differences between the groups. The results showed that the conservative access preparation had the

highest mean value of 15.79 ± 4.1 , followed by the truss preservation technique with a mean value of 10.12 ± 3.8 and the ninja technique with the lowest mean value of 8.0 ± 3.7 . There was a statistically significant difference between the three groups ($p=0.001$). This study concluded that the conservative access cavity preparation technique may be preferred over the other techniques as it preserves the most dentin thickness in the peri-cervical region.

Introduction

Mandibular first molars are by far the most affected tooth by carious lesions¹. Toxins leaching out through dentinal tubules due to carious lesions can devitalize the pulpal tissue¹⁻³. Molars being most actively engaged in grinding, are most susceptible to attrition. Many a time, these cases need intentional root canal therapy⁴. Either because low-grade chronic inflammation has devitalized the pulp tissue or because of prognostic concerns³.

Traditionally access opening would mean gaining “straight-line access” to the canal orifice. This means completely “de-roofing” the pulp chamber and making a cavity diverging from the pulp floor⁴. It was believed that this would facilitate optimal root canal cleaning, shaping, and orifice location¹. Unrelated to the objective, extensive removal of healthy tooth structure to gain straight-line access to the canal orifice seems unnecessary.

This idea of conservative access opening was first put forward by **Dr. David Clark and Dr. John khademi** in the early 2000s⁶. The advent of operating microscopes in dentistry (OM), digital imaging and planning modalities, modern nickel-titanium instruments, and innovative irrigation systems has made this idea very realistic. Magnification has become an indispensable part of endodontic practice, not just for visualizing the operating area but also for diagnosis and treatment planning.

Dental loupes with at least 3.5 X Magnification, dental operating microscopes are recommended to optimize the pulp floor colour change and orifice locating ability^{7,8}. It has been found that human eyes are most likely to miss the subtle colour changes and some minuscule phenomena (e.g., gas released from dissolving organic tissue, accumulation of debris around the root canal orifice, etc.) that are crucial for canal location⁸. Dental operating microscopes and loops also aid the ergonomics and ease of working and reduce the risk of cervical spondylosis in practitioners^{9,10}.

Digital imaging enables clinicians to view the radiographic image in the magnified aspect, which is impossible with film X-rays⁴. Digital imaging can capture the finer details with lower radiation dosage^{11,12}. Post-processing of images is also a significant advantage of digital imaging. Adjustments in contrasts, shadows, highlights, tint, white balance, and 3D rendering and slicing enable the clinician to enhance the image quality to better view the area of interest. The software used to view these images are in-built with tools to improve visual quality and aid measurement of lengths and angles. Some specialized software is also designed to fabricate the models to enhance treatment accuracy¹³.

Radiographic digital imaging modalities include Photon stimulated plates (PSP), Radiovisiography (RVG), “Cone-beam computed tomography (CBCT), and micro-computed tomography (micro-CT)”. PSP or RVG is used to obtain 2D images. However, CBCT and micro-CT provide more details in multiple planes (3). Using CBCT in regular practice poses an ethical dilemma because of the increased radiation dosage¹⁴.

Root canal therapy is intended to preserve tooth structure by complete disinfection of complex canal anastomosis, followed by rehabilitation while preventing reinfection². Researchers found that mechanical cleaning is

insufficient to render a canal infection free¹⁵. File systems subjected to testing could not touch most canal surfaces. Thus, irrigation is essential to dissolve the organic tissue untouched by file systems¹⁶. Irrigation solutions are also crucial in lubricating the canal and killing microbes³. However, the ability of irrigants to reach the apical third is questionable. The capillary effect of canals prevents irrigation from reaching the apical third and lateral canals¹⁷.

Novel irrigation systems enable the irrigant to reach these hard-to-reach areas and enhance antimicrobial and tissue dissolving ability. Sonic and ultrasonic activation of irrigants was more effective than manual agitation in rinsing the apical third¹⁸.

The objective of the conservative design is 3D soffit and peri cervical dentine (PCD) preservation. Soffit is a term adopted from architecture, which means the ventral aspect of an architectural structure e.g. the downside of a roof. In endodontology, the soffit represents the ventral aspect of the pulp chamber roof. PCD is dentine adjacent to crestal bone, or cemento-enamel junction or pulp floor, 4mm above and 4mm below the reference point¹⁹. Studies have shown that teeth treated with conservative access openings show better biomechanical performance^{19,20}. It was found that conservative access openings improved fracture resistance of teeth significantly than that associated with the traditional method. However, pulp space cleaning ability remained unaffected by this change in the access design. Decreased bonded area of post-endodontic restoration also reduced the microleakage in vitro²¹.

These advantages encouraged clinicians and researchers to constrict the access opening design further. Thus, Ninja (ultra-conservative) access and truss access cavity were introduced. Truss endodontic cavity is designed to preserve the tooth structure by accessing mesial and

distal canals separately and leaving a truss of tooth structure in between²². Studies evaluating fracture confrontation potential of teeth treated with truss endodontic access cavities show a substantial increase in fracture resistance compared to conventional design of access cavities²³. Moreover, the design of access seemingly has no influence on canal locating and even mid-mesial canal discovering abilities²⁴. No adverse effects on canal cleaning and shaping ability were observed when truss access design is prepared²². Canal shaping and cleaning ability are studied in terms of the percentage of canal walls untouched, centering ability, apical transportation, and debris extrusion^{23,24}. However, fracture resistance is reduced if the marginal ridge is missing, and the difference becomes insignificant²⁰. The aim of this study is to compare the influence of three techniques of access cavity preparation on the remaining dentinal thickness at peri cervical area both before and after access cavity preparations by CBCT imaging.”

Methodology

A total of 30 mandibular molars extracted due to prosthodontic or periodontal concerns were obtained (figure. 2). The inclusion criteria were mandibular first molars without prior restoration or crack lines, and the exclusion criteria were extensively carious, previously restored, or fractured teeth, as well as those with internal or external resorption.

The 30 extracted mandibular molars were disinfected with 5.25% sodium hydrochloride and stored in formalin until the day of the study. Pre-treatment CBCT was performed to measure the dentinal thickness in the peri-cervical region (figure.4). The samples were divided into three groups (n=10) according to the access cavity preparation: Group I with a conservative access preparation using the Clark and Khademi technique under 30X magnification of a microscope and patented

with #8-K and #10-K files; Group II and III received the same treatment as Group I except for access preparation using the ninja technique and truss preservation technique respectively (figure.3).

The CBCT (Planmeca ProMax 3D) was used to scan each tooth. Before access cavity preparation, the image was kept in a small field of view (8×8 cm) at 90 kVp and 6.5 mA for 12 seconds with a 200 μm voxel size to determine the morphology of the pulp chamber. After the access cavity preparation, post-treatment CBCT was performed to measure the remaining dentinal thickness at the peri-cervical region. The percentage of volume lost in all three access preparation techniques of tomograms was selected for each sample(figure. 5,6,7.)



Figure 3

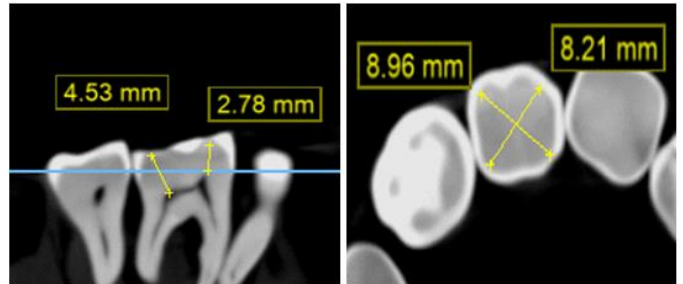


Figure 4



Figure 1

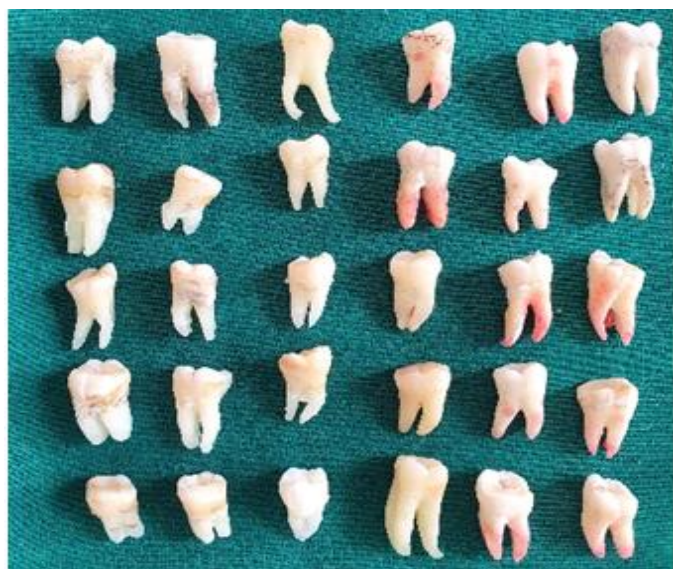

Figure 2

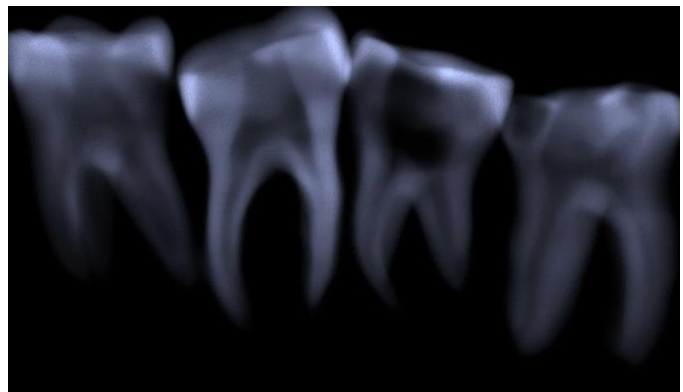


Figure 5

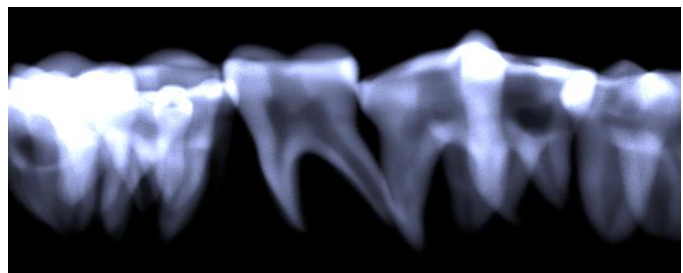


Figure 6

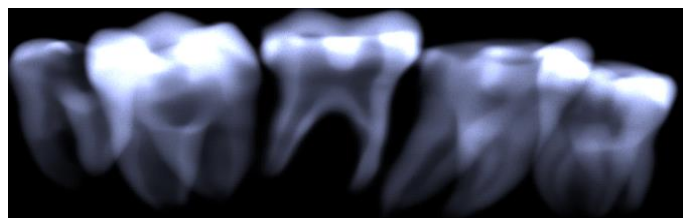


Figure 7

Statistical Analysis

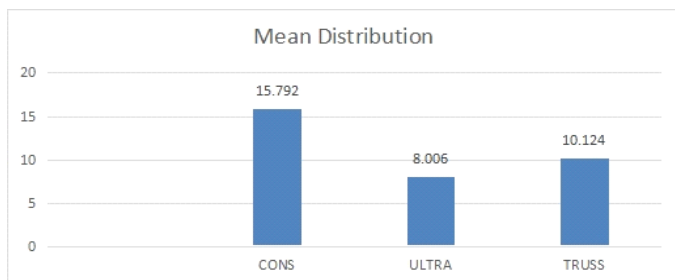
“Statistical Analysis was done in SPSS version 24.0 The descriptive statistical analysis was done for mean and standard deviation values. Intergroup comparison was done with One way Anova and post hoc analysis parametric test was used for assessing the mean difference. A statistical significant level was kept at $p < 0.05$ ”.

Results

Groups	N	Mean	Std. Deviation	Std. Error	95% Confidence Interval for Mean	
					Lower Bound	Upper Bound
					CONS	10
ULTRA	10	8.0060	3.71366	1.17436	5.3494	10.6626
TRUSS	10	10.1240	3.85484	1.21901	7.3664	12.8816
Total	30	11.3073	5.04264	.92066	9.4244	13.1903

Table1: Mean distribution of the groups

Table 1 represents the mean distribution of the groups as follows, in which conservative, ultra-conservative and truss has the mean of 15.79 ± 4.1 , 8.0 ± 3.7 , 10.12 ± 3.8 respectively. Maximum mean was observed in Conservative followed by truss and ultra-conservative group.



Graph 1: Mean distribution of Conservative, Ultra-conservative and Truss

	Sum of Squares	Df	Mean Square	F	Sig.
Between Groups	324.113	2	162.057	10.587	.001*
Within Groups	413.305	27	15.308		
Total	737.418	29			

Table 2: Inter Group Evaluation Between The Groups

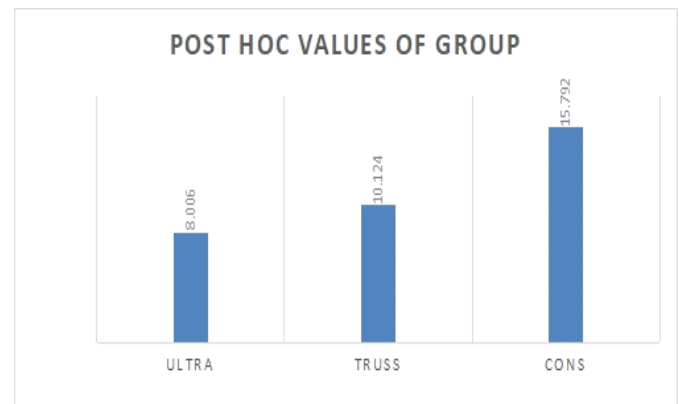
Table 2 represents the inter group evaluation between all the three groups.

“*P value, highly statistical significant difference was observed at 0.001’

“On intergroup comparison there was a highly statistical significant difference that was observed between the groups at $p = 0.001$. The F value evaluated is 10.58 with a mean square of is 162.05. There is a significant difference observed between the groups.”

Table 3: The Post Hoc Tukey Analysis of Intergroup Comparison

GROUPS	N	Subset for alpha = 0.05	
		1	2
ULTRA	10	8.0060	
TRUSS	10	10.1240	
CONS	10		15.7920
P value		.457	1.000



Graph 2: Post Hoc analysis of Ultra-conservative, Truss and Conservative group

“On post hoc analysis the Ultra-conservative, Truss and Conservative group values were observed to be 8.0, 10.12 and 15.79 respectively at subset for alpha 0.05. There was no significant difference observed. On analysis, Conservative group has the maximum value followed by Truss and Ultra-conservative.”

Discussion

The three vital steps in endodontic therapy comprises of biomechanical instrumentation, complete disinfection, as well as hermetic sealing of the canal space. The design

of access cavity preparation should be such that it facilitates linear access to the apex in straight canals and to the first curvature in curved canals¹.

The traditional access design provides an outward flare or a straight path up to the apex of a tooth². The constant emphasis on the conservancy or minimal removal of natural tooth assembly led to the introduction of modified access preparations⁵. Clark and Khademi in the early 2000s advanced the access cavity design by minimally removing and preserving the natural tooth structure. The objective of this design was 3D soffit and peri-cervical dentine preservation¹⁸. Another approach to a conservative access cavity was to prepare separate cavities to approach the canals. This orifice-directed design is termed a “Truss” access cavity. These access cavities leave a corbel of dentinal structure amid the two cavities access that have been prepared²². One more approach where the access cavity outline diagonal projection is prepared near the central fossa of the root orifices in an occlusal plane was introduced. In this cavity design, the access is analogous with the enamel cut perpendicular or greater angulation to the occlusal axis making it easier to find the openings of the root canal even from the dissimilar visual angulations⁵.

Traditional design of access to pulp chamber prepared significantly compromises tooth structure in the peri-cervical dentin region. Modified access preparations conserve the dentin in the peri-cervical region that (extends “4 mm above and 4 mm apical to the crestal bone”). Dentinal tissue preservation improves fracture resistance thereby improving the long-term prognosis of a tooth³⁴.

Root canal therapy is intended to preserve tooth structure by complete disinfection of complex canal anatomy, followed by rehabilitation while preventing reinfection². However, the chemo-mechanical preparation weakens

the tooth structure²². It is due to gross reduction of natural tooth structure. To overcome this shortcoming of root canal therapy conservative designs were proposed. The objective of the conservative design is 3D soffit and peri cervical dentine (PCD) preservation. Peri-cervical dentine is dentine adjuvant to crestal bone, cemento-enamel junction or pulp floor, 4mm above and below the reference point¹⁸. Studies have shown that teeth treated with conservative access openings show better biomechanical performance. It was found that conventional access opening increased fracture resistance of teeth significantly when compared with the traditional method^{28,29,31,33}. However, pulp space cleaning ability remained unaffected by this change in the access design^{14,22,24}. Decreased bonded area of post-endodontic restoration also reduced the microleakage in vitro²¹.

These advantages encouraged clinicians and researchers to constrict the access opening design further. Thus, Ninja (ultra-conservative) access and Truss access cavity were introduced^{25,30,35}. Truss endodontic cavity is designed to retain the natural, unaffected tooth structure by accessing mesial as well as distal canals separately and leaving a truss of tooth structure in between²⁶. Studies evaluating resistance to mechanical failure of teeth treated with truss design of endodontic access cavities show a noteworthy increase in fracture resistance compared to traditional design of access cavities. Moreover, the design of access cavity seemingly has no impact on canal locating and even mid-mesial canal discovering abilities^{36,37}. No adverse effects on canal cleaning and shaping ability were observed that was truss access design dependent. Canal shaping and cleaning ability are studied in terms of the percentage of canal walls untouched, centering ability, apical transportation, and debris extrusion^{14,24,38}.

The present study evaluated the impact of three distinct designs of the access to pulp chamber prepared, that is “conservative access cavity, Truss access cavity, and ultra-conservative access cavity”, on the volumetric loss of dentinal structure at peri cervical area. The access cavity was prepared under the magnification placing the tooth mounted on a wax rim at an angle to achieve a precision that simulates clinical situations. Ergonomic posture was maintained throughout the procedure. Use of magnification is must when a conservative access is planned. **Gabriela Rover et al.** showed that there is increased incidence of missing canals when ultrasonics and magnification aids is not used³⁷. CBCT produces more accurate three-dimensional imaging of the maxillofacial skeletal structures at a radiation dose pointedly lesser than traditional CT scans. They are more accurate to access the morphologies of tooth and root canals¹¹. The CBCT imaging system and software were utilised to evaluate the structure loss. CBCT provides precise three-dimensional information reducing the chances of iatrogenic damage along with tools of measurement built into the software¹².

Mandibular molars were selected for the study as they are the teeth most affected by caries and wasting and most frequently require root canal treatment³⁹. They also are teeth most frequently encountered with vertical root fracture after receiving root canal treatment.

The burs that were chosen for this study were endoguide burs as recommended by Dr David Clark and Dr John Khademi. These burs cause minimal amputation of tooth structure and also decrease chances of gauging¹⁸.

In our study the mean value of peri-cervical dentine in conservative group was found to be 15.79 , in Truss group it was found to be 10.12, while in ultraconservative group 8.00. This revealed that maximum mean was observed in conservative group

subsequent to truss group and further followed by ultra-conservative group.

Saeed et al pointed out current evidence available in the literature is insufficient to ascertain the superiority of a cavity design³¹. Hence this research was planned to explore and estimate the conservative nature of the designs of access when prepared with Endo guide burs.

Our study generated evidence that is comparable to findings of **Reddy et al.** and **Santosh et al.** Ultraconservative design and truss access design is much more efficient than conservative access design in conserving peri-cervical volume of dentinal tissue^{33,33}. The mean difference of Conservative group with Ultraconservative group and Truss group is 7.7 and 5.6 respectively with a statistically significant difference observed at $p < 0.05$. A vastly noteworthy variance was seen between Conservative group and Ultraconservative group with p-value at 0.001. The mean difference between Ultraconservative group and Truss groups was 2.1 in which no statistically noteworthy variance has been detected at $p < 0.05$.

Traditional straight-line access was taught to facilitate optimal root canal cleaning, shaping, and orifice location(1–3). This belief was only true when magnification aids and flexible instruments were not introduced to dentistry^{6,7}. Unrelated to the objective, extensive removal of healthy tooth structures to obtain linear approach to the canal orifice seems unjustified, more particularly in this modern era.

Outcomes of our research are also in accordance with the results of **Patil et al.** who demonstrated no significant variation in resistance to fracture between truss endodontic access cavity and ultra conservative endodontic access cavity designs. The reason behind this being, similarity in cross sectional area and volume of access cavity design⁴⁰.

On contrary to our results **Dan wang et al.** demonstrated that guided access to pulp chamber cavity group caused most dentine preservation followed by conservative access to pulp chamber cavity group and traditional endodontic access cavity group with statistical difference being insignificant in guided and conservative preparation of access cavity⁴¹.

Our findings are not in accordance with the results of **Sudarshan et al** who evaluated the volumetric loss of dentinal tissue in the peri-cervical region caused by traditional, truss, and conservative access cavities. Their result demonstrated significant difference statistically among all three groups³².

Researchers have demonstrated a lack of relationship between the volumetric loss of dentine at the peri-cervical area of the conservative access cavities and the ability of instruments to clean the canal. Even the centring ability is unaffected by the conservation of peri-cervical dentine. The ability of irrigation solutions to dissolve pulp tissue at various levels that is, at the coronal one-third, middle third and apical third of root canals, also remains unchanged by the conservation of pericervical dentine^{27,41}.

The most used techniques of irrigation include negative pressure irrigation, conventional positive pressure irrigation, activation of irrigants via laser and activation of irrigants via ultrasonics¹⁴.

Hajer M. Abd Elhamid demonstrated the ability of all these techniques in removing biofilm and opening up dentinal tubules remained unchanged by an increase in the peri-cervical width of dentine in conservative access designs²⁷.

Extrusion of debris along with irrigants during chemo-mechanical preparation has a negative correlation with the thickness of dentine at the peri-cervical area. A paper by **Jerry Joes et** published in **2020**, described the effect

of cavity design and type of irrigants on apical extrusion of debris. This study aimed to compare the conventional and conservative cavity design in terms of debris extrusion with different irrigants, i.e., 5.25% NaOCl solution or gel or distilled water. Statistical analysis of their study revealed debris extrusion. The conservation of dentine was significantly lesser than the traditional group, XP Finisher was markedly better than a shaper, and 5.25% NaOCl was considerably more significant than other groups. The reduced volume of irrigants is thought to be the cause of the decline in the extrusion of debris. All these findings imply that conserving peri-cervical dentine causes no detrimental effects²⁴.

While causing no detriment, an increase in the thickness of dentine at the peri-cervical area also results in superior biomechanical behaviour of teeth, a finite element analysis by **Jiang et al.** reported that reduction of dentinal structure at the peri-cervical site would increase the concentration of forces. This concentration of forces is very much likely to cause mechanical failure of the tooth, restorative material, or both⁴².

Conclusion

Within limitations of this study, it can be inferred that conservative access results in the least preservation of peri-cervical dentin when compared to ultra-conservative and truss access preservation techniques. While the values obtained from the truss access technique were marginally higher than those of the ultra-conservative technique, they were not statistically significant. Therefore, it can be concluded that the ultra-conservative technique caused the least damage to the tooth structure, followed by conservative access design. Consequently, the ultra-conservative access technique can effectively preserve the natural tooth structure and should be preferred whenever appropriate.

References

1. Ingle JI, Bakland LK, Baumgartner JC. Ingle's endodontics 6. 6th ed. Hamilton, ON, Maidenhead: BC Decker ; McGraw-Hill Education; 2008.
2. Chandra BS, Gopikrishna V, Grossman LI, editors. Grossman's endodontic practice. 13th edition. New Delhi: Wolters Kluwer; 2014. 551 p.
3. Hargreaves KM, Cohen S, Berman LH, editors. Cohen's pathways of the pulp. 10th ed. St. Louis, Mo: Mosby Elsevier; 2011. 952 p.
4. Setzer FC, Walsch H. Molar Access. The Guidebook to Molar Endodontics. 2017: p 117-31
5. Plotino G. Minimally Invasive Approaches in Endodontic Practice. Springer Nature; 2020. 233 p.
6. Low JF, Dom TNM, Baharin SA. Magnification in endodontics: A review of its application and acceptance among dental practitioners. Eur J Dent. 2018 Oct;12(04):610–6.
7. Arens DE. Introduction to Magnification in Endodontics. J EsthetRestor Dent. 2003 Dec;15(7):426–39.
8. Santos Accioly Lins CC dos, de Melo Silva EMV, de Lima GA, Conrado de Menezes SEA, Coelho Travassos RM. Operating microscope in endodontics: A systematic review. Open J Stomatol. 2013;03(09):1–5.
9. Plessas A, Bernardes Delgado M. The role of ergonomic saddle seats and magnification loupes in the prevention of musculoskeletal disorders. A systematic review. Int J Dent Hyg. 2018 Nov;16(4):430–40.
10. Raghav N, Reddy SS, Giridhar AG, Murthy S, Yashodha Devi BK, Santana N, et al. Comparison of the efficacy of conventional radiography, digital radiography, and ultrasound in diagnosing periapical lesions. Oral Surg Oral Med Oral Pathol Oral Radiol Endodontology. 2010 Sep;110(3):379–85.
11. Nair MK, Nair UP. Digital and Advanced Imaging in Endodontics: A Review. J Endod. 2007 Jan;33(1):1–6.
12. Shah P, Chong BS. 3D imaging, 3D printing and 3D virtual planning in endodontics. Clinical Oral Investigations. 2018 Mar;22(2):641-54.
13. Puskin JS. Perspective on the use of LNT for radiation protection and risk assessment by the US Environmental Protection Agency. Dose-Response. 2009 Oct 1;7(4):dose-response.
14. Souza E, Silva EJ, De Deus G, Versiani MA, Zuolo M. Scientific and Educational Aspects of Reciprocating Movement. Shaping for Cleaning the Root Canals: A Clinical-Based Strategy. 2022:215-48.
15. Metzger Z, Zary R, Cohen R, Teperovich E, Paqué F. The Quality of Root Canal Preparation and Root Canal Obturation in Canals Treated with Rotary versus Self-adjusting Files: A Three-dimensional Micro-computed Tomographic Study. J Endod. 2010 Sep;36(9):1569–73.
16. Zehnder M. Root Canal Irrigants. J Endod. 2006 May;32(5):389–98.
17. Vera J, Arias A, Romero M. Dynamic Movement of Intracanal Gas Bubbles during Cleaning and Shaping Procedures: The Effect of Maintaining Apical Patency on Their Presence in the Middle and Cervical Thirds of Human Root Canals—An In Vivo Study. J Endod. 2012 Feb 1;38(2):200–3.
18. Clark D, Khademi J. Modern Molar Endodontic Access and Directed Dentin Conservation. Dent Clin. 2010 Apr 1;54(2):249–73.
19. Saber SM, Hayaty DM, Nawar NN, Kim HC. The Effect of Access Cavity Designs and Sizes of Root

- Canal Preparations on the Biomechanical Behavior of an Endodontically Treated Mandibular First Molar: A Finite Element Analysis. *J Endod.* 2020 Nov;46(11):1675–81.
20. Plotino G, Grande NM, Isufi A, Ioppolo P, Pedullà E, Bedini R, et al. Fracture Strength of Endodontically Treated Teeth with Different Access Cavity Designs. *J Endod.* 2017 Jun;43(6):995–1000.
21. Karale R, Prathima B, Prashanth B, Shivaranjan N, Jain N. The effect of bulk-fill composites: Activa and Smart Dentin Replacement on cuspal deflection in endodontically treated teeth with different access cavity designs. *J Conserv Dent.* 2022;25(4):375.
22. Neelakantan P, Khan K, Hei Ng GP, Yip CY, Zhang C, Pan Cheung GS. Does the Orifice-directed Dentin Conservation Access Design Debride Pulp Chamber and Mesial Root Canal Systems of Mandibular Molars Similar to a Traditional Access Design? *J Endod.* 2018 Feb;44(2):274–9.
23. Ballester B, Giraud T, Ahmed HMA, Nabhan MS, Bukiet F, Guivarc'h M. Current strategies for conservative endodontic access cavity preparation techniques—systematic review, meta-analysis, and decision-making protocol. *Clin Oral Investig.* 2021 Nov;25(11):6027–44.
24. Jose J, Thamilselvan A, Teja KV, Rossi–Fedele G. Influence of access cavity design, sodium hypochlorite formulation and XP -endo Shaper usage on apical debris extrusion – A laboratory investigation. *AustEndod J.* 2022 Jun 9;aej.12637.
25. Corsentino G, Pedullà E, Castelli L, Liguori M, Spicciarelli V, Martignoni M, et al. Influence of Access Cavity Preparation and Remaining Tooth Substance on Fracture Strength of Endodontically Treated Teeth. *J Endod.* 2018 Sep;44(9):1416–21.
26. Abou-Elnaga MY, Alkhawas MBAM, Kim HC, Refai AS. Effect of Truss Access and Artificial Truss Restoration on the Fracture Resistance of Endodontically Treated Mandibular First Molars. *J Endod.* 2019 Jun;45(6):813–7.
27. Munihaier. Debridement Efficiency Of Different Irrigating Protocols In Truss Cavity Access Preparation. *Egypt Dent J.* 2020 Jul 1;66(3):1883–92.
28. Marinescu AG, Cîrligeriu LE, Boscornea SA, Horhat RM, SgîiaŞtefania T, Stoia DI, et al. FRACTURE STRENGTH EVALUATION OF TEETH WITH DIFFERENT DESIGNS OF ENDODONTIC ACCESS CAVITIES. 2020;12(2):9.
29. Saberi EA, Pirhaji A, Zabetiyan F. Effects of Endodontic Access Cavity Design and Thermocycling on Fracture Strength of Endodontically Treated Teeth. *Clin CosmetInvestig Dent.* 2020 Apr;Volume 12:149–56.
30. Lima CO, Barbosa AFA, Ferreira CM, Ferretti MA, Aguiar FHB, Lopes RT, et al. Influence of ultraconservative access cavities on instrumentation efficacy with XP-endo Shaper and Reciproc, filling ability and load capacity of mandibular molars subjected to thermomechanical cycling. *Int Endod J.* 2021 Aug;54(8):1383–93.
31. Saeed M, Al-Obadi M, Salim A, Alsawaf AY, Hadi K. Impact of Access Cavity Design on Fracture Resistance of Endodontically Treated Molars: A Systematic Review. *Clin CosmetInvestig Dent.* 2021 Jan;Volume 13:1–10.
32. Sudharsan G, Kamaraj P, Raguganesh V. CONE BEAM COMPUTED TOMOGRAPHIC EVALUATION OF FRACTURE STRENGTH OF MAXILLARY MOLARS WITH THREE

- DIFFERENT ACCESS CAVITY DESIGNS.-AN INVITRO STUDY. *International Journal of Dental and Clinical Study*. 2022 May 4;3(1):24-33.
33. Reddy Ng, Naga S, Manoj Kumar M, H Srinivas N, Mettu S, Animireddy D. Influence of access cavity design on the fracture resistance and root canal filling efficacy in simulated young permanent molars using cone-beam computed tomography: An in vitro study. *Endodontology*. 2020;32(3):130.
34. Silva EJNL, Pinto KP, Ajuz NC, Sassone LM. Ten years of minimally invasive access cavities in Endodontics: a bibliometric analysis of the 25 most-cited studies. *Restor Dent Endod*. 2021;46(3):e42.
35. Gambarini G, Galli M, Morese A, Stefanelli LV, Abduljabbar F, Giovarruscio M, et al. Precision of Dynamic Navigation to Perform Endodontic Ultraconservative Access Cavities: A Preliminary In Vitro Analysis. *J Endod*. 2020 Sep;46(9):1286–90.
36. Blauhut T, Sonntag D. Reliability of root canal orifice assessments using minimally invasive access cavities. *Endodontic Practice Today*. 2020 Oct 1;14(4):289-95.
37. Rover G, Belladonna FG, Bortoluzzi EA, De-Deus G, Silva EJNL, Teixeira CS. Influence of Access Cavity Design on Root Canal Detection, Instrumentation Efficacy, and Fracture Resistance Assessed in Maxillary Molars. *J Endod*. 2017 Oct;43(10):1657–62.
38. Giacomo C. Influence of Access Cavity Design on Fatigue Resistance of Reciproc Blue: Conservative vs. Truss Access. *Int J Oral Dent Health [Internet]*. 2021 Feb 10 [cited 2022 Nov 6];7(1).
39. Broadbent JM, Page LAF, Thomson WM, Poulton R. Permanent dentition caries through the first half of life. *Br Dent J*. 2013 Oct;215(7):E12–E12.
40. Patil P, Newase P, Pawar S, Gosai H, Shah D, Parhad SM. Comparison of Fracture Resistance of Endodontically Treated Teeth With Traditional Endodontic Access Cavity, Conservative Endodontic Access Cavity, Truss Endodontic Access Cavity, and Ninja Endodontic Access Cavity Designs: An In Vitro Study. *Cureus*. 2022 Aug 17;14(8).
41. Wang D, Wang W, Li Y, Wang Y, Hong T, Bai S, et al. The effects of endodontic access cavity design on dentine removal and effectiveness of canal instrumentation in maxillary molars. *Int Endod J*. 2021 Dec;54(12):2290–9.
42. Jiang Q, Huang Y, Tu X, Li Z, He Y, Yang X. Biomechanical Properties of First Maxillary Molars with Different Endodontic Cavities: A Finite Element Analysis. *J Endod*. 2018 Aug;44(8):1283–8.