

**Prosthetic Rehabilitation of Ocular Defects - A Review**

<sup>1</sup>Dr. Vikas B. Kamble, Professor and Head, Department of Prosthodontics, Crown and Bridge, P.M.N.M. Dental College and Hospital, Bagalkot, Karnataka, India.

<sup>2</sup>Dr. Raviraj G. Desai, Professor, Department of Prosthodontics, Crown and Bridge, P.M.N.M. Dental College and Hospital, Bagalkot, Karnataka, India.

<sup>3</sup>Dr. Kashinath C. Arabbi, Professor, Department of Prosthodontics, Crown and Bridge, P.M.N.M. Dental College and Hospital, Bagalkot, Karnataka, India.

<sup>4</sup>Dr. Danveera S. Raut Dessai, Postgraduate student, Department of Prosthodontics, Crown and Bridge, P.M.N.M. Dental College and Hospital, Bagalkot, Karnataka, India.

<sup>5</sup>Dr. Aparajita Lal, Postgraduate student, Department of Prosthodontics, Crown and Bridge, P.M.N.M. Dental College and Hospital, Bagalkot, Karnataka, India.

**Corresponding Author:** Dr. Vikas B. Kamble, Professor and Head, Department of Prosthodontics, Crown and Bridge, P.M.N.M. Dental College and Hospital, Bagalkot, Karnataka, India.

**Citation of this Article:** Dr. Vikas B. Kamble, Dr. Raviraj G. Desai, Dr. Kashinath C. Arabbi, Dr. Danveera S. Raut Dessai, Dr. Aparajita Lal, “Prosthetic Rehabilitation of Ocular Defects - A Review”, IJDSIR- December - 2020, Vol. – 3, Issue - 6, P. No. 472 – 483.

**Copyright:** © 2020, Dr. Vikas B. Kamble, et al. This is an open access journal and article distributed under the terms of the creative commons attribution noncommercial License. Which allows others to remix, tweak, and build upon the work non commercially, as long as appropriate credit is given and the new creations are licensed under the identical terms.

**Type of Publication:** Review Article

**Conflicts of Interest:** Nil

---

**Abstract**

Eyes are among the first features of the face to be noticed. Loss of eyes as a result of congenital defect, disease, accidental trauma or surgical intervention can have a significant physical, physiological, social and psychological impact on the patient. The ocular prosthesis is a modality of facial prosthesis that acts on the repair of loss or deformity of the ocular globe. The fabrication of ocular prosthesis with acceptable aesthetics and reasonable motility is crucial in restoring the normal appearance. The prosthesis prevents eyelid deformation, protects the anophthalmic cavity, orients the lacrimal

reflex and avoids accumulation in the cavity. This article presents the various techniques of impression making, iris repositioning and fabrication of prosthesis with modifications in compromised cases along with recent advancements for better comfort and aesthetics.

**Keywords:** Ocular, prosthesis, anophthalmic, impression, iris

**Introduction**

The eye is a vital organ in terms of vision and is also an important component of facial expression.<sup>[1]</sup> Congenital defects, severe trauma and tumor attribute to the loss of an

eye, and subsequent deformity. Surgical procedures adopted for the removal of an eye were classified by Peyman et al.,<sup>[2]</sup> into: evisceration, enucleation or exenteration. The evisceration and enucleation defects are rehabilitated using intraocular acrylic prosthesis whereas extra ocular silicone prosthesis are the mode of rehabilitation adopted in an exenteration defect.

An ocular prosthesis which restores and replaces the natural eye aims to improve the patient's esthetics, restore and maintain the health of the remaining structures and consequently provide physical and mental well-being for the patient.<sup>[3]</sup>

A fundamental objective when restoring an anophthalmic socket with an ocular prosthesis is to enable the patient to cope better with the difficult process of rehabilitation.<sup>[4]</sup> A multidisciplinary approach including a prosthodontist, ophthalmologist, surgeon and maxillofacial prosthetist should be considered for an aesthetic and stable outcome.<sup>[5]</sup>

Ocular prosthesis can be referred to variously as artificial eyes, molded eyes, cosmetic contact shells, cosmetic contact lens, spectacle prosthesis.<sup>[6]</sup> Ocular prosthesis is mainly of three types- stock ocular prosthesis, modified stock ocular prosthesis and custom-made ocular prosthesis. The fabrication process mainly comprises of impression making, formulation of mould, wax pattern fabrication, iris positioning, processing of prosthesis followed by characterisation and polishing of prosthesis. The purpose of this article is to review various techniques of fabrication of ocular prosthesis along with considerations in compromised cases and recent advances. All the data for the review are collected from Wolters Kluwer, Pubmed Central and Google Scholar published in the year 1944 to 2018 using keywords such as ocular, prosthesis, anophthalmic, impression and iris.

## Impression Techniques For Fabrication Of Ocular Prosthesis

The anophthalmic socket is anesthetized using anaesthetic eye drops. The patient is seated erect, requested to stare at a distant spot and is instructed to hold his gaze in a straight forward position with eyes open while the impression is being made. This procedure will ensure that the posterior aspect of the enucleated socket and its rectus muscles will be in the same relative position as those of the remaining eye.<sup>[7]</sup>

Some of the common impression techniques have been discussed.

### Direct / External Impression<sup>[8]</sup>

Several authors suggested technique in which low viscosity alginate or reversible hydrocolloid is injected directly into the enucleated socket.<sup>[9,10,11,12]</sup> The patient is instructed to stare straight ahead as the material sets. Additional material is applied to the external tissue, and an impression is made using a rigid tray for reinforcement. As a result, the anatomy of the anophthalmic socket and overlying tissues is obtained. (Figure1,2)

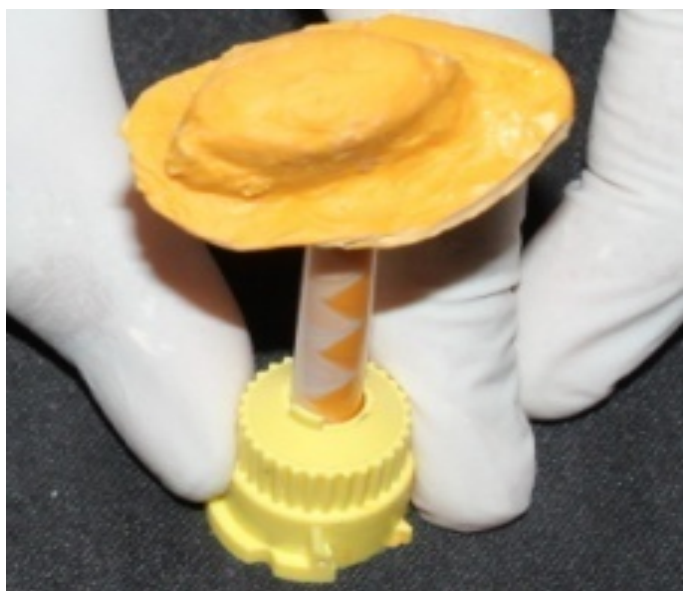

Figure 1



Figure 2

**Impression With Stock Ocular Tray<sup>[13]</sup>**

Allen and Webster suggested technique which is most commonly used. Plastic eye shells of suitable shapes are perforated and attached to a syringe using a hollow stem needle (needle cap) through which a runny mix of ophthalmic alginate (Moldite) is injected in the enucleated socket. The perforations in the eye shell aid in retention of the impression material. When the mix has set firmly, the shell and impression are removed from the socket, with care not to injure the socket or cause damage to thin areas of the impression. (Figure3,4)



Figure 3

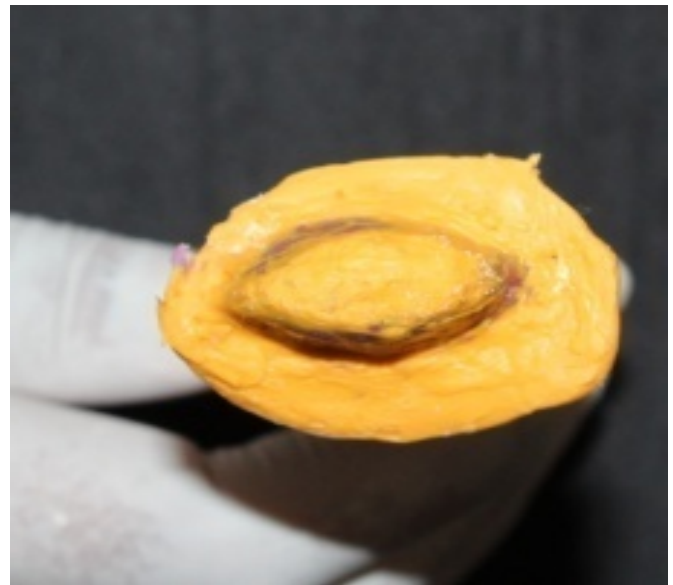

Figure 4

**Impression With Custom Ocular Tray<sup>[10,14]</sup>**

Miller suggested a technique in which the use of custom ocular tray is necessary in conditions where the anophthalmic sockets are highly irregular and stock trays are unavailable. It involves a clear acrylic resin tray with perforations and a tunnel in centre fabricated on the primary mold. Impression is made using medium body elastomeric impression material followed by wash impression with light body. (Figure5)



Figure 5

### IRIS Positioning

Positioning of the iris is an important step in fabrication of the custom-made ocular prosthesis, which helps achieve better aesthetics and self esteem of the patient. The literature suggests many techniques for positioning the iris on the ocular prosthesis. The iris should be bilaterally symmetrical, therefore accurate placement of the custom painted or stock iris disk on the sclera wax pattern is critical.<sup>[15]</sup> The conventional use of visual measurements, dividers, rulers, or calipers produces inaccurate results due to factors such as parallax and facial asymmetry.

### Robert Pupillometer<sup>[5]</sup>

Pupillometer, an instrument introduced in 1969 consists of two cylindrical tubes with parallel axes each containing a positive lens. The instrument is positioned on the patient by resting two plastic adjustable discs on the bridge of the nose. Scale markings are provided to ensure that both discs are rotated the same amount. The pupil of the patient's natural eye is observed through the circular apertures at the other end of the tubes which project to infinity by the lenses. The pupil serves as a fixation point for the patient. Each lens contains a graduated scale, with the zero of each scale situated at the vertical plane of symmetry of the instrument, relative to the axis of the patient's nose. Separate monocular measurement of each eye is achieved by operating a shutter. The apertures of the instrument are 4 mm in diameter which eliminates small parallax errors that may occur when the interpupillary distance of the clinician is different from that of the patient. (Figure6,7)



Figure 6

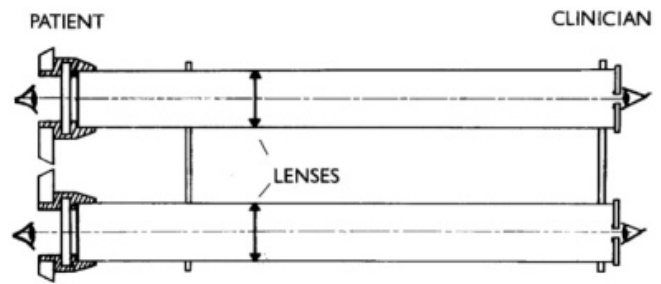


Figure 7

### McArthur Ocular Locator And Fixed Caliper<sup>[16]</sup>

An ocular locator is fabricated using a Plexiglas sheet with an opening in the centre for the nose. After trial placement of the locator on the patient's face, a vertical mid-sagittal mark is made on the forehead and chin where the scribed horizontal lines of the locator will intersect the vertical markings. The fixed caliper is used to determine the intersection of the horizontal lines with the mid-sagittal markings. The locator is placed so that the scribed lines on the locator are superimposed over the markings on the face. The anatomy of the eye is traced onto the surface of the locator with a grease pencil or water-soluble felt-tipped pen. The locator is turned 180 degrees on the midsagittal axis to produce its mirror image. The locator is placed on the stone moulage to aid in the correct placement of the eye. (Figure8)

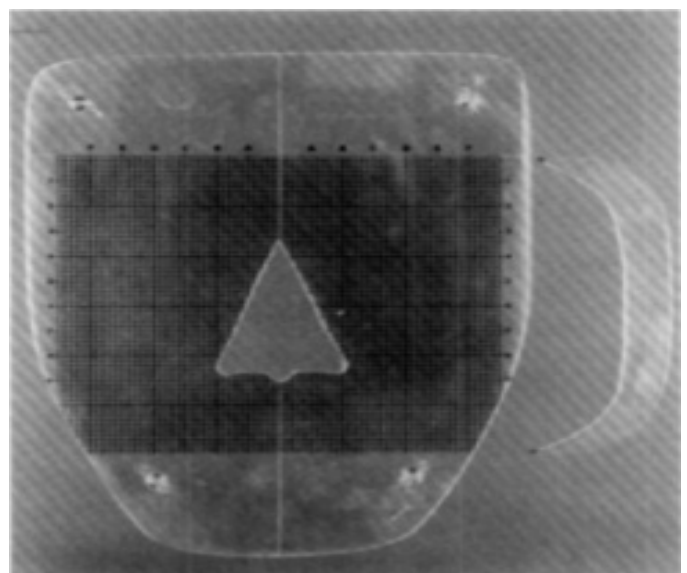


Figure-8

### Benson Visual Adjustment<sup>[17]</sup>

In 1977, Benson introduced a technique in which an iris button coinciding with the size of the iris of adjacent eye (range 11-13mm) is adjusted in the wax pattern to replicate the “normal gaze position”. The location for the iris button is marked with an “X,” and the iris button is attached to the wax form. The iris button is tried in and aligned. The sclera is removed, contoured with wax, and reinserted. If satisfactory, the model eye is removed and prepared for investing.

### Using Graph Grid Template<sup>[15]</sup>

In this technique, a transparent graph grid is used to attach the iris disk. During the trial of the sclera wax pattern, a vertical midline is marked passing through the forehead crease, glabella, tip of nose and chin. The distance from the medial canthus of both eyes to the midline is measured and marked to reposition the grid template each time during the try-in visit. The patient is asked to gaze at an object 4 feet away and superior and inferior, medial and lateral limits of the iris is marked. These markings are then transferred to the graph grid template, and from that the markings are transposed to the side of the defect. The markings are transferred onto the sculpted wax pattern, and the iris button is attached. (Figure9)

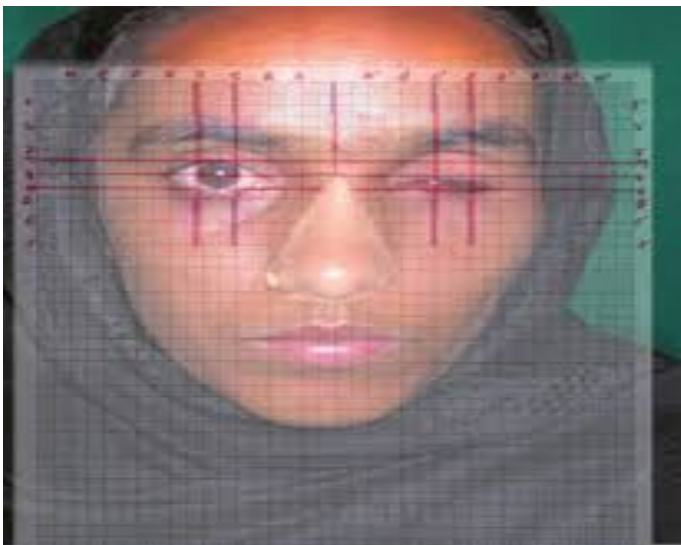

Figure 9

### Using Hanau Wide View Spring Bow<sup>[6]</sup>:

The Hanau wide-view spring bow is used for this technique. The U shaped frame of the Hanau spring bow should be reversed such that the orbital pointer is stabilized on the lower border of the ala of the nose. This standardises and stabilises the face bow and acts as the third point of reference. Next, the transfer clamp assembly of the face bow is attached to the reversed face bow frame. A metal graduated scale is cut to the exact width of the bite fork and is attached horizontally to the edentulous face bow fork with double sided tape. (Figure10) Two paper clips are placed as a rider on the scale for ease of measurement. The width and height of the iris of normal eye are recorded and the markings are transferred to the conformer in the defective eye. (Figure11)



Figure 10

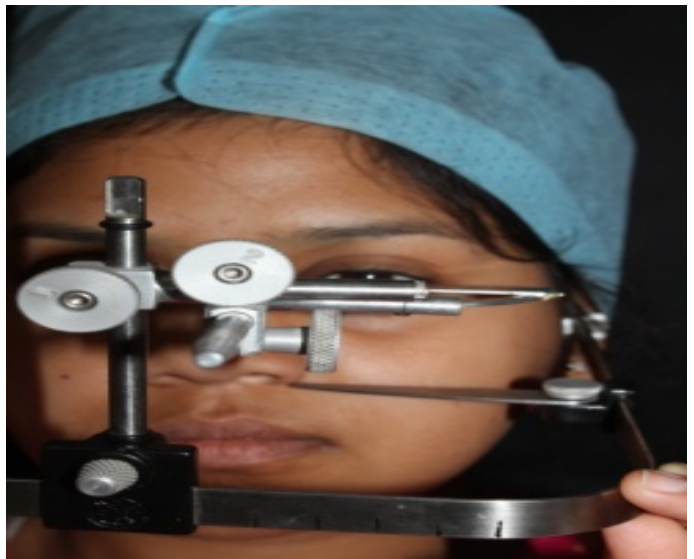

Figure 11

### Using Graph Grid Attached To Spring Bow<sup>[18]</sup>

A special assembly which consists of a heat cured acrylic resin frame with graph grid, attached to a hanau spring bow is attached to position the iris accurately. The frame is made with equal lines of graph grid on either side of the midline of the scale. The patient is placed in the aesthetic reference position and outline of the iris of the normal eye is traced on the graph grid. Markings are transferred to the wax conformer by flipping the graph grid on the defective side of patient using the markings on the spring bow to maintain symmetrical distance on either side. The iris disk from the stock eye is cut according to the measured dimensions and placed on the markings. (Figure12,13)




Figure 12

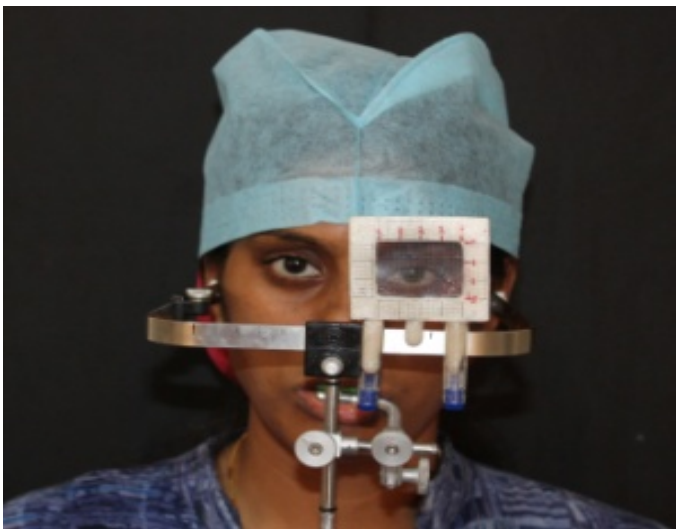


Figure 13

### Fabrication of Ocular Prosthesis

When the surgical site is well healed and dimensionally stable, fabrication of an ocular prosthesis can begin. Before beginning, a thorough examination of the enucleated socket must be made to ensure proper healing and the absence of infection. The movement of the tissue bed, and size and extent of the socket should be noted.<sup>[7]</sup> Techniques for making these ocular prostheses vary from simple to complicated. The various techniques are:

#### Stock Ocular Prosthesis<sup>[19]</sup>

Stock acrylic resin eyes are supplied in three shapes: oval, standard and three-cornered. Each shape has three sizes: small, medium and large, and can be prepared for the right or the left eye. The irises are produced in three basic colours: brown, hazel and blue, and the individual colours have been formulated so that they have some elasticity and overlapping quality in matching effects. The scleral colours are also varied. One basic size of iris (11.5 mm) is used, and it has a pupil opening of 3.5 mm. Where possible, the stock eye should be made to duplicate the superior fit and aesthetics of the custom eye as closely as possible. Advantage of the stock acrylic resin eye is its rapid fabrication and positioning to serve the patient while awaiting the custom-built ocular prosthesis and can also be used as a conformer or stent immediately post-operatively to aid in the re-growth and orientation of the tissues in the surgical area. The drawback of this type of prosthesis is poor apposition between the stock prosthesis and surface leading to unequal weight distribution, constant irritation and vaulted spaces in the cavity which further causes chronic discharge and laxity of the lower eye lid.<sup>[20,21]</sup> (Figure14)

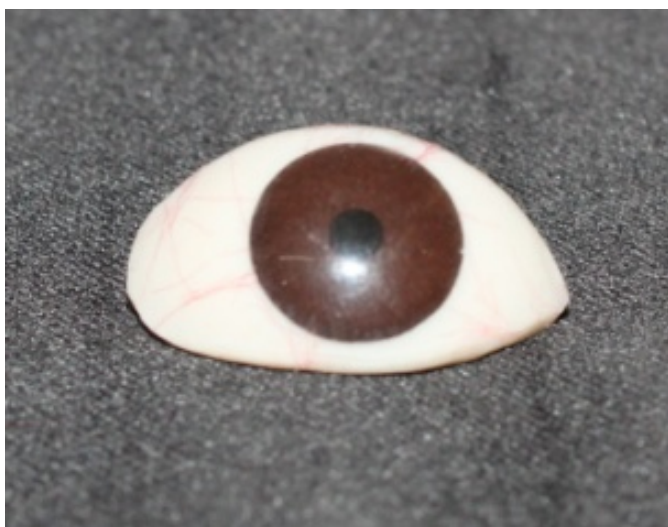

Figure 14

### Modified Stock Ocular Prosthesis<sup>[22]</sup>

This technique permits the prosthesis to generate an equal distribution of pressure throughout the defect, while increasing its movement due to excellent adaptation to the walls of the socket. In this technique, impression of the anophthalmic socket is made using a stock ocular prosthesis. The impression is invested in a two-piece mold using dental stone. Heat cured clear acrylic resin is packed in the mould and cured. Characterisation of the prosthesis is done followed by finishing and polishing to give a natural appearance. Prior to insertion the prosthesis is disinfected using 0.5% chlorhexidine and 70% isopropyl alcohol for 5 minutes. The limitation of modified stock ocular technique is the limited variations in iris size, colour and position.

### Custom Made Ocular Prosthesis<sup>[23]</sup>

In this technique, direct impression is made followed by impression using custom tray. The impression is poured using dental stone to obtain a two piece mold. Wax conformer is fabricated and tried in patient's anophthalmic socket. The size of the iris of the contra-lateral natural eye is measured and a customised iris button is made by painting or digital photography to match the contra-lateral eye. The iris is then positioned on the sclera blank. The

iris is covered by a layer of clear acrylic and the prosthesis is characterised and polished. (Figure15,16)

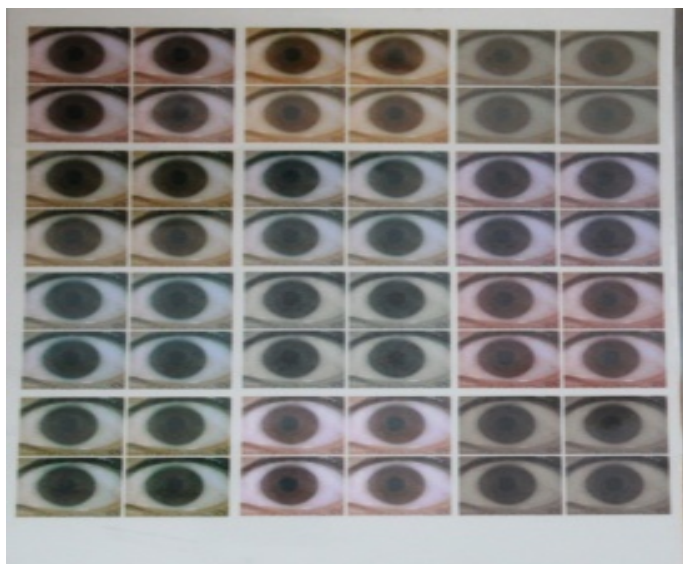


Figure 15

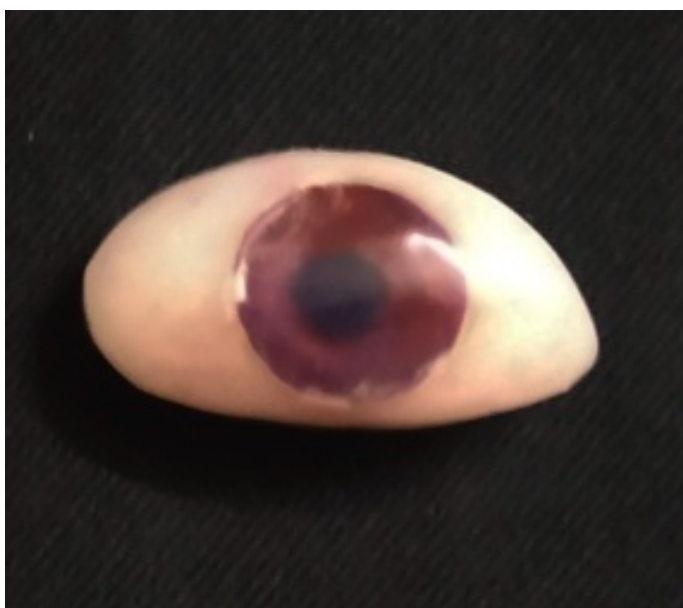

Figure 16

### Modifications In Compromised Cases

#### Post Enucleation Socket Syndrome<sup>[24]</sup>

Rehabilitation of an enucleated socket with an inappropriately sized prosthesis can result in superior sulcus deepening, enophthalmos, ptosis, ectropion and lower lid laxity which are collectively known as post enucleation socket syndrome.

Etiologies of post enucleation socket syndrome are atrophy of orbital fat, migration of muscle cone, traumatic bony loss, herniated orbital fat secondary to unrecognized orbital wall fracture, loss of volume when globe is removed, levator disinsertion, malposition of superior rectus muscle and long-standing gravitational burden of orbital implant and prosthesis. The loss of volume resulting from the removal of the eyeball is the chief cause. This condition can be managed by reducing the wax pattern on the anterior superior aspect to reposition the superior tarsal plate, correct ptosis and increase eye opening. Modelling wax is added on the anterior corneal area to support the upper eyelid and anterior inferior surface is reduced to lift lower eye lid. Modelling wax is added on the posterior superior surface to lift the margins of eye thus reducing the cosmetic disfigurements in the final prosthesis. (Figure17,18)

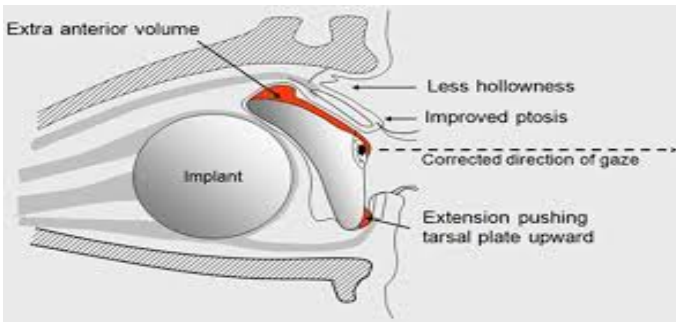


Figure 17



Figure 18

### Contracted Socket<sup>[25]</sup>

Contracted socket is defined as shrinkage of fornices of the eye. They are either congenital or acquired. Contracted socket can be classified as mild, moderate and severe and depends on the severity of shrinkage. Infection, cicatricial, conjunctival diseases, post enucleation radiation, absence or poor fitting conformer, absence or migration of implant, faulty technique of enucleation and evisceration, rotation of inferior tarsus, sagging of lower lid, cicatricial ectropion, pre-enucleation trauma (chemical, thermal burns), congenital condition all contribute to contracted socket. In contracted sockets with reduced volume, surgical expansion of the socket is the desired treatment. But when surgical correction is not possible alterations in the prosthesis can be made. Spectacles with magnified glass (10x or 15x) is used on the side of contracted socket to camouflage the asymmetry. (Figure19)



Figure 19

### Impaired Tear Reflex<sup>[26]</sup>

[Hollow Ocular Prosthesis with Lubricant Reservoir]

In patients with anophthalmic sockets, blinking and tearing reflexes are either absent or do not function at optimal levels leading to problems such as dryness, discomfort, irritation, bacterial infections, and mucous deposition in prosthetic wearers, all of which makes

prosthesis wear uncomfortable. Dry eye is a condition in which a person does not have enough quality tears to lubricate and nourish the eye. This condition can be managed by the hollow ocular prosthesis with functional lubricant reservoir which consists of a reservoir for the lubricant in the superior aspect of the body of the prosthesis. The lubricant reservoir is connected to an access opening on the posterior surface of the body by a passage. The prosthesis also has an exit hole for the lubricant, 0.5 mm in diameter on the anterior surface of the prosthesis. It opens into the limbus and it leads to the reservoir containing the lubricant. The hollow ocular prosthesis also improves comfort by reducing the weight of the prosthesis. (Figure 20,21)



Figure 20

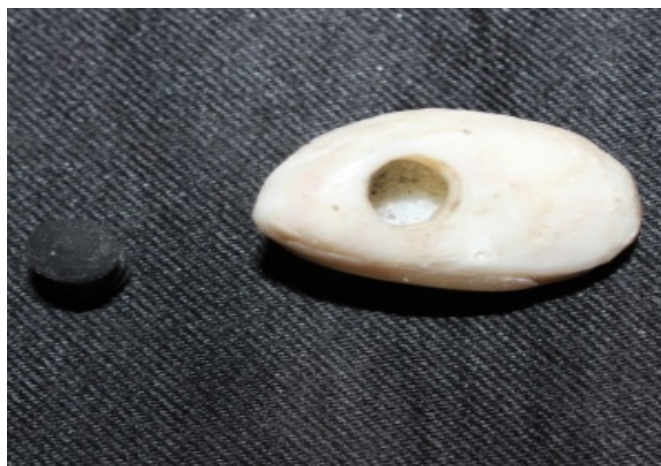

Figure 21

## Recent Advancements in Ocular Prosthesis

### Bionic Eye<sup>[27]</sup>

Bionic eye is an artificial retina device, with a miniature camera mounted in eye glasses captures images and wirelessly sends the information to a microprocessor (worn on a belt) that converts data into electrical signals and transmits it to a receiver on the eye. The receiver sends the signals through a thin cable to the microelectrode array stimulating it to emit impulse. The artificial retina device thus bypasses the photo receptor cells and transmits electrical signals directly to retina's viable cells. The pulses travel to the optic nerve and ultimately to the brain, which perceives patterns of light and dark spots corresponding to electrodes stimulated. (Figure 22)

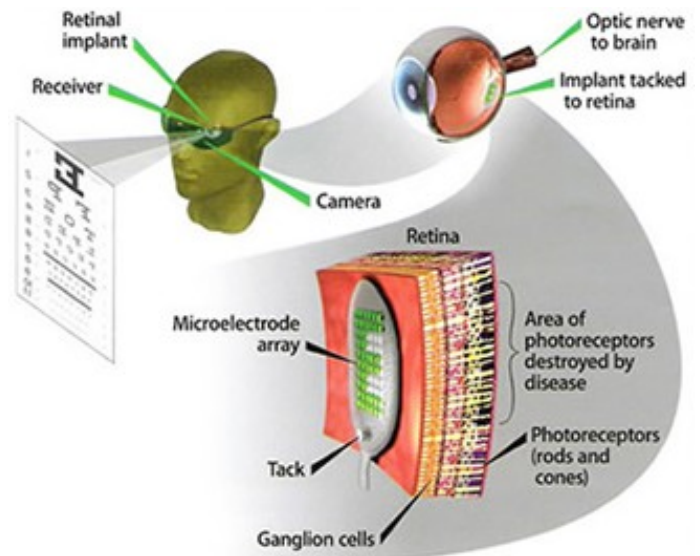


Figure-22

### CAD And Rapid Prototyping

This process provides quick, inexpensive, aesthetically and functionally superior ocular prosthesis. The direct and indirect techniques of fabrication by CAD and rapid prototyping are discussed below. (Figure23)

**Direct technique<sup>[28]</sup>:** A cone beam computerised tomography of the anophthalmic socket is done to obtain a 3D computer model. This design is exported to a STL

(Standard Tessellation Language) format and printed in resin by 3D printer. The printed prototype is used as working trial prosthesis. The iris is positioned and the processing is performed using standard way with duplication to polymethyl methacrylate prosthesis.

**Indirect technique<sup>[29]</sup>:** Initial accurate impression of the patient's eye socket is obtained to prepare a suitable wax model. After the try-in, the wax model is scanned and a 3D image is obtained. Input of the STL file is given to the rapid prototyping machine and the prototype is obtained. Iris positioning is done and the prosthesis is fabricated in a standard way.

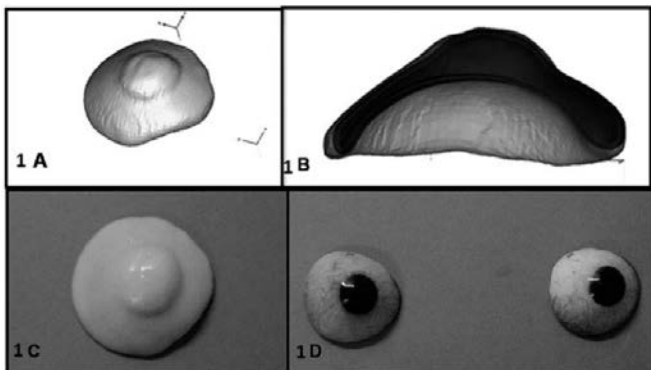


Figure 23

### Ocular Implants<sup>[7]</sup>

Most ocular defects result from trauma; occasionally tumors require removal of the eye. Frequently an implant is placed in the tissue bed to facilitate construction of the ocular prosthesis. If no material is used to help fill the space the orbit will exhibit a sunken appearance as the size of a prosthetic eye is limited by the opening between the superior and inferior palpebra.

If no implant is placed to which the ocular muscles can be connected, there will be no movement of the overlying prosthetic eye. An implant that is attached to the ocular muscles will move as the muscles move in their normal course. Consequently, a prosthetic eye in contact with the tissue that covers a moving implant will move as the muscles move in the eye in contact with the tissue that

covers a moving implant will have some degree of movement. The result will be a more realistic prosthesis. (Figure 24)

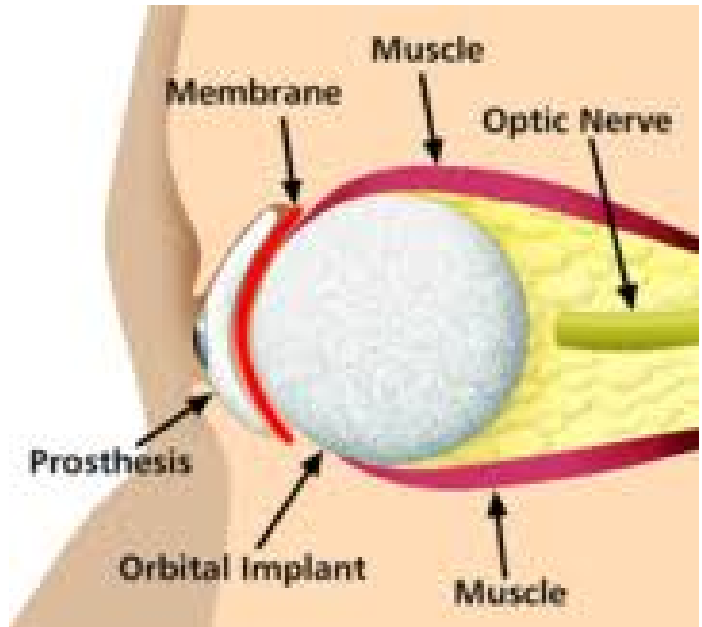


Figure 24

### Conclusion

The prosthetic rehabilitation of anophthalmic socket is a challenging process. The prime factors that need to be considered include surgical modifications to enhance the prosthetic rehabilitation; accurate impression of the defect, selection of proper material and the technique of prosthesis fabrication. This helps the patient re-integrate into the society by improving their psychology and quality of life.

### References

1. Jitendra Jethwani et al, Functional Impression Technique for an Ocular Prosthesis, J Indian Prosthodont Soc. (Jan-Mar 2012) 12(1):55–58.
2. Anna Serene Babu et al. Prosthetic rehabilitation of surgically treated orbital defects- evisceration, enucleation, and extenteration: a case series. J Indian Prosth soc. 2016;16:2
3. Newton JT, Fiske J, Foote O et al. Preliminary study of the impact of loss of part of the face and its

- prosthetic restoration. *J Prosthet Dent.* 1999; 82:585–590.
4. Sanjayagouda B. Patil et al, Ocular prosthesis: a brief review and fabrication of an ocular prosthesis for a geriatric, *The Gerodontology Association and Blackwell Munksgaard Ltd, Gerodontology* 2008; 25: 57–62.
  5. Roberts AC. An instrument to achieve pupil alignment in eye prosthesis. *J Prosthet [11] Dent.* 1969;22:487-89.
  6. Prajna P. Shetty et al. A iris positioning device and centering approach: A technique. *J Prosthet Dent.* 2017.
  7. Rohit Kulshrestha et al. Ocular prosthesis in Dentistry-A review. *Int J clinical & case.* 2018; 2.6:55-61.
  8. Mark F. Mathews, Rick M. Smith, Alan J. Sutton. The ocular impression: A review of the literature and presentation of an alternate technique. *J of Prost.* vol 9,2000;4:210-6
  9. Bartlett SO, Moore DJ: Ocular prosthesis: A physiologic system. *J Prosthet Dent* 1973;29:450-459
  10. Brown KE: Fabrication of an ocular prosthesis. *J Prosthet Dent* 1970;24:225-235
  11. Murphey PJ, Schlossberg L: Eyereplacement by acrylic maxillofacial prosthesis. *US Nav Med Bull* 1944;43:1085-1099
  12. Kennedy JA: Fabrication of ocular prostheses, in Beumer J, Curtis TA, Marunick MT (eds): *Maxillofacial Rehabilitation: Prosthodontic and Surgical Considerations.* St Louis, MO, Ishiyaku EuroAmerica, Inc, 1996, pp 425-427
  13. Allen L, Webster HE: Modified impression method of artificial eye fitting. *Am J Ophthalmol.* 1969;67:189-218.
  14. Miller BJ: Custom ocular impression trays. *J Facial Somato Prosthet* 1996;2:109-113
  15. Guttal SS, Patil NP, Vernekar N et al. A simple method of positioning the iris disk on a custom made ocular prosthesis. *J Prosthodont.* 2008;17:223-227.
  16. McArthur RD. Aids for positioning prosthetic eyes in orbital prosthesis. *J Prosthet Dent.* 1977;37:320-26.
  17. Benson P. The fitting and fabrication of a custom resin artificial eye. *J Prosthet Dent.* 1977;38:532-38.
  18. Ankita Chamaria et al. Iris positioning using a grid attached to a spring bow for a custom ocular prosthesis. *J clinical dent research.* 2016.
  19. Welden RB, Niiranen JV: Ocular prosthesis. *J Prosthet Dent.* 1956;6:272-278
  20. Kuldeep Raizada, Deepa Rani. Ocular prosthesis. *Contact Lens and Anterior Eye.* 2007; 30: 152–162.
  21. Burner J, Curtis TA, Firtell DN: *Maxillofacial Rehabilitation: Prosthodontic and Surgical Considerations.* St. Louis. 1974. The CVMosby Co.
  22. Taicher S, Steinberg HM, Tubiana I, et al: Modified stock eye ocular prosthesis. *J Prosthet Dent.* 1985;54:95-98.
  23. Ronak Mukundkumar Shah et al. The ocular prosthesis: A novel technique using digital Photography. *J Indian Prosthodont Soc.* 2013;30:10-6.
  24. Vikas B. Kamble. Prosthetic correction of post enucleation socket syndrome: A case report. *J Indian Prosthodont Soc.* 2012.
  25. Kamble VB et al. Ocular prosthesis for radiation-induced severely contracted anophthalmic socket: A case report. *Unique journal of medical and dental sciences* 2013;01 (01): 53-56
  26. Kavlekar AA, Aras MA, Chitre V. An innovative and simple approach to fabricate a hollow ocular prosthesis with functional lubricant reservoir: A

- solution to artificial eye comfort. J Indian Prosthodont Soc 2017;17:196-202.
27. Jong Min Ong FRCOphth. The Bionic Eye: A review. Clinical and Experimental Ophthalmology 2012;40:6-17.
28. Ruiters S, Sun Y, de Jong S, et al. Br J Ophthalmol 2016;100:879-881.
29. Md. Shahid Alam, M. Sugavaneswaran, G. Arumaikkannu & Bipasha Mukherjee (2017): An innovative method of ocular prosthesis fabrication by bio-CAD and rapid 3-D printing technology: A pilot study. The International Journal on Orbital Disorders, Oculoplastic and Lacrimal Surgery.2017; Aug;36(4):223-227.