

**Comparative Evaluation of Socket Preservation in Anterior teeth using Allograft Vs Probiotic and Collagen Membrane - A Cone Beam Computed Tomography Analysis**

<sup>1</sup>Dr. Sneha C, PG Student, Department of Periodontics, Panineeya Institute of Dental Sciences and Research Centre, Hyderabad

<sup>2</sup>Dr. Rekha Rani Koduganti, Professor & HOD, Department of Periodontics, Panineeya Institute of Dental Sciences and Research Centre, Hyderabad

<sup>3</sup>Dr. Veerendranath Reddy Panthula, Professor, Department of Periodontics, Panineeya Institute of Dental Sciences and Research Centre, Hyderabad

<sup>4</sup>Dr Surya Prasanna Jammula, Professor, Department of Periodontics, Panineeya Institute of Dental Sciences and Research Centre, Hyderabad

<sup>5</sup>Dr Himabindu. G, Professor, Department of Periodontics, Panineeya Institute of Dental Sciences and Research Centre, Hyderabad

<sup>6</sup>Dr Manasa Ambati, Reader, Department of Periodontics, Panineeya Institute of Dental Sciences and Research Centre, Hyderabad

<sup>7</sup>Dr. Swetha Manchala, Sr Lecturer, Department of Periodontics, Panineeya Institute of Dental Sciences and Research Centre, Hyderabad

**Corresponding Author:** Dr. Rekha Rani Koduganti, Professor & HOD, Department of Periodontics, Panineeya Institute of Dental Sciences and Research Centre, Hyderabad

**Citation of this Article:** Dr. Sneha C, Dr. Rekha Rani Koduganti, Dr. Veerendranath Reddy Panthula, Dr Surya Prasanna Jammula, Dr Himabindu. G, Dr Manasa Ambati, Dr. Swetha Manchala, “Comparative Evaluation of Socket Preservation in Anterior teeth using Allograft Vs Probiotic and Collagen Membrane - A Cone Beam Computed Tomography Analysis”, IJDSIR- March – 2026, Volume – 9, Issue – 2, P. No. 41 – 53.

**Copyright:** © 2026, Dr. Rekha Rani Koduganti, et al. This is an open access journal and article distributed under the terms of the creative common’s attribution non-commercial License. Which allows others to remix, tweak, and build upon the work non-commercially, as long as appropriate credit is given, and the new creations are licensed under the identical terms.

**Type of Publication:** Original Research Article

**Conflicts of Interest:** Nil

**Abstract**

**Background:** The alveolar bone undergoes volumetric changes after extraction due to physiologic bone remodelling. The amount of alveolar bone available during prosthetic replacement can affect the aesthetic

outcome of the treatment and make implant placement challenging. Socket preservation techniques are advocated post extraction to maintain the bone’s vertical and horizontal alveolar bone dimensions and prevent its atrophy. This study aimed to compare the efficacy of

allograft v/s probiotic when used alone or together (Allograft+ Probiotic) in socket preservation

**Materials and Methods:** A total of 30 patients (mean age of 25-50yrs) were included. The subjects were divided into three groups with each group comprising of 10 individuals. Group I included socket preservation after extraction using allograft with collagen membrane Patients in Group II underwent socket preservation after extraction using probiotic and collagen membrane. In Group III patients, socket preservation using combination of allograft and probiotic, with collagen membrane was done.

**Results:** The socket height at the apical thirds and the overall width improved significantly from baseline to three months in Group I (Allograft+ collagen membrane).and the results were also significant in relation to Group III (Allograft+ Probiotic +collagen membrane), wherein there was an improvement at coronal and middle thirds in the socket height.

**Conclusion:** Socket preservation maintains the height and width of the remaining viable alveolar ridge post extraction. Results showed that the socket height and width improved significantly in Group I. In Group III there was an improvement pertaining only to the socket height in the coronal and middle thirds after 3 months of socket preservation.

**Keywords:** Socket preservation, CBCT, allograft, probiotic, GTR.

### Introduction

Tissues that surround and anchor a tooth in the maxillary or mandibular alveolar process make up the periodontium. All the components of the periodontium in health, play a very important role in supporting the teeth in their sockets. However, when a tooth is extracted due to periodontal disease, it is observed that if the socket is not preserved, more amount of bone loss occurs,

impeding the placement of either fixed or removable prosthesis<sup>1,2</sup>. Recently implants have been preferred by both the patients as well as the clinicians, due to higher success rates. It is imperative that the bone quality and quantity should be adequate for successful placement of endosseous implants. Socket preservation is a procedure followed after an infected tooth is extracted, and periapical curettage is done. This procedure is advocated in patients wanting implants, as it is mandatory that the bone around the socket has to be preserved to make implant placement feasible and successful. Many graft materials and techniques of socket preservation have been done<sup>3,4</sup>. This study was done to understand the benefits of utilizing allograft and probiotic either as monotherapy or synergistically in socket preservation.

**Materials and Methods:** Thirty patients who attended the outpatient ward of a tertiary referral care centre in Hyderabad participated in this parallel arm randomised study conducted from September to December 2023. Written informed consent was taken from each of them and this study was approved by the institutional ethical committee ((PMVIDS&RC IEC PERIO/DN/415-21) and was registered (CTRI/2023/05/052557). The subjects were equally divided into three groups, wherein in Group I after tooth extraction the sockets were preserved with allograft and collagen membrane, and in Group II after tooth extraction the sockets were preserved using Probiotic and collagen membrane. Patients in Group III received allograft +probiotic and collagen membrane after tooth extraction.

**Inclusion Criteria:** Required extraction of Maxillary or mandibular non restorable single rooted tooth and the presence of healthy teeth adjacent to the extracted socket.

**Exclusion Criteria:** Smokers, Pregnant and lactating woman. Patients with motor difficulties that impede or hamper hygiene, immunocompromised patients, and

patients with metabolic bone diseases or who had undergone radiotherapy in the last five years were excluded from the study.

**Primary Outcome Measure:** Measurement of socket width and height was done from the Cementoenamel junction to the base of the socket using cone beam computerized tomography (CBCT) at baseline and three months after socket preservation. The assessment was performed by dividing the socket equally into 3 parts to derive the coronal, middle and apical thirds of the socket at baseline and after three months.

**Secondary Outcome Measure:** Included assessment of soft tissue healing at 1 week and 3 months' post extraction using Laundry et al 1988 healing index and assessment of post-operative pain using visual analogue scale (VAS) 1 week after extraction.

**Pre-Surgical Protocol:** Detailed medical and dental history were recorded before enrolling the patients in this study. Routine blood investigations were done and clinical photographs were taken for documentation.

**Surgical Procedure:** Surgery was carried out under strict aseptic condition with 10ml of 0.2% Chlorhexidine mouth rinse used as a presurgical mouth rinse. Local anaesthesia with lignocaine hydrochloride 2% with adrenaline 1:80000 was administered at the surgical site. Atraumatic extraction of the tooth was performed using a suitable periosteal elevator to sever the periodontal ligament fibre attachments and the tooth was extracted using forceps. Care was taken to preserve the integrity of the buccal and lingual/palatal bony walls.

**Socket grafting:** After extraction, the socket was carefully curetted and saline irrigation was done to remove any surgical debris and granulation tissue that was present and the socket was inspected to ascertain that the bony plates were intact

**Group I:** The allograft was procured from Tata Memorial Hospital Tissue Bank., Mumbai (Decalcified Freeze-Dried Bone Allograft-DFDBA). It was mixed with 2-3 drops of saline into a workable consistency and compacted into the socket in small increments using the ball end of a CPITN probe. The material was gently and slowly compressed until the socket was completely filled. (Figs 1a, b, c,)

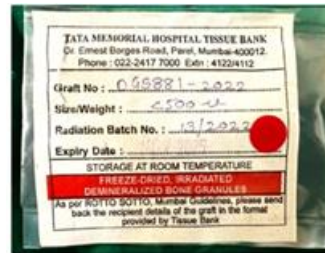

Fig 1a: Allograft from Tata Memorial

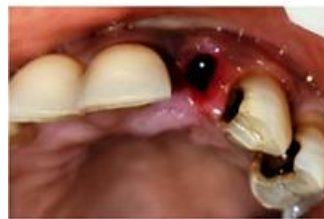

Fig 1b: Socket post extraction in Group I

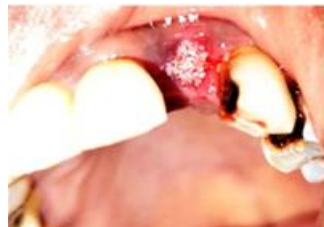

Fig 1c: Placement of allograft into the socket in Group I

**Group II:** Probiotic powder was procured from in life Pharma, Pre and Probiotic capsules comprising of Lactobacillus acidophilus and Lactobacillus rhamnosus 0.60 billion colony-forming units (CFU) each, Bifidobacterium bifidus and Bifidobacterium longum 0.60 billion CFU). The probiotic powder obtained from one capsule was mixed with 2-3 drops of saline into a workable consistency and compacted into the socket in small increments using the ball end of a CPITN probe.

The material was gently and slowly compressed until the socket was completely filled. (Figs 2a, b, c)



Fig 2a: Probiotic capsules from INLIFE

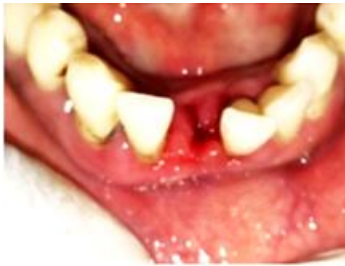

Fig 2b: Socket post extraction in Group II

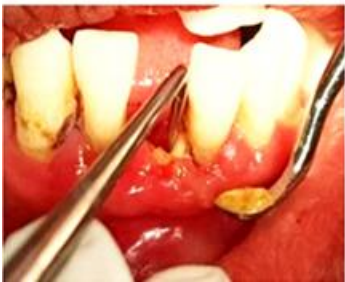

Fig 2c: Placement of probiotic mixed with saline into the socket in Group II

**Group III:** Equal quantity of allograft and probiotic powder (1:1 ratio) were taken depending upon the socket depth, mixed with 2-3 drops of saline into a workable consistency and compacted into the socket in small increments using the ball end of a CPITN probe. The material was gently and slowly compressed until the socket was completely filled. After placement of the graft material into the socket a resorbable collagen membrane (Healiguide membrane- Advanced Biotech Pvt Ltd, Chennai, Tamil Nadu) shaped to fit the diameter of the socket entrance was placed as a barrier (Figs 3, 4) and the

socket was sutured using 3.0 black silk suture. The patients were asked to report after one week to record the VAS Score as well as the Landry's Healing index. The Healing index was again taken at 3 months along with the CBCT.

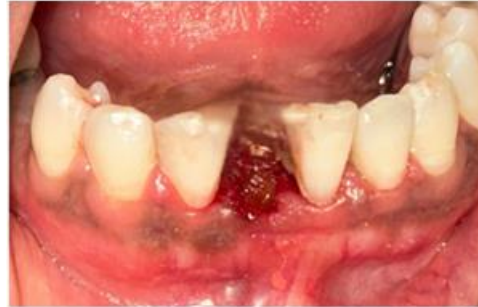

Fig 3: Placement of Allograft+ Probiotic into the socket in Group III

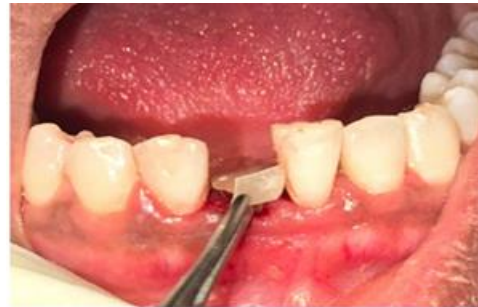

Fig 4: Placement of GTR membrane covering the socket

**Landry's Healing Index:** This Healing Index (HI), was introduced by Landry et al. in 1988 and evaluated the parameters of tissue colour, bleeding response to palpation, presence of granulation tissue, characteristics of the incision margins, and the presence of suppuration. The scores range from 1 to 5 and correspond to very bad to excellent healing.

**VAS:** It is a subjective measure of pain with the scores recorded by making a handwritten mark on a 10-cm line that represents a continuum between "no pain" (0) and "worst pain." (10). The VAS was assessed at day 7 post surgery.

#### Statistical Analysis

The data was entered in Microsoft excel 2016 for Windows. The Frequencies and percentages of variables

in different groups among gender were calculated. Paired t-test was used to compare the intragroup comparisons of means among the groups at baseline and 3 months. One-way ANOVA (Intergroup comparison) was used to compare the length and width of the bony walls between the 3 groups at coronal, middle and apical surfaces. P value < 0.05 was considered statistically significant. Data analyses were performed using version 25.0 of the Statistical Package for Social Sciences (IBM Corporation, Armonk, New York, USA).

## Results

### Primary outcome measure: Intragroup Comparison

#### Group I (Allograft +GTR)

**Socket Height:** At baseline, the mean height of socket at coronal thirds was  $3.54 \pm 0.58$  and it increased to  $4.69 \pm 1.2$  by the end of 3 months. At middle thirds it was  $7.31 \pm 1.38$  and it improved to  $7.48 \pm 1.4$  but the result was not significant statistically. The apical thirds at baseline it was  $9.97 \pm 3.15$  and it increased to  $12.35 \pm 2.32$  at 3months showing a significant improvement. (Table1)

**Socket Width:** The mean coronal width of socket at baseline was  $11.09 \pm 1.8$  and it increased to  $12.54 \pm 1.34$  by the end of 3 months. At middle thirds it was  $9.27 \pm 1.96$  and it increased to  $10.60 \pm 1.43$  which was statistically significant. The mean apical width of socket at baseline was  $4.52 \pm 1.40$  and increased to  $5.77 \pm 1.43$  at 3months showing a significant difference. Therefore, there was a marked improvement related to height of socket in the coronal and apical thirds, while there was an overall improvement in the width of the socket in Group I. (Table1) (Figs 5 a, b, c, d)

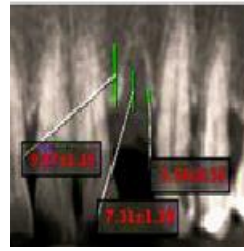


Fig 5a: Socket Height at baseline in Group I by CBCT




Fig 5b: Socket Width at baseline in Group I by CBCT

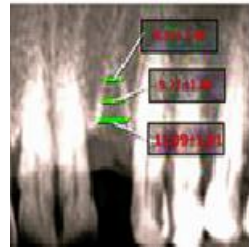


Fig 5c: Socket Height after 3 months in Group I by CBCT

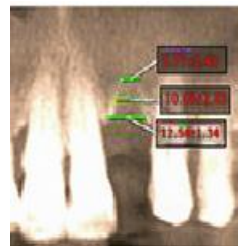


Fig 5d: Socket width after 3 months I Group I by CBCT

#### Group II (Probiotic+ GTR):

**Socket height:** At baseline, the mean height of socket at coronal thirds was  $3.85 \pm 0.49$  and  $3.75 \pm 0.35$  by the end of 3 months. In the middle thirds it was  $7.05 \pm 0.7$  and  $7.25 \pm 0.9$  at 3 months but was not statistically significant. At the apical thirds it was  $12.6 \pm 1.8$  at baseline and reduced to  $11.92 \pm 1.6$  at 3months. (Table 2)

**Socket width:** At baseline, the mean coronal width of socket was  $12.90 \pm 1.1$  and decreased to  $10.79 \pm 1.38$  by the

end of 3 months. At middle thirds it was  $9.34 \pm 1.63$  and  $7.4 \pm 1.11$  at 3 months showing no statistical significance. The mean apical width of socket at baseline was  $5.15 \pm 9.6$  and  $4.52 \pm 8.6$  at 3 months. In Group II, there was an improvement only related to the height of the socket at middle thirds which was not of statistical significance. (Table 2) (Figs 6 a, b, c, d)

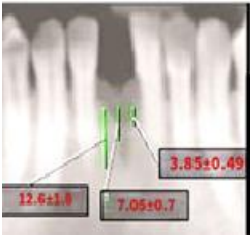

Fig 6a: Socket Height at baseline in Group II by CBCT

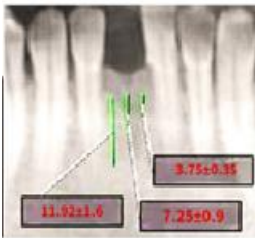


Fig 6b: Socket Width at baseline in Group II by CBCT

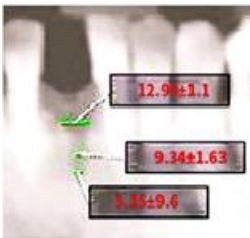


Fig 6c: Socket Height after 3 months in Group II by CBCT

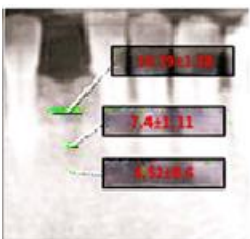


Fig 6d: Socket width after 3 months I Group II by CBCT

**Group III (Allograft+ Probiotic+ GTR)**

**Socket Height:** At baseline, the mean height of socket at coronal thirds was  $3.86 \pm 0.46$  and it increased to  $5.42 \pm 1.37$  by the end of 3 months. At middle thirds it was  $7.28 \pm 0.63$  and  $8.14 \pm 1.37$  at 3 months but was not statistically significant. The mean apical height of socket at baseline was  $10.58 \pm 1.18$  and  $11.28 \pm 1.22$  at 3 months (Table 3)

**Socket width:** The mean coronal width of socket at baseline was  $9.69 \pm 1.14$  and  $11.7 \pm 1.72$  by the end of 3 months. At middle thirds it was  $7.92 \pm 1.71$  and  $8.37 \pm 0.92$  at 3 months showing a statistically significant difference. The mean apical width of socket at baseline was  $4.98 \pm 0.74$  and  $6.01 \pm 0.94$  at 3 months showing a significant difference. Therefore, in Group III though the height at the coronal thirds of the socket only improved at 3 months, the overall width of the socket improved in this group from baseline to 3 months. (Table 3) (Figs 7 a, b, c, d)

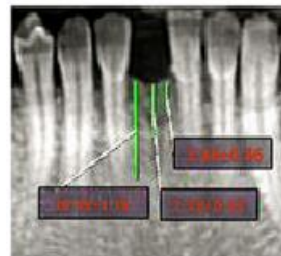


Fig 7a: Socket Height at baseline in Group III by CBCT




Fig 7b: Socket Width at baseline in Group III by CBCT

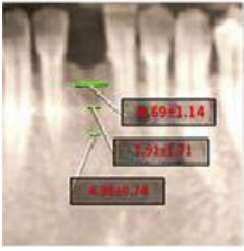


Fig 7c: Socket Height after 3 months in Group III by CBCT

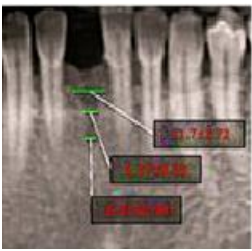


Fig 7d: Socket width after 3 months I Group III by CBCT

### Intergroup Comparison

**Socket Height:** There was a significant difference seen among all the three groups in the height of the socket after 3 months, and Group III (Allograft + Probiotic+ GTR) showed superior results compared to the other two groups at the coronal and middle thirds of the socket. However, at the apical thirds of the socket after 3 months, Group I (Allograft+ GTR). showed superior results. (Table 4)

**Socket width:** It was observed that the socket width improved in all the three groups at coronal, middle and apical thirds after 3 months. However, Group I (Allograft+ GTR) showed superior results when compared to the other two groups. (Table 5)

### Secondary Outcome Measure

It was observed that Group III showed marginally superior results related to the healing index at 7 days and after 3 months, closely followed by Group I (Allograft + GTR) and then Group II (Probiotic +GTR). (Graph I)

Related to the Visual analogue score (VAS) it was observed that in Group III (Allograft+ Probiotic + GTR) the VAS Score was the best as 9 patients had given a

score of 0, followed by Group II wherein 6 patients had given a score of 0. (Graph II)

### Discussion

Atraumatic extraction and limiting the flap elevation are essential to preserve the socket anatomy. Prevention of resorption of the buccal plate of the socket, is the primary requisite of socket preservation. In addition, the goal is to preserve alveolar bone volume three dimensionally. This provides faster regeneration of bone and good osseointegration of the implant when placed in the socket. The end result would be a good aesthetic outcome when the implant prosthesis is seated on the implant <sup>5</sup>. This procedure is mandatory in aesthetic regions like the anterior, when the alveolar crest is very narrow, and when the buccal and lingual alveolar walls are thinner than 2mm with an associated thin gingival phenotype. Socket preservation cannot be performed in medically compromised patients who are on bisphosphonates, or immunosuppressants and have received radiation or chemotherapy <sup>6,7</sup>.

Numerous studies have been done using different graft materials and membranes for preserving the socket. A systematic review was conducted by some researchers to evaluate whether socket preservation at the time of tooth extraction improves soft tissue volume and/or implant aesthetics. It was concluded from the evidence gathered from studies that the addition of soft tissue grafting to hard tissue intra socket grafts for ridge preservation may improve soft tissue contours and reduce volumetric loss from baseline in patients with intact buccal bone <sup>8</sup>.

Using allografts in socket preservation, some authors histologically compared the benefits of utilising Freeze-dried bone allografts (FDBA) and Decalcified-freeze dried bone (DFDBA) allografts in the healing of extraction sockets. It was observed that greater new bone formation occurred with DFDBA <sup>9</sup>.

Another study was done to evaluate the efficacy of extraction socket preservation with demineralized freeze-dried bone allograft alone and along with platelet-rich fibrin. The results of this study demonstrated that PRF combined with DFDBA preserved ridge width better than DFDBA alone. The authors concluded that DFDBA+PRF would benefit the patient by providing ridge form to meet functional and aesthetic needs and preclude future ridge augmentation procedures <sup>10</sup>.

Membranes have often been used with graft materials in socket preservation as they serve as barriers preventing the downgrowth of epithelial cells into the socket and facilitating the laying down of osteogenic cells to synthesize bone. Moreover, they also preserve bone thus contributing to ridge stability for implant placement. Non-resorbable membranes were used earlier and have now been replaced by resorbable collagen membranes and polymeric bioresorbable membranes like polylactic acid.

Forty subjects who had extraction sockets with buccal dehiscence participated in a study. They were equally divided into two groups. One group received demineralized allograft and reconstituted cross-linked collagen membrane (DFDBA + RECXC) while the other received deproteinized bovine bone mineral with native bilayer collagen membrane (DBBMC + NBCM). Socket dimensions were recorded at baseline and 6 months and biopsies were retrieved for histomorphometric analysis at 6 months. Though biopsies taken for histomorphometric analysis did not show significant difference pertaining to the lingual and buccal vertical bone changes between the two groups it was observed that the width of the socket improved significantly in the DBBMC+NBCM group <sup>11</sup>.

Another study evaluated the long-term aesthetic and radiographic results of implants placed in the anterior maxilla after ridge preservation, combining bovine

xenograft with collagen matrix. Fifteen patients who required a single tooth extraction were included in the study. After extraction, all sites were grafted using Deproteinized Bovine Bone Mineral (DBBM) with collagen and covered by a resorbable collagen matrix (CM). Five months after socket grafting, implants were successfully installed. After seven years, a 100% survival rate was observed for all 15 implants, with minimal marginal bone loss. The Pink aesthetic score calculated at baseline and after 7 years did not change markedly proving that placing collagen bovine bone in a fresh extraction socket, covered with a collagen matrix, can preserve the alveolar ridge and provide long-term stable aesthetic results <sup>12</sup>.

This study is in accordance with the previous studies as it was observed that in Group I (Allograft + GTR) there was an improvement at apical thirds in socket height after 3 months and the socket width improved overall significantly after 3 months in this group when compared to the other groups

Research is revolving around probiotics these days and many studies have been done using probiotics systemically, as local drug delivery agents and for oral irrigation as well as in the management of peri-implantitis <sup>13-18</sup>. As per our knowledge, no study has been done to evaluate the efficacy of Probiotics in socket preservation. In the present study combination of Probiotic+ GTR in Group II did not show any beneficial effects related to the overall socket width. Though the height of the socket improved marginally at the middle thirds after 3 months, the results were not statistically significant. The patients allocated to Group 3 included Allograft+ Probiotic+ GTR. Though no studies as per our knowledge are available using these materials in combination for socket preservation, in Group III the

socket height improved at the coronal and middle thirds after 3 months.

### **Limitations**

The sockets of anterior teeth of both the maxilla and mandible were included in the study, perhaps limiting the study pertaining to a single tooth socket, would have validated the study better. The sample size was small, conducting a study with a larger sample size could help us ascertain the true potential for regeneration of the materials used.

### **Conclusion**

Many graft materials have been employed for socket preservation and in the present study we made use of Allograft +GTR in Group I, Probiotic+ GTR in Group II and Allograft +Probiotic +GTR in Group III. The results showed that the socket height at the apical thirds and overall width improved significantly in Group I (Allograft+ GTR), though superior results were observed in relation to Group III (Allograft+ Probiotic +GTR), pertaining to the socket height at the coronal and middle thirds after 3 months of socket preservation. Probiotics have many beneficial properties to aid in wound healing and regeneration, and many studies have been done to ascertain their role in periodontal therapy. In this study it was observed that the patients administered probiotics in Group II, did not show appreciable improvement in the socket height and width 3 months post socket preservation. These results may indicate that the probiotic powder may not have been retained in the socket for a feasible amount of time. Mixing the Probiotic powder with a carrier like Xanthan which aids in release and retention of the probiotic may have given better results. Future studies have to be conducted with these graft materials using a larger sample size and for a period of 5-6 months to truly validate their benefits in socket preservation.

### **References**

1. Avila-Ortiz G, Gubler M, Romero-Bustillos M, Nicholas CL, et al. Efficacy of Alveolar Ridge Preservation: A Randomized Controlled Trial. *J Dent Res.* 2020; 99:402–409. doi: 10.1177/ 0022 034520905660.
2. Faria-Almeida R, Astramskaite-Januseviciene I, Puisys A, Correia F. Extraction Socket Preservation with or without Membranes, Soft Tissue Influence on Post Extraction Alveolar Ridge Preservation: a Systematic Review. *J Oral Maxillofac Res.* 2019;10:e5. doi: 10.5037/jomr.2019.10305.
3. Stumbras, A.; Kuliesius, P.; Januzis, G.; Juodzbalsys, G. Alveolar Ridge Preservation after Tooth Extraction Using Different Bone Graft Materials and Autologous Platelet Concentrates: A Systematic Review. *J. Oral Maxillofac. Res.* 2019;10:e2.
4. Nisar, N.; Nilesh, K.; Parkar, M.I.; Punde, P. Extraction Socket Preservation Using a Collagen Plug Combined Withplatelet-Rich Plasma (PRP): A Comparative Clinico-Radiographic Study. *J. Dent. Res. Dent. Clin. Dent. Prospect.* 2020; 14:139–145.
5. Mahesh L, Venkataraman N, Shukla S, Prasad H, Kotsakis GA. Alveolar ridge preservation with the socket-plug technique utilizing an alloplastic putty bone substitute or a particulate xenograft: a histological pilot study. *J Oral Implantol.* 2015;41:178-83
6. Tomlin EM, Nelson SJ, Rossmann JA. Ridge preservation for implant therapy: a review of the literature. *Open Dent J.* 2014; 8:66-76.
7. Jung RE, Ioannidis A, Hämmerle CHF, Thoma DS. Alveolar ridge preservation in the esthetic zone. *Periodontol* 2000. 2018; 77:165-175.
8. Geisinger ML, Holmes CM, Geurs NC, Reddy MS. Does Ridge Preservation at the Time of Tooth

Extraction Improve Soft Tissue Volume and/or Implant Esthetics? A Review of Current Evidence. *Clin Adv Periodontics*. 2015;5:208-215

9. Wood, Robert A., and Brian L. Mealey. "Histologic comparison of healing after tooth extraction with ridge preservation using mineralized versus demineralized freeze-dried bone allograft." *Journal of periodontology* 2012;83:329-336.
10. Thakkar DJ, Deshpande NC, Dave DH, Narayankar SD. A comparative evaluation of extraction socket preservation with demineralized freeze-dried bone allograft alone and along with platelet-rich fibrin: A clinical and radiographic study. *Contemp Clin Dent*. 2016;7:371-6
11. Scheyer ET, Heard R, Janakievski J, Mandelaris G, Nevins ML, Pickering SR, Richardson CR, Pope B, Toback G, Velásquez D, Nagursky H. A randomized, controlled, multicentre clinical trial of post-extraction alveolar ridge preservation. *J Clin Periodontol*. 2016;43:1188-1199.
12. Batas L, Xanthopoulou V, Gnigou M, Vagdouti T, Fragkioudakis I, Vouros I. The Long-Term Esthetic and Radiographic Outcome of Implants Placed in the Anterior Maxilla after Ridge Preservation, Combining Bovine Xenograft with Collagen Matrix. *Dent J (Basel)*. 2024;12:80.
13. Penala S, Kalakonda B, Pathakota KR, Jayakumar A, Koppolu P, Lakshmi BV, Pandey R, Mishra A. Efficacy of local use of probiotics as an adjunct to scaling and root planing in chronic periodontitis and halitosis: A randomized controlled trial. *J Res Pharm Pract*. 2016;5:86-93
14. Tada H, Masaki C, Tsuka S, Mukaibo T, Kondo Y, Hosokawa R. The effects of *Lactobacillus reuteri* probiotics combined with azithromycin on peri-implantitis: A randomized placebo-controlled study. *J Prosthodont Res*. 2018;62:89-96.
15. Boyeena L, Koduganti RR, Panthula VR, Jammula SP. Comparison of efficacy of probiotics versus tetracycline fibers as adjuvants to scaling and root planing. *J Indian Soc Periodontol*. 2019;23:539-544
16. Kumar V, Singhal R, Rastogi P, Lal N, Pandey S, Mahdi AA. Localized probiotic-guided pocket recolonization in the treatment of chronic periodontitis: a randomized controlled clinical trial. *J Periodontal Implant Sci*. 2021;51:199-212
17. El-Bagoory GKM, El-Guindy HM, Shoukheba MYM, El-Zamarany EA. The adjunctive effect of probiotics to nonsurgical treatment of chronic periodontitis: A randomized controlled clinical trial. *J Indian Soc Periodontol*. 2021;25:525-531
18. Vishnusripriya J, Melath A, Feroz M, Subair K, Chandran N. Comparative evaluation of locally delivered probiotic paste and chlorhexidine gel as an adjunct to scaling and root planing in treating chronic periodontitis: A split-mouth randomized clinical trial. *J Indian Soc Periodontol*. 2022;26:262-268.

**Legend Tables and Figure**

Table 1: Intragroup Comparison of Mean Values of Socket Height and Width in Group I (Allograft+Gtr)

	Surface	Time		Mean Difference	T-Value	P-Value
		Baseline	3 months			
Height	Coronal	3.54±0.58	4.69±1.2	1.14400	3.185	0.01*
	Middle	7.31±1.38	7.48±1.41	0.16200	.280	0.786

	Apical	9.97±3.15	12.35±2.32	2.38000	3.262	0.01*
Width	Surface	Baseline	3 months	Mean Difference	T-Value	P-Value
	Coronal	11.09±1.81	12.54±1.34	-1.45200	-2.559	0.03*
	Middle	9.27±1.96	10.60±1.43	-1.32900	-3.447	0.007*
	Apical	4.52±1.40	5.77±1.43	-1.24500	-2.215	0.05*

Table 2: Intragroup Comparison of Mean Values of Socket Height and Width in Group II (Probiotic+GTR)

Height	Surface	Time		Mean Difference	T-Value	P-Value
		Baseline	3 months			
	Coronal	3.85±0.49	3.75±0.35	0.10000	.538	0.604
	Middle	7.05±0.7	7.25±0.9	0.20200	.714	0.493
	Apical	12.6±1.8	11.92±1.6	0.67500	1.010	0.339
Width	Surface	Baseline	3 Months	Mean Difference	T-Value	P-Value
	Coronal	12.90±1.1	10.79±1.38	2.11000	-4.759	-0.001
	Middle	9.34±1.63	7.4±1.11	1.94300	-2.631	-0.02
	Apical	5.15±9.6	4.52±8.6	0.63200	1.899	0.09

Table 3: Intragroup Comparison of Mean Values of Socket Height and Width in Group III (Allograft+Probiotic+GTR)

HEIGHT	Surface	Time		Mean Difference	T-Value	P-Value
		Baseline	3 months			
	CORONAL	3.86±0.46	5.42±1.37	1.56000	4.010	0.003*
	MIDDLE	7.28±0.63	8.14±1.37	0.86000	2.192	0.056
	APICAL	10.58±1.18	11.28±1.22	0.70000	1.901	0.09
WIDTH	Surface	Baseline	3 months	Mean Difference	P-Value	T-Value
	CORONAL	9.69±1.14	11.7±1.72	2.01000	5.573	0.000
	MIDDLE	7.92±1.71	8.37±0.92	1.55000	2.799	0.02*
	APICAL	4.98±0.74	6.01±0.94	1.03000	3.494	0.007*

Table 4: Intergroup Comparison of Socket Height at Coronal, Middle and Apical Thirds from Baseline to 3 Months

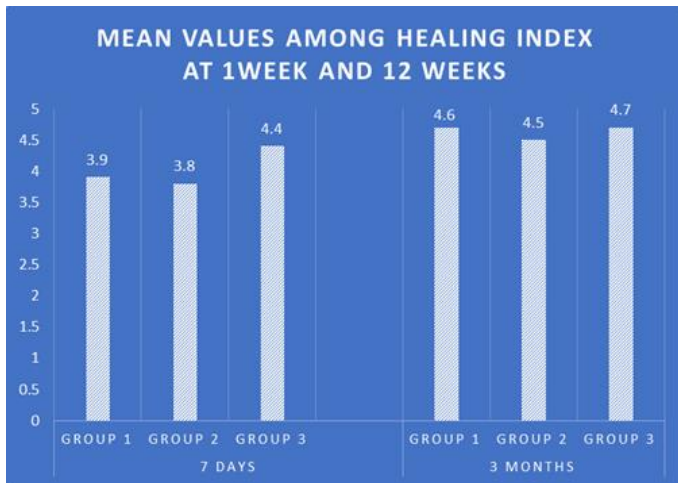
Surface	Socket Height Between Groups	Mean	STD	95% Confidence Interval		p-value
				Lower Bound	Upper Bound	
Baseline						
Coronal	G1	3.54	0.58	3.1304	3.9616	0.312
	G2	3.85	0.49	3.5011	4.2089	
	G3	3.86	0.46	3.5271	4.1929	

Middle	G1	7.31	1.38	6.3286	8.3074	0.178
	G2	7.05	0.76	6.5052	7.6028	
	G3	7.28	0.63	6.8307	7.7393	
Apical	G1	9.97	3.15	7.7134	12.2266	0.03*
	G2	12.6	1.88	11.2482	13.9518	
	G3	10.58	1.18	9.7290	11.4310	
After 3 months						
Coronal	G1	4.69	1.24	3.7994	5.5806	0.008*
	G2	3.75	0.35	3.5002	4.0098	
	G3	5.42	1.37	4.4335	6.4065	
Middle	G1	7.48	1.41	6.4668	8.4932	0.281
	G2	7.25	0.95	6.5731	7.9389	
	G3	8.14	1.37	7.1595	9.1305	
Apical	G1	12.35	2.32	10.6842	14.0158	0.412
	G2	11.92	1.60	10.7778	13.0722	
	G3	11.28	1.22	10.4027	12.1573	

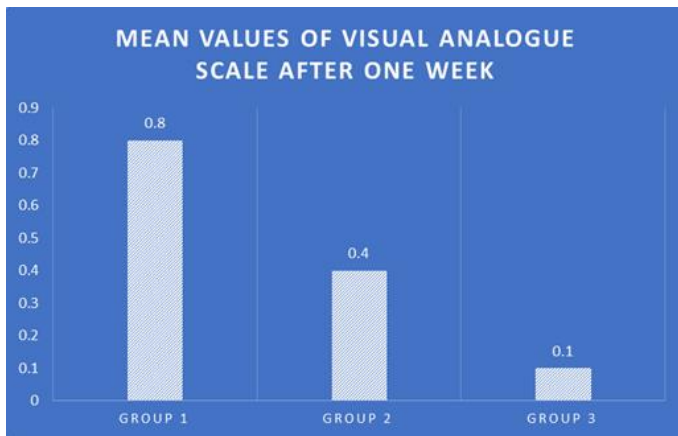
Table 5: Intergroup Comparison Of Socket Width At Coronal, Middle And Apical Thirds From Baseline To 3 Months

Surface	Socket Width Between Groups	Mean	STD	95% Confidence Interval		P- Value <0.05
				Lower Bound	Upper Bound	
Baseline						
Coronal	G1	11.09	1.811	9.7885	12.3915	0.01*
	G2	12.9	1.100	12.1127	13.6873	
	G3	9.690	1.143	8.8720	10.5080	
Middle	G1	9.27	1.96	7.8669	10.6851	0.850
	G2	9.34	1.63	8.1729	10.5131	
	G3	7.92	1.71	7.6949	10.1451	
Apical	G1	4.52	1.402	3.5219	5.5281	0.414
	G2	5.15	0.964	4.4622	5.8418	
	G3	4.98	0.745	4.4470	5.5130	
After 3 Months						
Coronal	G1	12.54	1.34	11.5818	13.5022	0.04*
	G2	10.79	1.38	9.7962	11.7838	
	G3	12.70	1.72	10.4688	12.5312	

Middle	G1	10.60	1.43	9.5807	11.6293	0.000*
	G2	7.40	1.11	6.6056	8.1944	
	G3	8.37	0.92	6.7066	8.0334	
Apical	G1	5.77	1.43	4.7438	6.7962	0.01*
	G2	4.52	0.86	3.9030	5.1370	
	G3	6.01	0.94	5.3327	6.6873	



Graph I: Healing Index by Laundry at 1 week and 6 weeks



Graph II: VAS score after 1 week