



To Compare and Evaluate The Transconjunctival and Subciliary Approach to Orbit in Zygomaticomaxillary Complex Fracture

¹Dr. Mahima Jain, Department of Oral and Maxillofacial Surgery, 3rd Year Resident , Mahatma Gandhi Dental College and Hospital, Mahatma Gandhi University of Medical Sciences and Technology, Jaipur, India

²Dr. Vikas Kunwar Singh, Professor and Head, Department of Oral and Maxillofacial surgery, Mahatma Gandhi Dental College and Hospital, Mahatma Gandhi University of Medical Sciences and Technology, Jaipur, India

³Dr. Ruchika Tiwari, Professor, Department of Oral and Maxillofacial Surgery, Mahatma Gandhi Dental College and Hospital, Mahatma Gandhi University of Medical Sciences and Technology, Jaipur, India

⁴Dr. Krupa Chokshi, Department of Oral and Maxillofacial Surgery , 3rd Year Resident , Mahatma Gandhi Dental College and Hospital, Mahatma Gandhi University of Medical Sciences and Technology, Jaipur, India

⁵Dr. Krati Jajani, Department of Oral and Maxillofacial Surgery , 3rd Year Resident , Mahatma Gandhi Dental College and Hospital, Mahatma Gandhi University of Medical Sciences and Technology, Jaipur, India

Corresponding Author: Dr. Mahima Jain, Department of Oral and Maxillofacial Surgery, 3rd Year Resident, Mahatma Gandhi Dental College and Hospital, Mahatma Gandhi University of Medical Sciences and Technology, Jaipur, India

Citation of this Article: Dr. Mahima Jain, Dr. Vikas Kunwar Singh, Dr. Ruchika Tiwari, Dr. Krupa Chokshi, Dr. Krati Jajani, “To Compare and Evaluate The Transconjunctival and Subciliary Approach to Orbit in Zygomaticomaxillary Complex Fracture”, IJDSIR- December – 2024, Volume –7, Issue - 6, P. No. 68 – 77.

Copyright: © 2024, Dr. Mahima Jain, et al. This is an open access journal and article distributed under the terms of the creative common’s attribution non-commercial License. Which allows others to remix, tweak, and build upon the work non-commercially, as long as appropriate credit is given, and the new creations are licensed under the identical terms.

Type of Publication: Original Research Article

Conflicts of Interest: Nil

Abstract

Background: The most commonly used approaches to infraorbital rim and orbital floor are subciliary, subtarsal, infraorbital rim and transconjunctival approach. Access to inferior orbital margins and to the orbital floor can be gained through conventional approaches of Subciliary, Mid lower eyelid and Infraorbital incisions. The transconjunctival approach results in decreased risk of postoperative eyelid retraction, which varies from scleral show to persistent ectropion. It also results in better aesthetic results, greater degree of exposure of orbital

floor, and less extending scar as compare to Subciliary Approach.

Aim of The Study: To compare and evaluate the clinical outcomes of two approaches i.e Transconjunctival and Subciliary to orbit for open reduction and fixation of Zygomatico-Maxillary complex fractures.

Materials and Methods: It is a prospective study undertaken in the IPD patients of Department of Oral and Maxillofacial Surgery. The study was conducted in 20 cases of Zygomatico-maxillary complex fractures with involvement of orbital floor and rim.

Results: Cases done with subciliary approach shows more soft tissue complications e.g. Scar, Ectropion etc. while result in cases done with transconjunctival approach were more aesthetically pleasing. Subciliary approach provides direct access to the fracture site and hence the time taken is comparatively lesser than transconjunctival approach.

Conclusion: Both the approaches have potential for sequelae and complications. The subciliary approach is faster gives good exposure of the infra-orbital rim and is better suited to reduce displaced fractures of the infra-orbital rim, but the risk of post-operative scarring and other soft tissue complications are much higher. The transconjunctival approach is comparatively faster, gives better esthetic results and fewer post-operative complications but is technique sensitive and requires an additional lateral canthotomy in cases where more exposure is needed.

Keywords: Transconjunctival approach; Sub Ciliary Approach; Orbital floor; Infraorbital rim; Zygomatic complex fracture

Introduction

The incisions used for orbital skeleton and periorbital area historically appear to have their origins, at least partly, in the treatment of two separate facial problems: zygomatico-orbital fractures and cosmetic blepharoplasty.

There is a current trend towards more central placement of incisions with respect to the globe, which provides nearly equal access and improved esthetics. Successful utilization of these approaches is dependent on surgeon's appreciation of the relationship between eyelid/periorbital anatomy and lid/ocular function¹

The most commonly used approaches to infraorbital rim and orbital floor are subciliary, subtarsal, infraorbital rim and transconjunctival approach. Access to inferior

orbital margins and to the orbital floor can be gained through conventional approaches of subciliary, mid lower eyelid and infraorbital incisions.

Although it seems that differences are only at the level of the incision from the ciliary margins, the anatomy of region, particularly the junction of the palpebral and circumorbital components of the orbicularis oris muscle, the presence of orbital septum at the level where it arises from the periosteum of the rim and the periorbital fat on the deep aspect combine to increase the risk of subsequent scar contracture and adhesions to the orbital margin which, in turn may lead to depressed scar possibly and ectropion.

Thus, these approaches leave behind a scar which may be cosmetically disfiguring at times.² Several authors have proposed that the transconjunctival approach decreases the risk of postoperative eyelid retraction, which varies from scleral show to persistent ectropion. These studies have shown a lower incidence of ectropion using a transconjunctival compared with a subciliary approach for the treatment of orbital trauma.³⁻⁴ The infraorbital incision can heal well with meticulous wound closure, but the approach is associated with prolonged lower eyelid pretarsal edema.

There are two different routes for the transconjunctival approach: retroseptal and preseptal.⁵ In blepharoplasty procedures, many authors use the retroseptal approach. It is also used in the treatment of orbital fractures, because of direct access to the orbital floor.⁶

The main disadvantage of the retroseptal approach is additional disturbances of the infraorbital connective framework. The retroseptal approach produces an additional scar in the anterior part of the infraorbital fat system. This could influence the eye movements and can participate in the development of an enophthalmos.⁷

Since only few studies were reported in the literature regarding transconjunctival preseptal approach for the treatment of orbital floor and infraorbital rim fracture, present study was undertaken to evaluate the various advantages of this approach mentioned in the literature like minimal scar, decreased possibility of eyelid retraction or ectropion.

Aim and objective of the Study: To compare and evaluate the clinical outcomes, time required for exposure of fracture site and complications of two approaches i.e Transconjunctival and Subciliary for open reduction and fixation of Zygomatico-Maxillary complex fractures.

Materials and Methods

The study was undertaken in IPD patients of Department of Oral and Maxillofacial Surgery, Mahatma Gandhi Dental College and Hospital, Jaipur. Patients were selected irrespective of sex, cast and socioeconomic status. This is a prospective randomised controlled study.

20 patients were divided randomly into 2 groups, 10 in each group. Group A is the control group where patients with zygomaticomaxillary complex fractures were treated using subciliary approach. In Group B all 10 patients, having zygomatic maxillary complex fracture involving infraorbital rim and floor, were treated with transconjunctival approach. All the patients were operated by a single operator.

Following patients were included in the study:

1. Patients of age group 15-50 years.
 2. Patients having Zygomatico-Maxillary complex fractures with involvement of orbital floor, infraorbital rim fractures and other associated fractures which required open reduction and fixation.
- The patients were subjected to through pre-operative history, clinical examination, radiographs involving

paranasal sinus view (PNS) and computerized 3D scans involving Coronal, Axial, Saggital & 3D face reconstructions view.

Following patients were excluded from the study:

1. Functioning eye in monocular patient.
2. Acute or chronic Active conjunctival diseases.
3. Anophthalmic socket with an ocular prosthesis.
4. Previous scleral buckle procedure for retinal detachment.
5. Patients who were unfit for general anesthesia, medically compromised and immunocompromised patients were excluded from the study.
6. Blind Patients

Preoperative Evaluation

Evaluation of Soft Tissues

1. Ectropion:

Ectropion is an abnormal eversion (outward turning) of the lid margins away from the globe. Without normal lid globe apposition, corneal exposure, tearing, keratinization of the palpebral conjunctiva and visual loss may result. It mainly involves the lower eyelid and often has a component of horizontal laxity. (Table 1)

0	Normal eyelid appearance and function
I	Normal appearance but symptomatic; eyelid laxity present on examination
II	Scleral show without eversion of lower eyelid
III	Ectropion without eversion of lacrimal punctum
IV	Advanced ectropion with eversion of lacrimal punctum from lacrimal lake
V	Ectropion with complication (eg, conjunctival metaplasia, retraction of anterior lamella, or stenosis of lacrimal system)
L	Predominantly lateral
M	Predominantly medial
LM	Combined medial and lateral
r	Previous revision*

Table 1: Ectropion Grading Scale

2. Entropion

Condition is characterized by progressive inversion of lower eyelid margin, causing progressive irritation of ocular surface. Although conservative treatment with

ocular lubricants, tapping or botulism causing injections can produce temporary relief, surgical intervention require to definitely restore anatomical positioning. (Table. 2)

Grade	Definition
E0	(none) None
E1	(mild) <50 % of lid margin rolled inwards without cornea - lash base contact
E2	(moderate) >50% of lid margin rolled inwards without cornea -lash base contact
E3	(severe) Lid margin rolled inwards with <50% lash base - cornea contact
E4	(severe) Lid margin rolled inwards with >50% lash base - cornea contact

Table 2: Grading Scale of Entropion

3. Scar scale:

Absent	Noticeable scar	Hypertrophic Scar
0	1	2

Table 3: Grading Scale of Scar

4. Surgical exposure adequacy

5. Complications

Surgical Technique

For the Subciliary Approach Group, after the partial tarsoraphy was done the subciliary incision was marked about 2mm below and also parallel to the lid margin. Layer by layer dissection is done to reach upto the tarsal plate. Subperiosteal dissection is then performed to expose the fractured site.

For the Transconjunctival Approach Group, after traction sutures are placed on the lower lid through the tarsal plate. An incision was made 3-4mm on the conjunctival surface below the tarsus extending from the punctum of the lacrimal canaliculus to lateral orbital fissure. A plane of dissection is then created and as the orbital septum is freed it was lifted upward and inward.

For both the groups reduction of the fracture was performed and was held in their anatomic position using titanium mini plates and screws. Injury to the orbital structures and nerves was taken care of during incision, dissection and internal fixation. closure was done using vicryl and Ethilon.

Case 1

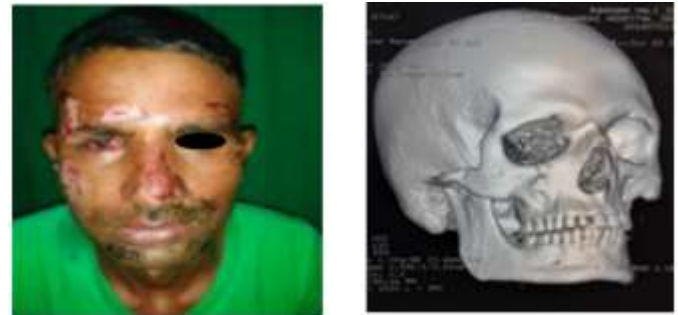

Figure 1: Preoperative Photograph and Scan

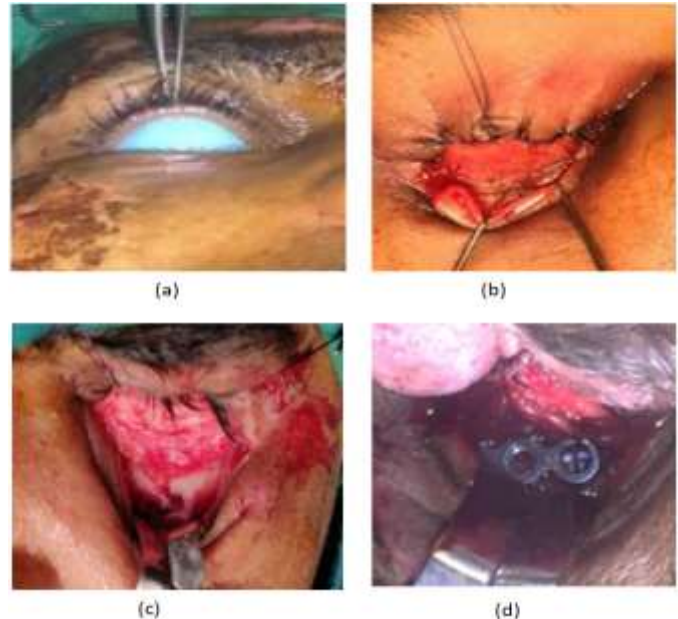

Figure 2: (a-d) Intraoperative photos depicting Transconjunctival Approach a) Placement of corneal shield b) Traction done to expose the tarsal plate c) Exposure of fracture site d) Secured with titanium plate

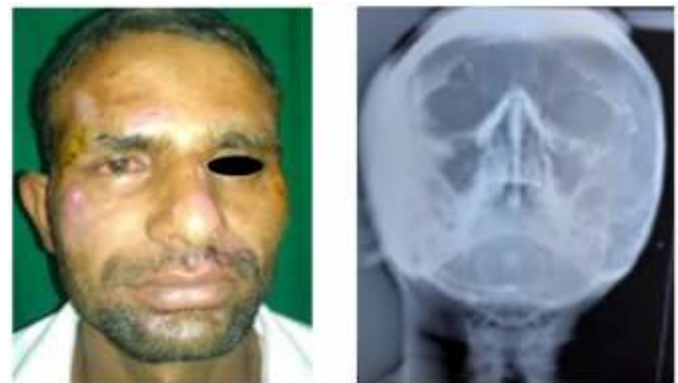

Figure 3: Follow Up Photos at 3months

Case 2

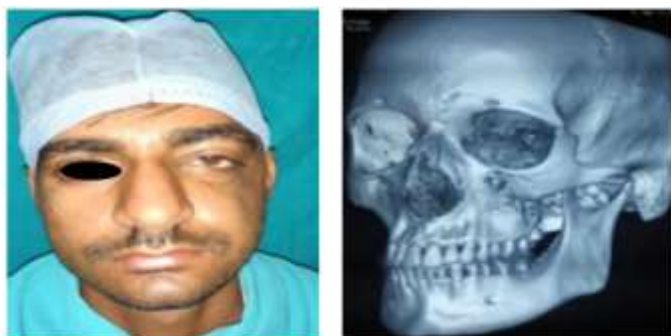

Figure 4: Preoperative Photographs and Scans

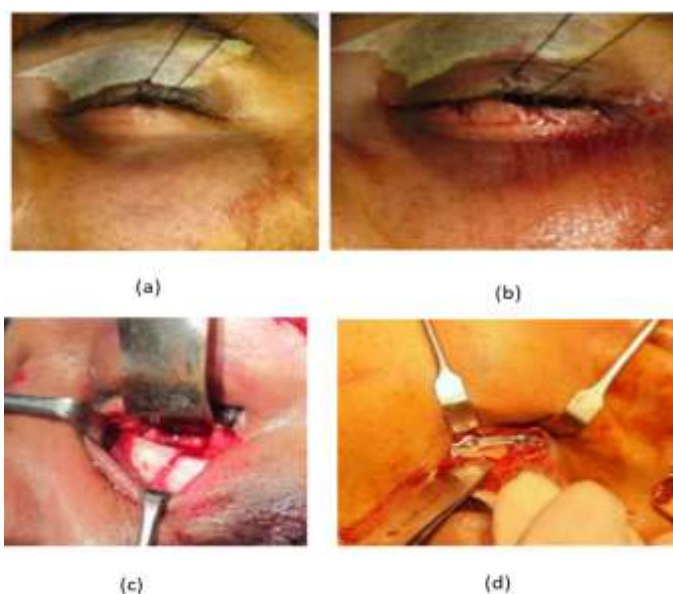


Figure 5: (a-d) Intraoperative photos depicting Subciliary Approach a) Partial tarsoraphy done b) Subtarsal incision given c) Exposure of fracture site d) Secured with titanium plate

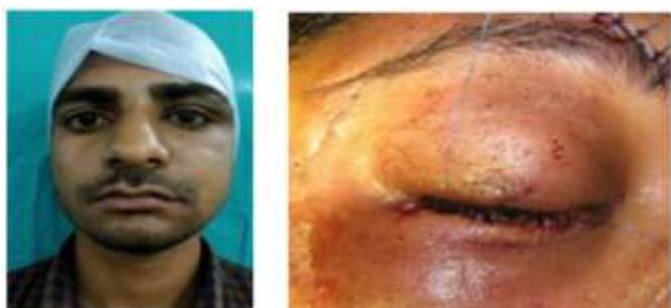

Figure 6: Post Operative Follow Up Photographs

Result

The data was coded and entered into Microsoft Excel spreadsheet. Analysis was done using SPSS version 20

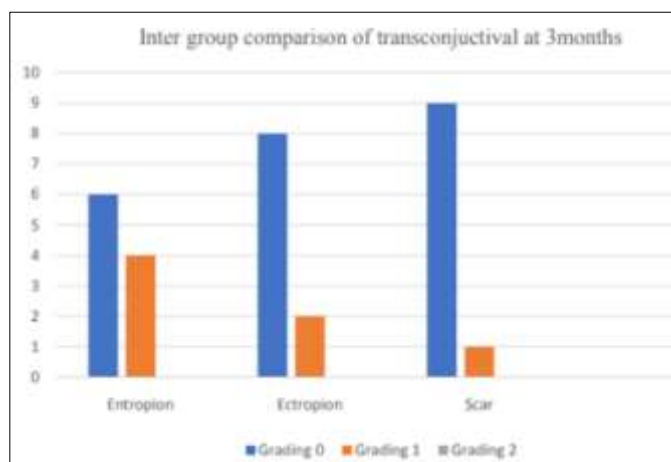
(IBM SPSS Statistics Inc., Chicago, Illinois, USA) Windows software program. Descriptive statistics included computation of percentages, means and standard deviations. The unpaired t test (for quantitative data to compare two independent two groups), and paired t test (for quantitative data to compare before and after observations) Level of significance was set at $P \leq 0.05$.

Following (Table I and Graph I) shows occurrence of entropion, ectropion and scar in *Transconjunctival Approach* at 3months of interval 40% cases shows entropion, 20% cases with ectropion and 10% cases shows scar formation at 3 months.

			Grading			Total
			0	1	2	
Group	Entropion	N	6	4	0	10
		%	60.0%	40.0%	0.0%	100.0%
	Ectropion	N	8	2	0	10
		%	80.0%	20.0%	0.0%	100.0%
	Scar	N	9	1	0	10
		%	90.0%	10.0%	0.0%	100.0%
Total		N	23	7	0	30
		%	76.6%	23.3%	0.0%	100.0%

P value=0.09

Table I:



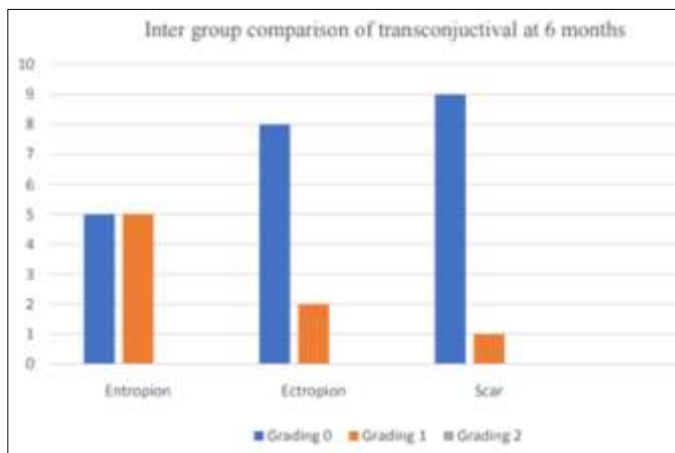
Graph I:

Following (Table II and Graph II) shows occurrence of entropion, ectropion and scar in Transconjunctival Approach at 6months of interval Showing 50% cases of entropion 20% of ectropion. Scar was seen in 10% of cases at 6months of interval.

			Grading			Total
			0	1	2	
Group	Entropion	N	5	5	0	10
		%	50.0%	50.0%	0.0%	100.0%
	Ectropion	N	8	2	0	10
		%	80.0%	20.0%	0.0%	100.0%
	Scar	N	9	1	0	10
		%	90.0%	10.0%	00.0%	100.0%
Total		N	23	8	0	30
		%	76.6%	26.6%	0.0%	100.0%

P value=0.09

Table II:



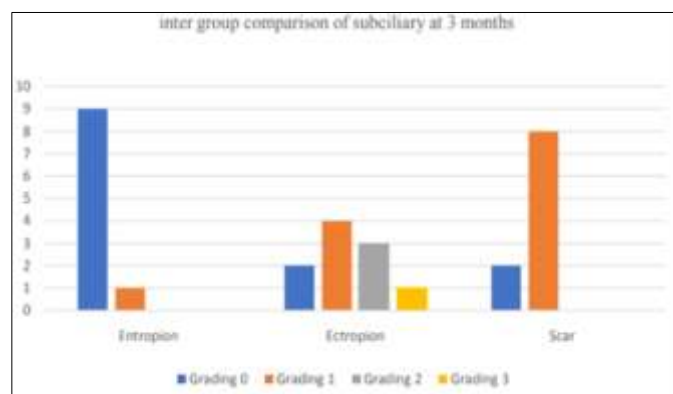
Graph II:

Following (Table III and Graph III) depicts occurrence of ectropion, entropion and scar in Subciliary Approach at 3 months of interval. 10% cases with mild entropion, 40% cases with mild ectropion, 30% cases with moderate entropion and 10% cases of severe ectropion. 80% of cases with scar formation.

			Grading				Total
			0	1	2	3	
Group	Entropion	N	9	1	0	0	10
		%	90.0%	10.0%	0.0%	0.0%	100.0%
	Ectropion	N	2	4	3	1	10
		%	20.0%	40.0%	30.0%	10.0%	100.0%
	Scar	N	2	8	0	0	10
		%	0.0%	80.0%	0.0%	0.0%	100.0%
Total		N	13	13	3	1	30
		%	43.33%	43.3%	10.0%	3.33%	100.0%

P value=0.001 (S)

Table III:



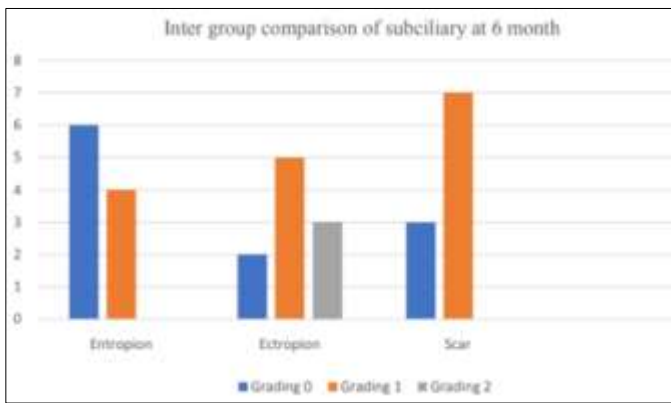
Graph III:

Following (Table IV and Graph IV) depicts the occurrence and severity of Ectropion, Entropion and Scar in Subciliary Approach at duration of 6months. 40% cases had mild entropion 40% cases with mild & 50% with moderate ectropion. 90% cases with mild scar formation at duration of 6 months.

			Grading			Total
			0	1	2	
Group	Entropion	N	9	1	0	10
		%	60.0%	40.0%	0.0%	100.0%
	Ectropion	N	2	5	3	10
		%	10.0%	40.0%	50.0%	100.0%
	Scar	N	3	7	0	10
		%	10.0%	90.0%	0.0%	100.0%
Total		N	14	13	3	30
		%	46.6%	43.3%	30.0%	100.0%

P value=0.001 (S)

Table IV:



Graph IV:

Following (Table V) shows the comparison between adequacy of both approaches to reach fracture site. *Transconjunctival Approach* was inadequate in 7 out of 10 patients in reaching fracture site. On the other hand, *Subciliary Approach* was found more adequate in 9 out of 10 patients in reaching fracture site. On the evaluation of data subciliary approach is more adequate than transconjunctival approach in reaching fracture site with statistically highly significant value of $p < 0.001$.

			Exposure		Total
			Adequate	Inadequate	
Groups	Transconjunctival	N	3	7	10
		%	30.0%	70.0%	100.0%
	Subciliary	N	9	1	10
		%	90.0%	10.0%	100.0%
Total		N	12	8	20
		%	60.0%	40.0%	100.0%

P value=0.006 (S)

P value=0.006 (S)

Table V:

Following (Table VI) shows comparison between both the approaches on the bases of complications. In *Transconjunctival Approach* 1 out of 10 patients had retraction injury. Whereas, none of the patient had such injury in *Subciliary Approach*. Hence no statistically non significant difference was found in between two approaches with $p \text{ value} > 0.001$.

			Complications		Total
			None	Retraction Injury	
Groups	Transconjunctival	N	9	1	10
		%	90.0%	10.0%	100.0%
	Subciliary	N	10	0	10
		%	100.0%	0.0%	100.0%
Total		N	19	1	20
		%	95.0%	5.0%	100.0%

P value=0.305

Table VI:

Discussion

In traditional approaches to the orbit, anterior orbitotomy is the broad term used to describe the surgical approach to the anterior half of the orbit. The location of the incision is determined by the desired quadrant of the orbit to be accessed. A cutaneous incision is made in various locations to access either the subperiosteal (via the orbital rim) or orbital (via the orbital septum) approach. Examples of orbital rim incisions include the direct brow, sub brow, Lynch, inferior rim, Kronlein, and lateral canthotomy. Eyelid incisions include upper lid crease, vertical lid-split, subciliary, and mid-tarsal. Each of these approaches is associated with pros and cons, and several have been abandoned due to their poor cosmetic outcome. The Lynch incision, for example, provides excellent exposure to the medial orbit, but there is a risk of medial canthal web formation and visible scarring. The subciliary approach to the orbital floor also allows for broad access, but can cause lower lid retraction and malposition.

The transconjunctival incision was first described in 1924 by Bourget for the removal of lower eyelid fat. Tessier was first to advocate this approach, to expose the orbital floor for treatment of congenital disease and trauma in 1973. McCord and Moses popularized transconjunctival surgery in the mid 1970's using

“Swinging Lower Eyelid Flap”. The ability to reach the periosteum through a transconjunctival incision allows access to a great portion of orbit. The transconjunctival approach to the orbit was introduced by Bourquet in 1928 and has gained popularity over the past 20 years (Bourquet, 1924). It has the advantage of hiding the scar behind the lower eyelid, so it is invisible. Also, it has the advantage of being capable of exposing not only the infraorbital rim and floor of the orbit, but, with medial extension, it can readily expose the medial wall of the orbit. Many studies have shown that the rate of complications with the transconjunctival approach is minimal.

In our study of 10 cases done with subciliary approach the frequency of soft tissue complications example ectropion, scar etc are more as compare to 10 cases done with transconjunctival approach, which appears to be aesthetically more pleasing. Loed et al⁸ frequently questioned whether scleral show and ectropion are varying degrees of same condition or are separate entities. Certainly both result from loss of muscle tonus and scar tissue formation between orbicularis muscle and surrounding soft tissue.

Bahr et al⁹ believe that ectropion is just a severe form of scleral show with lid eversion. To prevent ectropion and scleral show Converse 1981¹⁰ ; Manson et al 1987¹¹ ; Loeb 1989¹² have proposed preserving a pretarsal portion of orbicularis muscle in the maintenance of proper lower lid tonus. Of 10 cases done with Preseptal Transconjunctival Approach, 7 cases were done without lateral Canthotomy and the exposure obtained, thus was inadequate. Of the 3 cases of transconjunctival approach, supplemented with lateral canthotomy, the exposure obtained was adequate.

In our study, on the evaluation of data, subciliary approach is more adequate than transconjunctival approach

in reaching fracture site with statistically highly significant value of $p < 0.001$. Earlier studies considered transconjunctival approach for:

1. Children;
2. Older patients with existing eyelid laxity who are candidates for canthal resuspension;
3. Patients who form hypertrophic scars;
4. Scarophobic patients;
5. Patients undergoing reoperations; and
6. Patients with eyelid or cheek lacerations or abrasions, to avoid operating through a scar or creating adhesions between the skin and deep tissues.¹³

There are two different routes for the transconjunctival approach: retroseptal and preseptal. Many authors use retroseptal approach in blepharoplasty procedures and in treatment of orbital fractures, because of direct access to the orbital floor.

Disadvantages of retroseptal approach are:

1. Additional disturbances of the intraorbital connective framework.
2. Additional scar in the anterior part of the intraorbital fat system, which could influence the eye movements and can participate in the development of an enophthalmos.

Advantages of the preseptal transconjunctival approach are:

Minimal lateral scar and Decreased chances of eyelid retraction or ectropion¹⁴ Wray et al 2013 did study comparing 45 subciliary skin-muscle flap incisions to 45 retroseptal transconjunctival incisions undergoing orbital fracture repair. Four of the 45 eyelids treated by the subciliary approach required subsequent surgery to manage ectropion. There was only one case of ectropion in the transconjunctival group. One eyelid in the transconjunctival group was lacerated by traction; this

prompted the authors to perform a lateral canthotomy in 25 of the 45 transconjunctival approaches. So lateral canthotomy was added to the preseptal transconjunctival incision.

A retrospective study comparing 27 subciliary skin—muscle and 36 preseptal transconjunctival approaches in patients undergoing orbital fracture repair was described by Appling et al. (2014) and found a 12% rate of transient ectropion and a 28% rate of permanent scleral show with the subciliary skin-muscle flap compared with no transient ectropion and a 3% rate of permanent sclera show with the transconjunctival approach.

In a study, Arnulf Baumannn and Rolf Ewers 2014¹⁵ reported no complications in any patients with preseptal transconjunctival approach. But after a primary subciliary incision, complications included one laceration of tarsal plate and one temporary entropion. The overall complication rate was 2%. We observed that main drawbacks of the subciliary approach include the post-operative scarring and the risk for potential soft tissue complications. The main disadvantages of the transconjunctival approach are its technique sensitivity, a relatively higher percentage of lower eyelid malpositioning when combined with a lateral canthotomy and relatively limited exposure when used alone.

It was noted that although the exposure of the fractured bone took longer while using the transconjunctival approach and total time taken was more with this approach as more meticulous closure is needed. In our experience, the transconjunctival approach, if performed with adequate care, is a useful substitute to other cutaneous approaches to the periorbital region. Complications encountered are technique sensitive and can be totally avoided as reflected by our study. The lateral canthal incision heals well, with unremarkable

scar. The transconjunctival approach in hands of an experienced surgeon seems to be the best approach for orbital floor and infraorbital rim fracture.

Conclusion

Both the approaches have potential for sequelae and complications. The approach must be based, in part, on the surgeon's particular abilities in terms of preferred incision and also on the potential complications. By our study of 20 patients we can conclude that the subciliary approach is faster, gives good exposure of the infra-orbital rim and is better suited to reduce displaced fractures of the infra-orbital rim, but the risk of post operative scarring and other soft tissue complication are much higher. The transconjunctival approach is comparatively faster, gives better esthetic results and fewer post-operative complications but is technique sensitive and requires an additional lateral canthotomy in cases where more exposure is needed.

References

1. Eppley B L, Custer P L, Sadove A M. Cutaneous approaches to the orbital skeleton and periorbital structures. J Oral Maxillofac Surg 1990; 48:842-854.
2. Lorenz H P, Longaker M T, Kawamoto H K. Primary and secondary orbit surgery: the transconjunctival approach. Plast Reconstr Surg 1999; 103:1124-1128.
3. Wray R C, Holtmann B, Ribaud J M, Keiter J, Weeks P M. A comparison of conjunctival and subciliary incisions for orbital fractures. Br J Plast Surg 1977; 30:142-145.
4. Appling W D, Patrinely J R, Salzer T A. Transconjunctival approach vs subciliary skin-muscle flap approach for orbital fracture repair. Arch Otolaryngol Head Neck Surg 1993; 119:1000-1007.

5. Baumann A, Ewers R. Use of the preseptal transconjunctival approach in orbit reconstruction surgery. *J Oral Maxillofac Surg* 2001; 59:287-291.
6. Manganello-Souza L C, De Freitas R R. Transconjunctival approach to zygomatic and orbital floor fractures. *Int J Oral Maxillofac Surg* 1997; 26:31-34.
7. Zarem H A, Resnick J I. Expanded applications for transconjunctival lower lid blepharoplasty. *Plast Reconstr Surg* 1991; 88:215-220.
8. Dresner S C, Karesh J W. Transconjunctival entropion repair. *Arch Ophthalmol* 1993; 111:1144-1148.
9. Perkins S W, Dyer W K, Simo F. Transconjunctival approach to lower eyelid blepharoplasty. Experience, indications, and technique in 300 patients. *Arch Otolaryngol Head Neck Surg* 1994; 120:172-177.
10. Mullins J B, Holds J B, Branham G H, Thomas R. Complications of transconjunctival approach a review of 400 cases. *Arch Otolaryngol Head Neck Surg* 1997; 123:385-388.
11. Wesley R E. Transconjunctival approaches to the lower lid and orbit. *J Oral Maxillofac Surg* 1998; 56:66-69.
12. Wray R C, Holtmann B, Ribaud J M, Keiter J, Weeks P M. A comparison of conjunctival and subciliary incisions for orbital fractures. *Br J Plast Surg* 1977; 30:142-145.
13. Sailer H F. Osteosynthesis of orbital margin fractures via the transconjunctival approach using staples. *J. max.-fac. Surg* 1977; 5:184-186.
14. Holtmann B, Wray R C, Little A G. A randomized comparison of four incisions for orbital fractures. *Plast Reconstr Surg* 1981; 67:731-735.
15. McGraw B L, Adamson P A. Postblepharoplasty ectropion: prevention and management. *Arch Otolaryngol Head Neck Surg* 1991; 117:852-856.