

**Evaluation of Marginal Bone Levels In Subcrestally Placed Implants With Different Loading Protocols**

<sup>1</sup>Dr. Kanigicharla Sravani, Department of Prosthodontics & Implantology, MDS (Prosthodontics), Sibar dental college and hospital, Takkellapadu, Guntur, Andhra Pradesh, India

<sup>2</sup>Dr. Muvva Suresh Babu, Department of Prosthodontics & Implantology, Professor (Prosthodontics), Sibar dental college and hospital, Takkellapadu, Guntur, Andhra Pradesh, India

<sup>3</sup>Dr. T. Krishna Mohan, Department of Prosthodontics & Implantology, Professor (Prosthodontics), Sibar dental college and hospital, Takkellapadu, Guntur, Andhra Pradesh, India

<sup>4</sup>Dr. S. Asritha, Department of Prosthodontics & Implantology, Senior Lecturer (Prosthodontics), Care dental college and hospital, Guntur, Andhra Pradesh, India

<sup>5</sup>Dr. Arjuna Saradhi Chavidisetty, Department of Prosthodontics & Implantology, MDS (Prosthodontics), Sibar dental college and hospital, Takkellapadu, Guntur, Andhra Pradesh, India

**Corresponding Author:** Dr. Kanigicharla Sravani, Department of Prosthodontics & Implantology, MDS (Prosthodontics), Sibar dental college and hospital, Takkellapadu, Guntur, Andhra Pradesh, India

**Citation of this Article:** Dr. Kanigicharla Sravani, Dr. Muvva Suresh Babu, Dr. T. Krishna Mohan, Dr. S. Asritha, Dr. Arjuna Saradhi Chavidisetty, “Evaluation of Marginal Bone Levels In Subcrestally Placed Implants With Different Loading Protocols”, IJDSIR- April - 2023, Volume – 6, Issue - 2, P. No. 57 – 68.

**Copyright:** © 2023, Dr. Kanigicharla Sravani, et al. This is an open access journal and article distributed under the terms of the creative commons’ attribution non-commercial License. Which allows others to remix, tweak, and build upon the work non-commercially, as long as appropriate credit is given and the new creations are licensed under the identical terms.

**Type of Publication:** Original Research Article

**Conflicts of Interest:** Nil

**Abstract**

**Aim & Objectives:** To evaluate marginal bone levels and soft tissue changes in subcrestally placed implants with immediate progressive loading protocol and delayed loading protocol.

**Materials and Methods:** An in vivo study was conducted in the department of prosthodontics and implantology, SIBAR institute of dental sciences. Twenty edentulous patients with missing teeth were selected for the study. Patients were divided into two groups; Group-1 and Group-2. In Group- 1 patients, 10

implants were placed subcrestally with immediate progressive loading protocol. In Group 2, patients 10 implants were placed subcrestally with delayed loading protocol. Marginal bone levels were determined by digital IOPA with grid. Mucosal thickness was measured by using endodontic file no 20. Bleeding on probing was measured by using pressure sensitive probe.

**Results:** Higher marginal bone levels were seen in subcrestally placed implants with immediate progressive loading when compared to delayed loading with statistically significant difference. There was no much

statistically significant difference in both immediate progressive loading and delayed loading protocols regarding bleeding on probing, mucosal thickness during experimental time periods.

**Conclusion:** Within the limitations of this study, the following conclusion can be drawn: There was a significant change in bone levels in immediate progressive loaded and delayed loaded groups. There was no significant change in soft tissue adaptation in immediate progressive loaded and delayed loaded groups.

**Keywords:** Immediate progressive loading, delayed loading, Bleeding on probing, Thickness of mucosa.

### Introduction

In recent years patients awareness of dental implants and their expectations for treatment significantly increased.<sup>1</sup> The success of osseointegrated implants as an alternative to removable or tooth-supported prosthetic restorations has been proven by research over the last 30 years.<sup>2</sup> Year after year, modern engineering and research have generated increasingly more successful dental implants, but ultimate success is still dependent on the patient's and dentist's care of the peri-implant tissues.

Bone support and the stability of implant at bone crest are two aspects that may influence the success or failure of a dental implant. A biological width formed by the integration of epithelium and connective tissue supports and protects an abutment and implant from pathological effects.<sup>3</sup> It has been observed that if the biological width is changed in the apical direction, a corresponding loss of marginal bone occurs.<sup>4</sup>

The placement of an implant deeper in respect to the crest of the bone (subcrestal placement) has been suggested as a way for sustaining the peri-implant soft and hard tissues.<sup>5</sup>

In 1969 Branemark recommended implant placement below the bone crest to avoid implant exposure during the bone remodelling process. Subcrestal implant insertion engages more cortical bone while reducing stress on the surrounding bone. The likelihood of the metal top of the implant or the abutment margin being exposed is reduced when the implant is positioned apical to the bone, preventing contamination of the implant surface. It might provide enough vertical space to create a suitable aesthetic emergence profile.<sup>6</sup>

As a result, preventing peri-implant bone loss is critical to implant success. The amount and quality of bone around an implant impacts osseointegration and the form and contour of overlying soft tissues, all of which are significant for the treatment's aesthetic outcome.

For optimal tissue integration, it has been suggested that implants require a two-stage surgical approach and an extended load-free healing phase. The healing period was originally planned to be 6 months to reduce the possibility of failure.<sup>7</sup> Utilizing a modified (roughened) implant surface, using a wider diameter and aggressively engineered implant, and using a subcrestal approach to avoid implant loading stress are just a few of the particular concerns to keep in mind while placing implants. All of these techniques result in a larger implant surface area, which improves implant contact with the bone and stability.<sup>8</sup>

In recent times Immediate loading protocol attained popularity as it decreased the duration of treatment & also resulted in increasing the patient satisfaction, but in cases of soft bone immediate loading leads to failure of implant whereas immediate progressive loading permits maturation of bone during loading period without overloading the implant.

## Aim And Objectives

**Aim:** The aim of this study is evaluation of marginal bone levels in subcrestally placed implants with immediate progressive loading and delayed loading

## Objectives

- To evaluate marginal bone levels in immediate progressively loaded dental implants
- To evaluate marginal bone levels in delayed loaded dental implants
- Comparison of marginal bone levels in immediate progressively loaded and delayed loaded dental implants
- To evaluate mucosal thickness in immediate progressively loaded and delayed loaded dental implants
- To evaluate bleeding on probing in immediate progressively loaded and delayed loaded dental implants

## Materials And Methodology

The present study is assessment of the marginal bone levels and soft tissue changes around implant in the the Department of Prosthodontics and implantology, Sibar institute of dental sciences within a time period of 2019-2022 were selected for the study.

The parameters taken into consideration were marginal bone levels, bleeding on probing, mucosal thickness. A total of 20 patients aged 18-60 years divided into two groups , with 10 in each group Group 1 (immediate progressive loading), Group 2 (delayed loading) was done.

Subjects who meet the following criteria will be selected

## Inclusion criteria

- Patients aged 18-60 years
- Patients with partial edentulism
- Apparently healthy patients
- Patients with D2 and D3 bone density

- Individuals having sufficient bone quality, height and width

## Exclusion criteria

- Uncontrolled diabetes
- Pregnant and lactating patients
- Patients subjected to recent radiation therapy to head and neck region
- Untreated infections at the site of implant placement
- Severe bruxism or clenching

## Pre-operative evaluation

Detailed medical and dental history was taken. Patient is explained about the procedure and Informed consent form is obtained from the patient. Routine blood investigations were evaluated. Pre-operative photographs, radiographs (CBCT) and impressions were obtained on the initial screening and evaluation of first visit. The preoperative densities of bone were assessed through CBCT. Two piece implants were been selected for placement in edentulous site for both the groups. Surgical protocol included the standard operating procedure using surgical guide for the implant placement. After an individual period of healing, an impression was taken with elastomeric impression material and definitive restoration is fabricated using conventional method.

## GROUP 1(Immediate progressive loading):

### Procedure

o Before surgery the patient rinsed mouth with 0.12% chlorhexidine mouthwash. Local anaesthesia nerve block and infiltration with 2% lignocaine with 1: 80000 adrenaline administered under standard aseptic precautions and the thickness of the soft tissue was measured at a predetermined point using endodontic file number 20.

o Crestal and two vertical relieving incisions were given

- o The full thickness mucoperiosteal flap reflected to expose the underlying bone.
- o Point of entry gained through the guiding hole made in the surgical guide using a precession drill.
- o The implant bed preparation started with a standard pilot drill under copious internal and external irrigation of chilled saline.
- o Sequential drilling as per manufacturer instructions were done .
- o Angulation of osteotomy drill was checked using parallel pin.
- o Preselected implants were threaded into the prepared site at subcrestal level with an insertion tool.
- o Healing abutment is placed and bleeding on probing, mucosal thickness and marginal bone levels are evaluated.
- o IOPA radiographs along with x-ray grid were taken to assess marginal bone level.
- o Within 2 weeks temporary crown out of occlusion was given
- o After 1 month of implant placement, centric contact was established
- o At the end of 3rd month final impressions were made and final prosthesis was given and bleeding on probing, mucosal thickness and marginal bone levels were evaluated.
- o After 3 months of final prosthesis placement bleeding on probing, mucosal thickness, marginal bone levels were evaluated

## **GROUP 2(Delayed loading)**

### **Procedure**

- o Before surgery the patient rinsed mouth with 0.12% chlorhexidine mouthwash. Local anaesthesia nerve block and infiltration with 2% lignocaine with 1: 80000 adrenaline administered under standard aseptic precautions and the thickness of the soft tissue was

- measured at a predetermined point using endodontic file number 20.
- o Crestal and two vertical relieving incisions were given.
- o The full thickness mucoperiosteal flap reflected to expose the underlying bone.
- o Point of entry gained through the guiding hole made in the surgical guide using a precession drill.
- o The implant bed preparation started with a standard pilot drill under copious internal and external irrigation of chilled saline.
- o Sequential drilling as per manufacturer instructions were done .
- o Angulation of osteoto Preselected implants were threaded into the prepared site at subcrestal level with an insertion tool.
- o Suturing done using 3-0 silk suture .
- o IOPA radiographs along with x-ray grid were taken to assess marginal bone level.
- o Amoxicillin 500mg Ti Di for 5 days inflammatory medication tab diclofenac sodium Bid 3 days prescribed for all patients.
- o All patients were instructed to use chlorhexidine mouthwash twice daily for four weeks
- o Sutures removed after 7 days.
- o After 3 months cover screw was removed and healing cap was placed .
- o After 10 days of time interval healing cap was removed, Transfer coping was placed and elastomeric impression was made and implant analogue was attached to the coping and cast was obtained using type 4 dental stone .
- o Final prosthesis(Metal ceramic crown) was fabricated and cementation was done and bleeding on probing, mucosal thickness and marginal bone levels were evaluated.

o After 3 months of final prosthesis placement bleeding on probing, mucosal thickness, marginal bone levels were evaluated. omy drill was checked using parallel pin.

The following criteria was measured for assessment in the review period

o Marginal bone levels: IOPA Radiographs with grid taken with paralleling cone technique. Mesial and distal measurements are taken with the help of grids at the time of implant placement, 3rd month, 6th month.

The following criteria were measured for soft tissue changes

o Bleeding on probing: using pressure sensitive probe

o Mucosal Thickness: For measuring the thickness of gingiva an endodontic file number 20 is used. The file is inserted at the midpoint of attached gingiva between mucogingival junction and an imaginary line drawn from adjacent tooth CEJ to assess the mucosal thickness . The distance between the tip of file and rubber stop is recorded as the mucosal thickness using a digital caliper at baseline ,3rd and 6th month post operatively.

## Results

Table 1 depicts the comparison of mean mucosal thickness scores at baseline, 3 months and 6 months. At baseline the mean mucosal thickness in mm was  $0.98 \pm 0.20$  in immediate progressive loading group. The mean mucosal thickness was reduced to  $0.87 \pm 0.24$ , and then to  $0.78 \pm 0.19$  at three and six months follow up. In delayed loading group the mean mucosal thickness was lower at six months follow-up period i.e.  $0.68 \pm 0.11$  compared to baseline and 3 months follow-up period. Mucosal thickness reduced significantly from baseline to subsequent follow up periods ( $p < 0.05$ ) in both immediate progressive and delayed loading group. On pair wise comparisons statistically significant difference was observed from baseline to 6 months follow-up

period and from 3months to 6 months follow up period in both the groups ( $p < 0.05$ ).

Table 2, graph 1 depicts the intergroup comparison of mucosal thickness at baseline, 3 months and 6 months. There was no significant difference in mucosal thickness was observed between both the groups at baseline,3 months and 6 months.

Table 3 depicts the mean marginal bone level at mesial side at 3 months was higher in immediate progressive loading group i.e.  $0.46 \pm 0.31$  compared to delayed loading i.e.  $-0.10 \pm 0.61$ , and the difference observed was statistically significant ( $p = 0.026$ ).

The mean marginal bone level at mesial side at 6 months in immediate progressive loading group was  $-0.050 \pm 0.598$  and in delayed loading was  $-0.105 \pm 0.685$ , and there was statistically significant difference between the groups. ( $p = 0.003$ ).

Table 4 depicts that the mean marginal bone level at distal side at 3 months in immediate progressive loading group was  $0.45 \pm 0.437$  and in delayed loading was  $-0.05 \pm 0.64$ , and the difference observed was statistically non-significant ( $p = 0.059$ ). The mean marginal bone level at distal side at 6 months was higher in immediate progressive loading group i.e.  $0.050 \pm 0.550$  when compared to delayed loading i.e.  $-0.90 \pm 0.875$ , and the difference observed was statistically significant ( $p = 0.011$ ).

Graph 3 depicts the mean marginal bone level in both the immediate progressive and delayed loading groups. The mean marginal bone level on the mesial and distal sides was similar in both groups at baseline. Between the baseline and 6-month follow-up periods, there was a steady decline in mean marginal bone level at the mesial and distal sides in both groups.

## Discussion

Modern dentistry's ideal goal is to return the patient's shape, function, comfort, aesthetics, speech, and health to normal. The capacity to accomplish this ideal aim regardless of stomatognathic system atrophy, disease, or injury is what makes implant dentistry unique. Branemark is the first person to apply this idea to the dentistry. The best treatment option to replace a single missing tooth is a single-tooth implant, rather than preparing adjacent teeth and joining them together with a prosthesis. Since 1993, single-tooth implant survival has demonstrated that this procedure is the most predictable method of tooth replacement.<sup>9</sup>

The benefits of this modality include a lower risk of caries on the abutment teeth, a lower risk of endodontics on the abutment teeth, improved ability to clean the proximal surfaces of the adjacent teeth, a lower risk of cold or contact sensitivity while using a brush or scaler on the abutment teeth, improved aesthetics of the adjacent teeth, the preservation of bone in the edentulous site, and the psychological advantage (especially for congenitally missing or loss of a tooth after a crown restoration).<sup>10</sup>

The technique of progressive implant loading was developed by Misch in 1980 for implants placed in areas where poor bone density is present. This technique helps in maturation of bone during the loading period without overloading the implant and resulting in less crestal bone loss and early implant failure and enhances bone quality and density because bone could mature when tension during the prosthetic phase increases gradually without overloading the implant. This protocol uses transitional prostheses made of acrylic resin that minimally disturb the integration of the implant-bone interface during the healing phase.<sup>11</sup>

In delayed loading, the time gap present between placement of implant and eventual loading was long, and therefore patients had to deal with the functional concerns for quite some time while waiting for osseointegration and the fabrication of new prosthesis. In addition to functional concerns, the psychological impact of losing teeth can also be overwhelming to the patients.<sup>12</sup> Over time, the interest in immediate loading implants, for the most part, became patient driven. Now a days immediate loading of implants has become a reality not only in the partially edentulous patients but also, in edentulous patients.<sup>13</sup> But immediate loading of implants cannot be done in poor quality bone because loading may cause failure of implant when an implant is prematurely loaded into immature bone.<sup>14</sup> Immediate progressive loading can enhance bone quality by allowing time for maturation of bone without overloading implant and may offer an alternative solution when immediate implant loading is needed.<sup>15</sup>

Marginal bone loss was one of the most important criteria for evaluating implant success. Various researches revealed the relationship between the quality of bone at the implant site and crestal bone loss. Denser the bone present around the implant, less will be the crestal bone loss. If the amount of load exerted on the implant after placement is more, the intensity of crestal bone loss increases. The high intensity of load that was produced in some conditions such as bruxism, clenching, cantilevers etc also influence the crestal bone loss.<sup>9</sup>

Novaes et al suggested that the subcrestal location of the implants may have a positive impact on the maintenance or creation of a crestal bone peak in the inter-implant zone, according to the researchers. In the aesthetic areas, the presence of bone slightly beyond the top of the implant could be advantageous.<sup>16</sup> Isha Bhardwaj et al evaluated peri-implant soft tissue and bone levels around



early loaded implant in restoring single missing tooth. At 9 months, the dental implants had lost about 1 mm of crestal bone. Between the time of implant insertion and 3 months, clinically substantial marginal bone loss occurred. Following that, bone loss around the implant was negligible for the next 9 months. The maturity of the peri-implant soft tissue was maintained throughout the trial.<sup>17</sup>

This study aimed to evaluate marginal bone levels in implants with different loading protocols which involve immediate progressive loading and delayed loading protocol. The study did not have any confounding factor related bias as the study variables such as marginal bone levels, mucosal thickness and bleeding on probing did not show any significant difference at the time of implant placement. So, the influence of these parameters on the postoperative evaluation was negligible.

In the present study, marginal bone levels were measured using standard IOPA radiographs with the help of X-Ray grid. The X-ray grid consists of 1mm graduation superimposed on IOPA radiographs used for assessments the distance between alveolar crest and implant shoulder at the implant contact point were recorded at Mesial and distal areas of implants, assessed at the time of implant placement, 3 months and 6 months post operatively.

The marginal bone levels did not show any statistical significant difference at mesial, distal sites evaluated in both the groups at the time of implant placement. The selected patients were such that, they did not show any bone loss at the overall sites evaluated at the time of implant placement. The mean marginal bone level at all the sites evaluated was 1mm at the time of implant placement. When marginal bone levels were evaluated at the time of loading, the mean marginal bone levels were more in Group 1 than Group 2 statistical significant

difference was seen at mesial site when analyzed between the groups ( $p < 0.05$ ) whereas in distal side statistically non-significant difference was observed. The mean marginal bone level values evaluated at the time of loading in Group 1 at mesial was 0.46mm, at distal was 0.45mm. When Group 2 was evaluated, the mean marginal bone levels showed a mean value of -0.1mm at the mesial site, and -0.05mm at the distal site.

When marginal bone levels were evaluated after 3 months of loading, the mean marginal bone levels were more in Group 1 than Group 2, statistical significant difference was seen at mesial and distal site when analyzed between the groups ( $p < 0.05$ ). The mean marginal bone level values evaluated at three months after loading in Group 1 at mesial was -0.05mm, at distal was 0.05mm. When Group 2 was evaluated, mean marginal bone levels showed mean value of -1.05mm at the mesial site, and -0.9mm at the distal site. When changes in marginal bone levels were evaluated in Group 1 with change in time, Significant differences were observed in this intra-group comparison in the mesial, and distal marginal bone levels. Pairwise comparisons with post hoc tests revealed that all the possible time point pairs demonstrated a significant difference in marginal bone levels when mesial, distal aspect were separately considered except for mesial aspect where 3 months to 6 months statistically nonsignificant difference was observed. When changes in marginal bone levels were evaluated in Group 2 with a change in time, significant differences were observed in this intra-group comparison in the mesial, and distal sites. Pairwise comparisons with post hoc tests revealed that almost all the possible time point pairs demonstrated a significant difference in marginal bone levels when mesial, distal aspect were separately considered.

The results of the present study are in agreement with Ghozeizi et al where he performed a study but with a shorter healing period (2 months) and reported an increase in bone density when a Progressive loading protocol was used. They also found less crestal bone loss around progressively loaded implants when compared to the conventionally loaded group after 12 months.<sup>59</sup>

The results of present study are in agreement with Mohammed jasim AL juboorietal in 2018 where he evaluated that the implants placed in posterior region of maxilla have high incidence of implant failure due to poor bone quality, especially when immediate implant loading is needed. It was concluded that compared to delayed loading, progressive loading can enhance bone density and implant stability, resulting in greater early functionality and fewer surgery sessions.<sup>18</sup>

The results of present study are in agreement with study done by Rami M. Galal etal in 2022 where author assessed the effects of early, immediate, and progressive loading of dental implants clinically and radiographically Progressive loading demonstrated significantly less crestal bone loss than conventional one.<sup>19</sup>

In the present study marginal bone levels are higher in group 1 where Immediate progressive loading protocol is used when compared to group 2 where delayed loading protocol is used and statistically significant difference is present. This is because dense trabeculae develop around progressively loaded implants and major increase in density and amount was observed in the crestal region.<sup>20</sup>

Mucosal thickness measured using endodontic file number 20 with a rubber stopper. The file will be inserted at a predetermined reference point to assess the mucosal thickness the distance between the tip of the file and the rubber stopper was record recorded has the

mucosal thickness using a digital caliper third and sixth month post-operatively. The standard protocol for evaluation of the mucosal thickness was similar to previous studies assessed.<sup>20-23</sup>

When study results were evaluated in regards to mucosal thickness assessed at different experimental time periods, themucosal thickness did not show any statistical significant difference evaluated in both the groups at the time of implant placement, at the time of implant loading, 3 months after loading. When mucosal thickness was evaluated at the time of implant placement, no statistical significant difference was seen at different sites analyzed in both the groups ( $p>0.05$ ). Although the mean mucosal thickness was more in Group 1 than Group 2 at the time of implant placement, there was no statistically significant difference elicited in both the groups analyzed. The mean mucosal thickness values evaluated at the time of implant placement in Group 1 are 0.98mm and 0.91mm in Group 2. When mucosal thickness was evaluated at the time of implant loading, no statistical significant difference was seen at different sites analyzed in both the groups ( $p>0.05$ ). Although the mean mucosal thickness was more in Group 1 than Group 2 at the time of implant placement, there was no statistically significant difference elicited between the two groups. The mean mucosal thickness values evaluated at the time of implant loading in Group 1 was 0.98mm whereas 0.91mm in Group 2. When mucosal thickness was evaluated at 3 months after the implant loading, no statistical significant difference was seen at different sites analyzed in both the groups ( $p>0.05$ ). There was an increased mucosal thickness in Group 1 as compared to the other group analyzed. The meanmucosal thickness values evaluated three months after the implant loading in Group 1 are 0.78mm and 0.68mm in Group 2. With regard to mucosal thickness, a



significant decrease was observed with time in Group 1 and Group 2, this difference was significant. On pair wise comparisons statistically significant difference was observed from time of implant placement to 6 months follow-up period and from 3 months to 6 months follow up period in both the groups ( $p < 0.05$ ).

Bleeding on probing measured using pressure-sensitive probe at baseline, 3rd and 6th month postoperatively. The probe is passed along the gingival sulcus with the force of 0.25N/cm wait for 30 seconds to score the bleeding index. The scoring criteria were adopted from the modified sulcular bleeding index by Muhlemann and son. The width of gingiva and orientation of collagen fibers maintain periimplant health. In peri-implant sulcus, collagen fibers are present parallel to the implant surface, and whereas for natural teeth, collagen fibers are orientated perpendicularly and anchored to cementum, in the condition of absence of horizontal collagen fibers. This will lead to local tissue trauma, and bleeding will result.<sup>63</sup>

When study results were evaluated in regards to bleeding on probing assessed at different experimental time periods, there was no bleeding on probing at the time of implant placement in immediate progressive and delayed loading group. The mean bleeding on probing at the time of loading and three months after loading in group 2 increased to 0.80. In group 1 the mean bleeding on probing was higher at three months after loading i.e. 0.70. On pair wise comparisons statistically significant difference was observed from baseline to 3 months and 6 months follow-up period in group 1 where as in group 2, significant difference was observed from baseline to 6 months follow up period ( $p < 0.05$ ).

To perform a reliable evaluation, only the type of loading was different, all other implant characteristics (implant material, surface characteristics and macro

design) remained exactly the same. When previous literature on each and every parameter analyzed in the present study have to be compared, criteria for assessment and the study protocol although remained similar to the different parameters assessed, not all studies have evaluated the mucosal thickness, marginal bone levels, bleeding on probing. The present study is the first one to evaluate all the three parameters in the same study design. However, previous study design was conducted in patients to evaluate the effect of different loading protocols on marginal bone levels in patients. They did not evaluate the soft tissue parameters, which do play an important role in the healing and the success of the placed implants. So, our study was comprehensive in evaluating all the parameters assessed.

So, our study results showed the same pattern of bone loss values, and the results were in correlation with the data. The other reliable soft tissue parameters were also considered in the present study, which lacked in the previous literature. The entire results based on high evidence-based systematic reviews showed the enhanced peri-implant bone levels in progressive loading protocol as compared to the other types. The reason for favourable results observed for progressive loading protocol in sub crestally placed implants are progressive loading improves bone quality and density by allowing time for bone maturation during healing period. All these positive added benefits were demonstrated for the progressive loading protocol and Subcrestal placement in the above mentioned high evidence-based data.

Our study results, although included a shorter sample size with smaller assessment times, the reason for the immediate progressive loading to show better outcome data may be attributed to all the above-mentioned reasons discussed. When the available data high evidence-based data till date was analyzed regarding to

the effects of different loading protocols on the peri-implant marginal bone levels was assessed, the data suggested a significant difference between the progressive loading and delayed loading. The data proved better performance with the progressive loading as compared to the delayed loading protocols. Within the considered limitations of the reviews assessed till date, it can be concluded that different types of implant loading protocols can make it possible to achieve successful implant-prosthetic rehabilitation. The peri-implant bone level is generally higher in the progressive loading protocol.

MUCOSAL THICKNESS		Mean	SD	F-value	p-value
Immediate progressive loading	Baseline	0.98	0.20	18.181	0.000*
	3 months	0.87	0.24		
	6 months	0.78	0.19		
Delayed loading	Baseline	0.91	0.14	38.103	0.000*
	3 months	0.87	0.14		
	6 months	0.68	0.11		

p<0.05 statistically significant, Repeated measures ANOVA test, LSD post

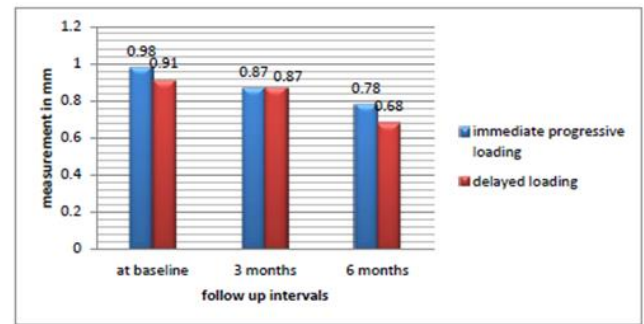
hoc test

Table 1: Intragroup comparison of mean mucosal thickness at baseline, 3 months and 6 months in both the groups.

MUCOSAL THICKNESS	Immediate progressive loading		Delayed loading		P-value
	Mean	SD	Mean	SD	
Baseline(at the time of implant placement)	0.98	0.20	0.91	0.14	0.398
3 months	0.87	0.24	0.87	0.14	1.00
6 months	0.78	0.19	0.68	0.11	0.189

\*P<0.05 statistically significant, Independent t test

Table 2: Intergroup comparison of mucosal thickness at baseline, 3 months and 6 months



Graph 1 : comparison of mucosal thickness among immediate progressive and delayed loading group at different time intervals

Mesial Marginal bone level	Immediate progressive loading		Delayed loading		P-value
	Mean	SD	Mean	SD	
Baseline	1	0.00	1	0.00	-
3 months	0.46	0.371	-0.100	0.614	0.026*
6 months	-0.050	0.598	-1.050	0.685	0.003*

\*P<0.05 statistically significant, Independent t test

Table 3: Intergroup comparison of mesial marginal bone level at baseline, 3 months and 6 months

Distal Marginal bone level	Immediate progressive loading		Delayed loading		P-value
	Mean	SD	Mean	SD	
Baseline	1	0.00	1	0.00	-
3 months	0.45	0.437	-0.05	0.6433	0.059
6 months	0.05	0.550	-0.90	0.875	0.011*

\*P<0.05 statistically significant, Independent t test

Table 4: Intergroup comparison of distal marginal bone level at baseline, 3 months and 6 months

## Conclusion

The present study “Evaluation of marginal bone levels in subcrestally placed implants with different loading protocols” done in the Department of Prosthodontics and Crown and Bridge including Implantology, Sibar Institute of Dental Sciences, Guntur. Patients presented to the department of prosthodontics with a single missing tooth within the age range of 18-60 years were

enrolled in the study. The parameters taken into consideration were marginal bone levels, bleeding on probing, mucosal thickness. The conclusions drawn from the study were:

Higher marginal bone levels were seen in subcrestally placed implants with immediate progressive loading when compared to delayed loading with statistical significant difference

There was no much statistical significant difference in both immediate progressive loading and delayed loading protocols regarding bleeding on probing, mucosal thickness during experimental time periods.

As the implants were placed 1mm subcrestally it compensates for the crestal bone loss that occurs due to bone remodelling process.

## References

1. Roccuzzo M, Aglietta M, Cordaro L. Implant loading protocols for partially edentulous maxillary posterior sites. *International journal of oral & maxillofacial implants*. 2009 Oct 2;24.
2. Moraschini V, Poubel LD, Ferreira VF, dos Sp Barboza E. Evaluation of survival and success rates of dental implants reported in longitudinal studies with a follow-up period of at least 10 years: a systematic review. *International journal of oral and maxillofacial surgery*. 2015 Mar 1;44(3):377-88.
3. Albrektsson T, Zarb G, Worthington P, Eriksson AR. The long-term efficacy of currently used dental implants: a review and proposed criteria of success. *Int j oral maxillofac implants*. 1986 Jan 1;1(1):11-25.
4. Berglundh T, Lindhe J. Dimension of the periimplant mucosa: biological width revisited. *Journal of clinical periodontology*. 1996 Oct;23(10):971-3.
5. Pellicer-Chover H, Díaz-Sánchez M, Soto-Peñaloza D, Peñarrocha-Diago M, Canullo L, Peñarrocha-Oltra D. Impact of crestal and subcrestal implant placement upon changes in marginal peri-implant bone level. A systematic review. *Medicina oral, patología oral y cirugía bucal*. 2019 Sep;24(5):e673.
6. Adell R, Hansson BO, Brånemark PI, Breine U. Intra-osseous anchorage of dental prostheses. *Scandinavian journal of plastic and reconstructive surgery*. 1970 Jan 1;4(1):19-34.
7. Parr GR. Tissue-integrated prostheses: Osseointegration in clinical dentistry: Per-Ingvar Branemark, MD, Ph. D., George A. Zarb, DSS, MS, FRCD (C), and Thomas Albrektsson, MD, Ph. D. Chicago, 1985.
8. Mesa F, Muñoz R, Noguerol B, Luna JD, Galindo P, O'Valle F. Multivariate study of factors influencing primary dental implant stability. *Clinical oral implants research*. 2008 Feb;19(2):196-200.
9. Misch CE. Density of bone: effect on surgical approach, and healing. *Contemporary implant dentistry*. 1999:371-84.
10. Misch CE. *Dental Implants prosthetics*. 2nd edition. Elsevier: Mosby; 2015
11. Perel ML. Progressive prosthetic transference for root form implants. *Implant Dent*. 1994;3:42-46
12. Esposito M, Grusovin MG, Achille H, Coulthard P, Worthington HV. Interventions for replacing missing teeth: different times for loading dental implants. *Cochrane Database Syst Rev*. 2009 Jan 21;(1):CD003878.
13. Phillip Worthington, *Osseointegration in Dentistry*, Quintessence publishing, 1994.
14. Charles A. Babbush, *Dental Implants-The art and science*, Saunders, 2011.

15. Roberts WE, Garetto LP, DeCastro RA. Remodeling of devitalized bone threatens periosteal margin integrity of endosseous titanium implants with threaded or smooth surfaces: indications for provisional loading and axially directed occlusion. *J Indiana Dent Assoc.* 1989 Jul-Aug;68(4):19-24.
16. Adell R, Lekholm U, Rockler B, Brånemark PI, Lindhe J, Eriksson B. Marginal tissue reactions at osseointegrated titanium fixtures: A 3-year longitudinal prospective study. *Int J Oral Maxillofac Surg* 1986; 15:39- 52.
17. Appleton RS, Nummikoski PV, Pigno MA, et al. A radiographic assessment of progressive loading on bone around single osseointegrated implants in the posterior maxilla. *Clin Oral Implants Res.* 2005 Apr;16(2):161-7.
18. Khorshid HE, Hamed HA, Aziz EA. The effect of two different immediate loading
19. Singh JP, Gupta AK, Dhiman RK, Chowdhury SR. Comparative study of immediate functional loading and immediate non-functional loading of monocortical implants. *Med j Armed Forces india.* 2015; 71:333-339
20. Kamleshwar Singh, Arun Ramachandran, Jitendra Rao, Niraj Mishra, SunitJurel, Kaushal Kishor Agrawal. A Prospective Study To Compare Crestal Bone Loss And Radiographic Bone Density Of Different Implant Systems Subjected To Immediate Functional Or Non Functional Loading. *J Dent Med Sci.* 2018 ;17(11):48-53.
21. Payne AG, Tawse-Smith A, Kumara R, Thomson WM. One-year prospective evaluation of the early loading of unsplinted conical Brånemark fixtures with mandibular overdentures immediately following surgery. *Clin Implant Dent Relat Res.* 2001;3(1):9-19.
22. Aimetti M, Ferrarotti F, Mariani GM, Ghelardoni C, Romano F. Soft tissue and crestal bone changes around implants with platform-switched abutments placed nonsubmerged at subcrestal position: a 2-year clinical and radiographic evaluation. *International Journal of Oral & Maxillofacial Implants.* 2015 Nov 1;30(6).
23. Romanos GE, Aydin E, Gaertner K, Nentwig GH. Long-term results after subcrestal or crestal placement of delayed loaded implants. *Clinical implant dentistry and related research.* 2015 Feb;17(1):133-41.