

A Rare Case of Inflammatory Paradental Cyst on The Distobuccal Aspect of Impacted Mandibular Third Molar

¹Aliya Khan, BDS, MDS, PG Student (Second Year), Department of Oral and Maxillofacial Surgery, M A Rangoonwala College of Dental Sciences and Research Centre, Pune.

²Alka Sherkhane, BDS, MDS, Reader, Department of Oral and Maxillofacial Surgery, Yashwantrao Chavan Dental College and Hospital, Ahmednagar.

³Dhriti Garde BDS, Private Practitioner.

⁴Janardhan Garde, BDS, MDS, Prof and Head of Department, Department of Oral and Maxillofacial Surgery, M A Rangoonwala College of Dental Sciences and Research Centre, Pune.

⁵Sharayu Dhande, BDS, MDS, Department of Periodontology and Oral Implantology, Assistant Professor, Sinhgad Dental College and Hospital, Pune.

Corresponding Author: Sharayu Dhande, BDS, MDS, Department of Periodontology and Oral Implantology, Assistant Professor, Sinhgad Dental College and Hospital, Pune.

Citation of this Article: Khan A, Sherkhane A, Garde D, Garde J, Dhande S, “A Rare Case of Inflammatory Paradental Cyst on The Distobuccal Aspect of Impacted Mandibular Third Molar”, IJDSIR- November - 2023, Volume – 6, Issue - 6, P. No. 120 – 128.

Copyright: © 2023, Aliya Khan, et al. This is an open access journal and article distributed under the terms of the creative common’s attribution non-commercial License. Which allows others to remix, tweak, and build upon the work non-commercially, as long as appropriate credit is given, and the new creations are licensed under the identical terms.

Type of Publication: Case Report

Conflicts of Interest: Nil

Abstract

The inflammatory paradental cyst (IPC) is one of the most common odontogenic cysts known to be associated with distal and buccal aspect of partially impacted mandibular third molars. Pericoronitis or a periodontal pocket could be traced as one of the sources of routes of inflammation. The inflammatory proliferation of epithelial rests of malassez is thought to be the pathogenesis behind its origin. Quite a scant literature has been found on IPC due to mis-diagnosis or lack of published literature till date. The present case shows confirm diagnosis of Inflammatory Paradental Cyst on the histopathological sections and was treated by

surgical intervention. Post-operative follow-up showed uneventful healing.

Keywords: inflammatory paradental cyst, odontogenic cyst, impacted mandibular molar, pericoronitis, epithelial rests

Introduction

Vedtofte and Praetorius suggested the use of the descriptive term ‘Inflammatory paradental cyst (IPC)’, because of its inflammatory origin and also due to its location at the side of the tooth. In addition, Main described it as ‘inflammatory collateral cyst’, the paradental cyst is an odontogenic cyst of inflammatory origin, which occurs on the buccal, distal, or, less

commonly, mesial aspects of partially erupted and impacted mandibular third molar teeth.¹ Hofrath in 1930, was the first author to report several cysts located distally to mandibular third molar associated with pericoronitis.^{2,3} According to the World Health Organization (WHO), the paradental cyst is defined as a cyst that occurs near the cervical margin of the lateral aspect of a root as a consequence of an inflammatory process in the periodontal pocket. Hofrath (1930) had reported several cases of a jaw cyst located distal to mandibular third molars with clinical signs of pericoronitis and named it “marginal wisdom tooth cyst”.³

The incidence and prevalence of these IPCs varied from 1% - 5% amongst all odontogenic cysts. Craig in 1976 introduced the term ‘Paradental Cysts’ (PCs). Craig and Phillipsen stated male : female ratio to be 1: 0.4. The paradental cyst has been frequently referred to by numerous other names too, such as inflammatory collateral cyst, mandibular infected buccal cyst, mandibular buccal bifurcation cyst, inflammatory lateral periodontal cyst, and inflammatory paradental cyst, Craig’s cyst, buccal bifurcation cyst, cystis paradentalis, Hofrath’s mandibular cyst and eruption pocket cyst.⁴ Appropriate clinic-radiographical presentation and histopathological presentation would help us to differentiate the inflammatory paradental cyst from other odontogenic cysts.⁵ Few authors advocated the reason behind formation of PCs to be the reduced enamel epithelium and epithelial cell rests of Malassez.⁶⁻⁸

Some authors suggested that these epithelial remnants in response to inflammatory stimuli further proliferate potentially, giving rise to several different odontogenic cysts including the PCs. However, Ackerman et al had a different point of view, according to him if epithelial cell rests of malassez were responsible for this development,

then PCs would have been distributed equally covering the root surface. Few other hypothesis could be origin from the crevicular epithelium and epithelial remnants of the dental lamina.⁹

The major clinical feature of the PC is the pain (moderate to severe and radiating at times) discomfort, suppuration from the periodontal pocket, presence of a recurring inflammatory periodontal process, usually pericoronitis.¹⁰⁻¹¹ The buccal aspect of mandible is the most common site for development of IPCs owing to the eruption sequence of mandibular first molar, rarely it does manifests on mesial aspect.^{12,13} Often misdiagnosed as dentigerous cysts, peri-apical or radicular cysts, pericoronitis, lateral periodontal cysts or even inflamed dental follicles.¹⁴

The most commonly affected tooth for IPCs is mandibular third molar (Ackermann et al 1987; Fowler and Brannon 1989; Trask et al 1985; Vedtofte and Praetorius, 1989) followed by mandibular second molar and lastly, mandibular first molar.^{6,14} Fowler and Brannon 1989 advocated enucleation of complete infected cyst with extraction of the offending tooth to be the treatment of choice for such IPCs.¹⁵

The authors report a case of inflammatory paradental cyst on the distobuccal aspect of right impacted mandibular third molar.

Case Presentation

A 22 years old male patient reported to the clinic with the chief complaint of pain and swelling in lower right back region of jaw since last 2-3 months. He was initially asymptomatic, he then started experiencing pain in lower right back region of jaw associated with swelling which was initially localized and gradually increased to the present size. He complained of food impaction associated with third molar on right side and was unable to chew from right side since more than a

month. There was no purulent discharge noted in that region.

Extra-oral examination revealed presence of swelling in the buccal and distal aspect of right side of mandible over the angle of the mandible. Submandibular lymph nodes were non-palpable. Moreover, Intra-oral examination a partially impacted right mandibular third molar with presence of pericoronitis distal to it. Radiographic interpretation states radiolucency present on distal aspect of mandibular third molar of approximately 2cm in diameter surrounded by intact lamina dura and widened periodontal ligament space, positive response to vitality tests.

The initial line of treatment was Phase I therapy included ultrasonic scaling and root planning followed by oral hygiene maintenance. Routine haematological investigations were performed and a written informed consent was obtained from the patient.

In the surgical phase, local anaesthesia (2% lignocaine hydrochloride) was infiltrated in the region of mandibular right first molar. The surgical approach was a full-thickness trapezoidal flap, with gingival crevicular incision and vertical releasing incisions in the region of 48. Enucleation of the cystic lesion was carried out followed by peripheral osteotomy with simultaneous extraction of 47 and 48. Numerous small tissue specimens measuring 1.6 x 1 x 1.4 cm in size and firm in consistency, irregular lobular surface, shape and borders were further sent for histopathological examination in 10% NBF solution.

Chemical cauterization was carried out with application of Carnoy's solution was carried out for 5 minutes on the affected part so as to reduce further chances of recurrence. Utmost care was taken to preserve surrounding healthy tissues by placing dry gauze buccally and lingually prior to application of Carnoy's

solution. Finally, irrigation with 10% povidone iodine and saline was carried out and interrupted suturing carried out with 3-0 non-resorbable suture. Patient was recalled after a week for suture removal. No post-operative complications were seen. Wound healing was found uneventful at 3 months follow-up visit.

Radiographic Interpretation: CBCT scan of Mandible of FOV 11 X 8 was performed on Planmeca Romexis 3D Classic. Axial, coronal and sagittal sections of resolution 0.015mm (High definition) were obtained at 1 mm interval.

Site: Single, large, unilocular, expansile radiolucent lesion noted in the right-side angle and ramus region of mandible, associated with the impacted tooth 48.

Size And Shape: The lesion is roughly oval in shape, approximately measuring 39.34mm.

Antero-Posteriorly, Bucco-Lingual 17.60mm, Supero-Inferiorly 24.41 mm.

Thinning, expansion and perforation of buccal and lingual cortical plates noted.

External resorption of roots of 47 and 48 noted.

Extent

Antero-Posteriorly the lesion extends from mesial aspect of mesial root of 47 towards anterior border of ramus of mandible.

Bucco-Lingual the lesion extends from the buccal cortical plate to the lingual cortical plate.

Supero-Inferiorly the lesion extends from Inferior Alveolar nerve canal towards sigmoid notch of ramus of mandible.

Borders of the Lesion: Borders of the lesion are well defined.

Internal Structure of The Lesion: Internal structure of the lesion is predominantly radiolucent with Presence of impacted 48.

Effects on the surrounding structures

Thinning, Expansion and perforation of buccal and lingual cortical plates noted.

Inferior Alveolar Nerve Canal is Displaced in lingual and lower direction.

Inferior Alveolar Nerve Canal noted in close contact with involvement of superior cortical outline.

External resorption of roots of 47 and 48 noted.

Radiographic Diagnosis: Dentigerous Cyst with 48

Provisional Diagnosis: Periapical cyst

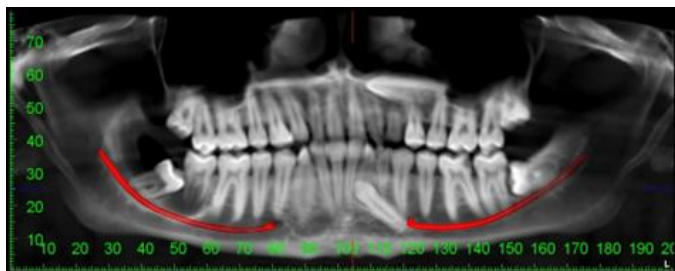
Differential Diagnosis: Paradental cyst, Dentigerous cysts, Lateral periodontal cyst, Periostitis ossificans

Histopathology: The H and E stained section of the submitted tissue sample shows hyperplastic non-keratinized stratified squamous epithelium of varying thickness. Epithelium exhibits proliferation in an arcading pattern. An intense inflammatory cell infiltrate is observed in the adjacent fibrovascular connective tissue capsule. The connective tissue is moderately collagenous with diffuse dense mixed inflammatory cells, predominantly neutrophils, lymphocytes and plasma cells. Numerous, endothelium lined blood vessels, extravasated RBCs, and trabeculae of bone are also seen in the connective tissue stroma. The above features are suggestive of “**Inflammatory Paradental Cyst.**”

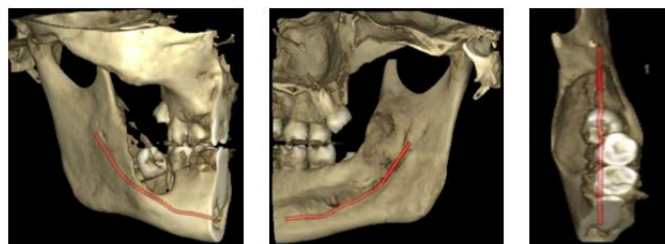
Final Diagnosis: Inflammatory Paradental Cyst

Clinical Images

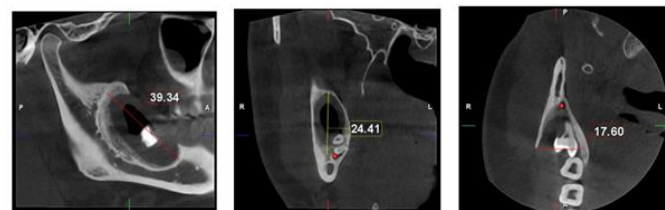
Pre-Operative Orthopantomogram



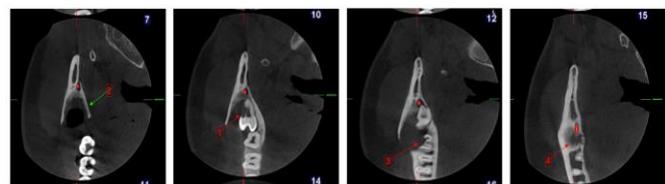
3D Reconstructed Images: Buccal View, Lingual View, Occlusal View



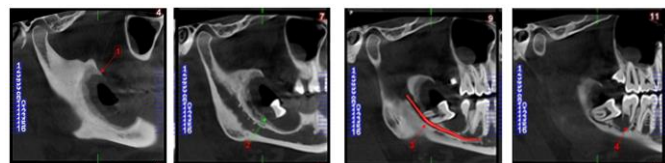
Cyst Dimensions On CBCT Slices: Cyst Dimensions



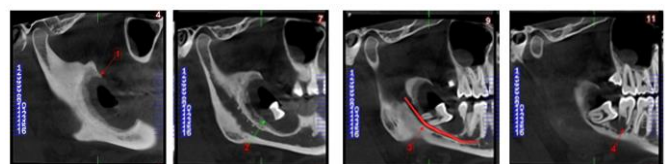
Axial Sections



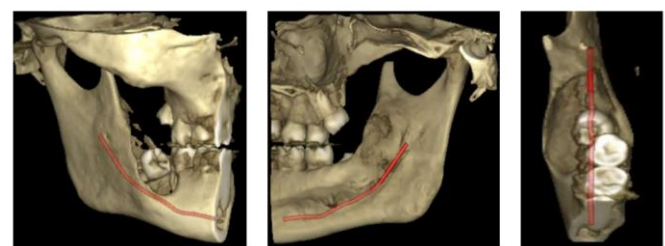
Coronal Sections



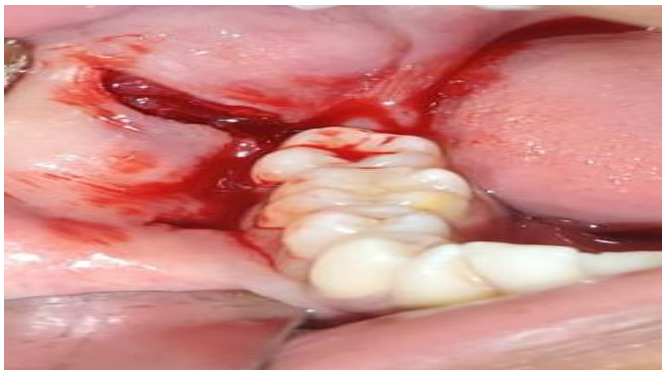Sagittal Sections



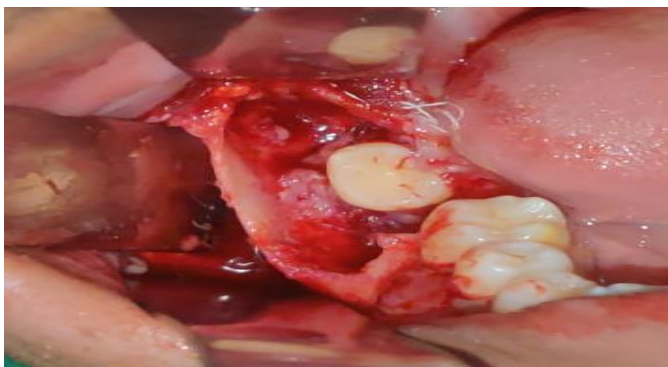3D Reconstructed Images: Buccal View, Lingual View, Occlusal View



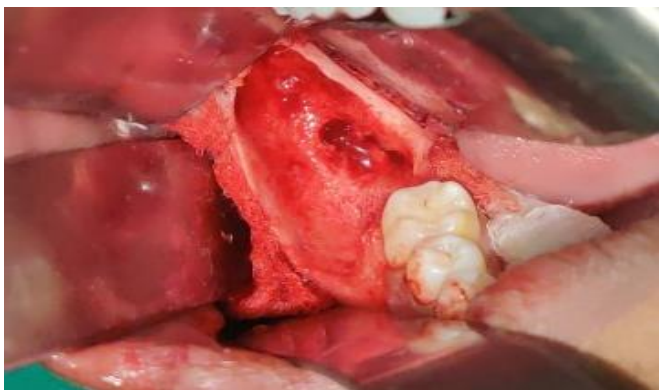Incision and reflection of full thickness flap



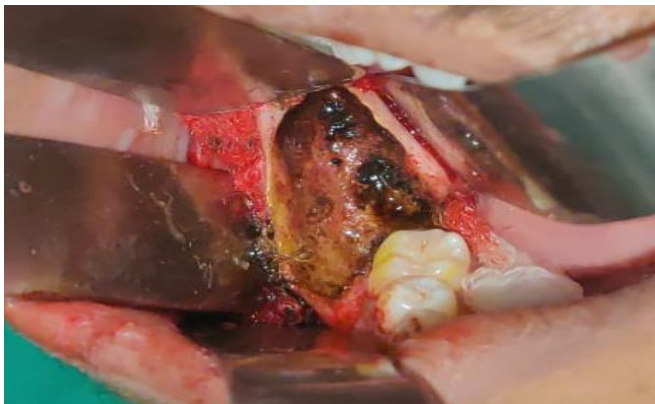
Enucleation of the Cyst



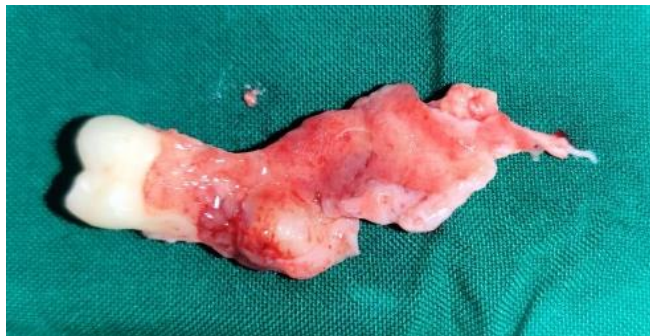Extraction Of Mandibular Third Molar



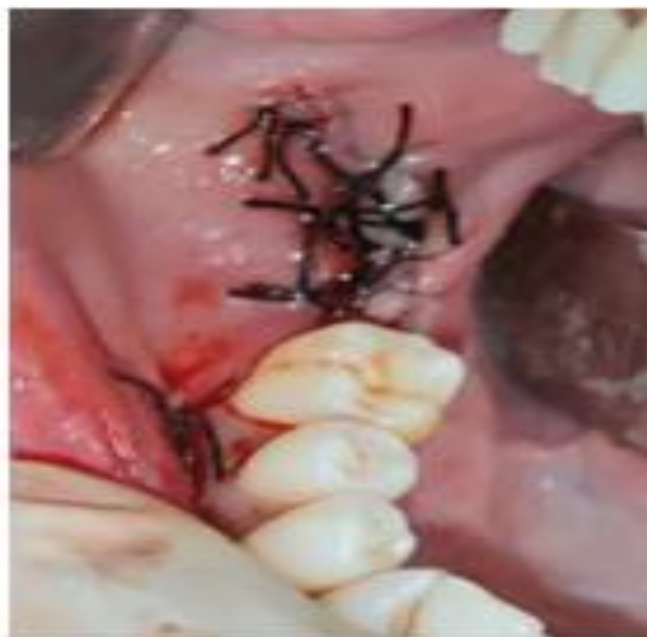Application of Carnoy's Solution



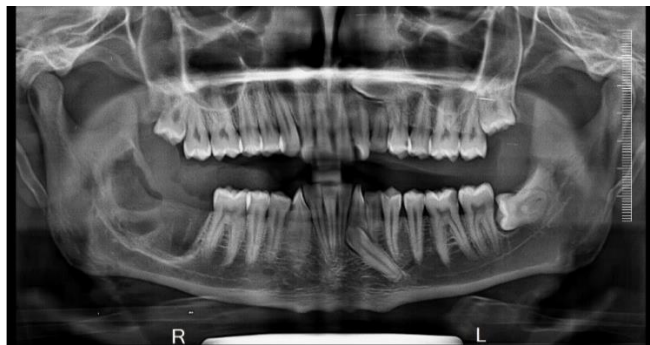Specimen Sent For Histopathology



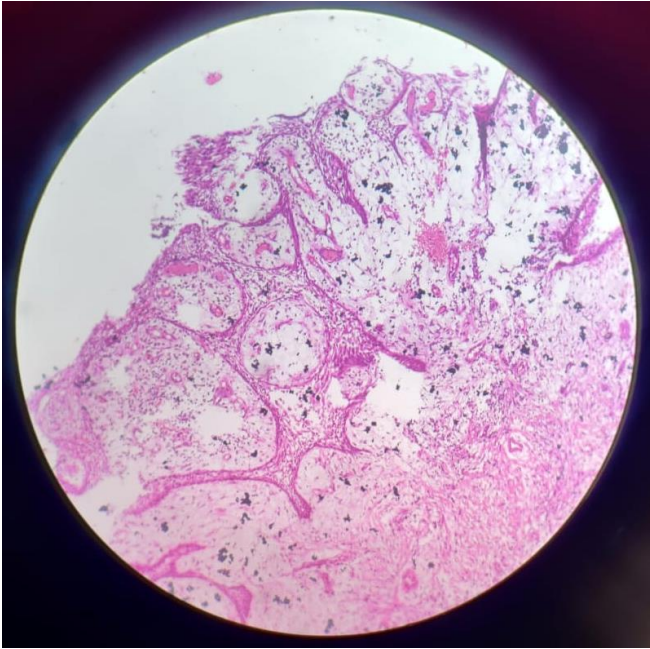
Interrupted Suturing Carried Out With 3-0 Black Silk Sutures



Post-Operative Orthopantogram



Histopathology



Discussion

In the present case, pain and swelling and occasionally food impaction in lower right back region of jaw since last 2-3 months. Since, the inflammatory component is not of endodontic origin, the periodontal ligament space and the lamina dura are intact and continuous around the root of the affected tooth. Assessment of vitality of the involved teeth was carried out with an electric pulp tester. Both 47 and 48 showed vital pulp that confirms the diagnosis of IPC. Since, non-vitality of the pulp associated with a cyst more commonly suggests a lateral radicular cyst rather than IPC. The inflammatory process in the soft tissue causes the occlusion of the opening of the periodontal pocket within the peri-coronal soft tissues, further this leads to the accumulation of fluid within the obstructed periodontal pocket which later leads to cystic expansion.¹⁶

According to Phillipsen et al, 61.4% of the 342 cases studied were associated with the 3rd mandibular molar, while 35.9% were found to be associated with either the 1st or 2nd mandibular permanent molars. In the present case, too mandibular third molar was known to be

affected. While, IPCs are rarely seen to be involving incisors, canines and premolars. Moreover, out of 109 cases of PC in 1st or 2nd mandibular molars reviewed by Phillipsen et al, 26 cases (23.9%) occurred bilaterally. In addition, there was only unilateral involvement of IPC in the present case.¹⁵⁻¹⁶

IPCs commonly appear on buccal aspects and rarely on the mesial aspect of partially or fully erupted vital teeth. One of the most common reason for it could be the eruption sequence of teeth, especially the mesio-buccal cusp is the first to break through the oral mucosa and get exposed to the oral environment. Other local anatomical factors (crown form, fissure pattern, adjacent teeth, and gingival architecture) may also influence the precise location of the cyst.¹⁶

Few diagnostic criteria that highlight Paradental Cyst and help differentiate it from other odontogenic cysts : ¹⁷

1. The associated tooth must be partly or fully erupted with direct contact with the cyst in a distal or distobuccal location.
2. The vital pulp of the involved tooth to be evaluated by electrometrical testing.
3. The clinical signs/history of associated pericoronitis or periodontitis
4. An intact periodontal ligament space of the involved tooth on radiographic evaluation.
5. Radiographic evidence of the preservation of the distal follicular space (Colgan's sign), indicating that the follicle is not involved in the process of cyst development.
6. The presence of dense inflammatory infiltrate on histopathological examination.

Craig suggested the hyperplasia and cystic change in reduced enamel epithelium could be one of the cause for development of this cyst. He also suggested that the presence of an extension of reduced enamel epithelium

over the enamel projections might be the source and could explain the frequent buccal location of the cyst. The present case of IPC was seen involving the distobuccal aspect of mandibular third molar. Hence, the buccal location of the paradental cyst could be one of the distinguishing features compared with other odontogenic cysts.

In regard to the lower third molars, this can be considered the second most frequent cyst, representing up to 25% of the cystic lesions, although they represented only 1.6% of the cystic lesions amongst that reported by Colgan et al.¹⁸

The onset of a vestibular swelling seems to be associated exclusively to the paradental cyst. Since the lesion is localized to the vestibular aspect of the roots, the involved molar is usually tilted, so that the root apices are adjacent to the lingual cortex with the crown showing buccal tipping. There is often presence of a communication between the periodontal pocket and the cystic lumen, but the cortical expansion of the bone is not so frequent unlike other cysts arising from odontogenic epithelium. The majority of lesions fail to exceed 15 mm of diameter. On the contrary, the cystic dimensions in the present case were quite remarkable; measuring 39.34mm Antero-Posteriorly, Bucco-Lingual 17.60mm, Supero-Inferiorly 24.41 mm.

Few authors like Colgan studied the aetiology behind Inflammatory paradental cyst (IPDCs) and believed that the resultant inflammatory process of food impaction within the surrounding soft tissues leads to the occlusion of the peri-coronal periodontal pocket. Further, fluid accumulates within this obstructed pocket owing to the osmotic processes as a consequence of the inflammation, leading to expansion of the cystic lesion. Histologically, the cysts are indistinguishable from radicular cysts. The lining usually consists of hyperplastic, non-keratinized,

spongiotic stratified squamous epithelium. The fibrovascular connective tissue capsule is a seat of an intense chronic or mixed inflammatory infiltrate.¹⁹⁻²⁰

The treatment of choice for mandibular first and second molars is enucleation of the cyst with preservation of the affected tooth. Similarly, surgical extraction of the offending tooth along with total enucleation of the cystic lesion is the treatment of choice for mandibular third molar. In the present case, the involved tooth was mandibular third molar and as a result; total enucleation of the cystic lesion along with extraction of the tooth was the treatment of choice carried out.

Few studies viz; Chrcanovic Bruno et al 2011¹⁹, Borgonovo et al 2013²⁰, Mony V et al 2017²¹, Vasudev et al 2018²² treated cases of paradental cyst with enucleation of the cyst followed by extraction of the involved tooth in case of third molars. This was in accordance with the present study. Similarly, another case carried out by Kumar LK et al 2022²³ reported IPC in an 18 years old female patient and treated it with cyst enucleation followed by surgical removal of mandibular third molar with simultaneous preservation of inferior alveolar nerve. Moreover, in the present case there was no direct involvement of inferior alveolar nerve and as a result, preservation of it was not required.

Conclusion

To the best of our knowledge spontaneous healing of the paradental cyst has not been reported in the literature published till date. Few factors like superimposition of anatomical structures, presence of infection, and lesion size and location can vary from the radiographic presentation of the IPC. Furthermore, the authors advocate correlation of clinical, radiographic and histologic findings in order to obtain final diagnosis of such lesions. There are very less reports of recurrence of IPC, but care should always be taken as authors did in

the present case, enucleation followed by chemical cauterization. Retention or extraction of the offending tooth differs from case to case and every case should hence be treated with caution.

References

1. Gomez RS, De Oliveira JR, Castro WH. Spontaneous regression of a paradental cyst. *Dentomaxillofacial Radiology*. 2001 Sep 1;30(5):296.
2. Hofrath H. U"ber das Vorkommen von Talgdr"sen in der Wandung einer Zahncyste, zugleich ein Beitrag zur Pathogenese der Kiefer-Zahncysten. *Deutsche Monatsschr Zahnheilk*. 1930;48: 65–76.
3. Craig GT. The paradental cyst: a specific inflammatory odontogenic cyst. *Br Dent J*. 1976;141: 9–14.
4. Silva TA, Batista AC, Camarini ET, Lara VS, Consolaro A. Paradental cyst mimicking a radicular cyst on the adjacent tooth: case report and review of terminology. *Journal of endodontics*. 2003 Jan 1;29(1):73-6.
5. Kreidler J, Raubenheimer EJ, van Heerden WFP. A retrospective analysis of 367 cystic lesions of the jaw: the Ulm experience. *J Craniomaxillofac Surg*. 1993;21: 339–41.
6. Philipsen HP, Reichart PA, Ogawa I, et al. The inflammatory paradental cyst: a critical review of 342 cases from a literature survey, including 17 new cases from the author's files. *J Oral Pathol Med*. 2004;33: 147–55.
7. Fowler CB, Brannon RB. The paradental cyst: a clinicopathologic study of six new cases and review of the literature. *J Oral Maxillofac Surg*. 1989; 47:243–8.
8. Kanno CM, Gulinelli JL, Nagata MJ, et al. Paradental cyst: report of two cases. *J Periodontol*. 2006;77: 1602–6.
9. Ackermann G, Cohen M, Altini M. The paradental cyst: a clinicopathologic study of 50 cases. *Oral Surg Oral Med Oral Pathol*. 1987;64: 308–12.
10. Stoneman DW, Worth HM. The mandibular infected buccal cyst: molar area. *Dent Radiogr Photogr*. 1983;56:1–14.
11. Bsoul SA, Flint DJ, Terezhalmay GT, et al. Paradental cyst (inflammatory collateral, mandibular infected buccal cyst). *Quintessence Int*. 2002; 33:782–3.
12. Souza SOM, Correˆa L, Deboni MC, et al. Clinicopathologic features of 54 cases of paradental cyst. *Quintessence Int*. 2001; 32:737–41.
14. Lim AA-T, Peck RH-L.
13. Bilateral mandibular cyst: lateral radicular cyst, paradental cyst, or mandibular infected buccal cyst? Report of a case. *J Oral Maxillofac Surg*. 2002; 60:825–7.
14. Morimoto Y, Tanaka T, Nishida I, et al. Inflammatory paradental cyst (IPC) in the mandibular premolar region in children. *Oral Surg Oral Med Oral Pathol Oral Radiol Endod*. 2004; 97:286–93.
15. Fowler, C. B. & Brannon, R. B. (1989). The paradental cyst. A clinicopathologic study of six new cases and review of the literature. *Journal of Oral and Maxillofacial Surgery*, 47, 243.
16. Colgan CM, Henry J, Napier SS, Cowan CG. Paradental cysts: a role for food impaction in the pathogenesis? A review of cases from Northern Ireland. *British Journal of Oral and Maxillofacial Surgery*. 2002 Apr 1;40(2):163-8.

17. Slater LJ. Dentigerous cyst versus paradental cyst versus eruption pocket cyst. *Journal of oral and maxillofacial surgery*. 2003 Jan 1;61(1):149.
18. Kumar LS, Kurien NM, Tharakan M, Adersh GA, Thuruthel MJ, Raghavan VB. Inflammatory Paradental Cyst: A Case Report and Literature Review. *Journal of Scientific Dentistry*. 2022 Dec 17;12(1):23-6.
19. Chrcanovic BR, Reis BM, Freire-Maia B. Paradental (mandibular inflammatory buccal) cyst. *Head and neck pathology*. 2011 Jun; 5:159-64.
20. Borgonovo AE, Grossi GB, Maridati PC, Maiorana C. Juvenile paradental cyst: presentation of a rare case involving second molar. *Minerva Stomatol*. 2013 Oct 1;62(10):397-404.
21. Mony V, LK SK. Inflammatory paradental cyst on the distobuccal aspect of an impacted mandibular third molar: a case report. *Int j case rep images*. 2017;8(9):592-6.
22. Vasudev SB, Iyengar AR, Kotni RM, Tiwari D, Agarwal R. Paradental cyst of mandibular third molar-A case report. *International Journal of Medical and Dental Case Reports*. 2018;5(1):1-4.
23. Surej Kumar LK, Kurien NM, Mathew Tharakan AG, Thuruthel MJ, Raghavan VB. Inflammatory Paradental Cyst: A Case Report and Literature. *Journal of Scientific Dentistry*. 2022 Jan;12(1):24.