

An orthodontic-restorative treatment of patient with missing maxillary central incisor

¹Dr. Kshama Kudchadkar, MDS, Assistant Professor, Department of Orthodontics and Dentofacial Orthopaedics, Goa Dental College and Hospital, Bambolim, Goa.

²Dr. Puja Sunil Jadekar, Post Graduate Student, Department of Orthodontics and Dentofacial Orthopaedics, Goa Dental College and Hospital, Bambolim, Goa.

³Dr. Anushka A. M. Mesquita, Lecturer, Department of Orthodontics and Dentofacial Orthopaedics, Goa Dental College and Hospital, Bambolim, Goa

Corresponding Author: Dr. Kshama Kudchadkar, MDS, Assistant Professor, Department of Orthodontics and Dentofacial Orthopaedics, Goa Dental College and Hospital, Bambolim, Goa.

Citation of this Article: Dr. Kshama Kudchadkar, Dr. Puja Sunil Jadekar, Dr. Anushka A. M. Mesquita, “An orthodontic-restorative treatment of patient with missing maxillary central incisor”, IJDSIR- June - 2023, Volume – 6, Issue - 3, P. No. 446 – 453.

Copyright: © 2023, Dr. Kshama Kudchadkar, et al. This is an open access journal and article distributed under the terms of the creative common’s attribution non-commercial License. Which allows others to remix, tweak, and build upon the work non-commercially, as long as appropriate credit is given and the new creations are licensed under the identical terms.

Type of Publication: Original Research Article

Conflicts of Interest: Nil

Abstract

Comprehensive management of missing central incisor presents a greater challenge in dentistry. This case report describes the successful interdisciplinary treatment of a patient with class I malocclusion with bimaxillary dental protrusion with a missing right maxillary central incisor and treated with three first premolar extraction protocol. The treatment consisted of a team approach combining carefully performed orthodontic space closure and aesthetic remodelling and restoration on substituted teeth. This treatment provided a satisfying outcome with maximum functional and aesthetic improvement.

Keywords: interdisciplinary, missing incisor, tooth substitution.

Introduction

Comprehensive management of an avulsed maxillary central incisor presents a difficult diagnostic dilemma. The most important treatment decision should be one that is comprehensible but more importantly, it should best meet patient’s esthetic and functional needs. Therefore, it is beneficial to use an interdisciplinary treatment approach to obtain satisfactory results. There are various treatment options available for replacement of an avulsed tooth including orthodontic space closure, single-tooth implants and tooth-supported restorations¹⁻³. Recently, resin-bonded bridge became a popular substitute for conventional bridge that leaves the adjacent teeth untouched which is particularly important in young patients and unrestored dentition. However,

resin-bonded bridges have a poor long-term prognosis for retention⁴. Since the introduction of implants into dentistry in the mid-1980s, they have become a promising substitute for conventional and resin-bonded bridges. Although high success rates for implants and implant-supported prosthesis can be expected, unesthetic soft and hard tissue changes around implant-supported porcelain crowns are frequent^{5,6}. In adolescent patient, however, implant placement has to be deferred until cessation of vertical growth.

Considering the above characteristics and socio-economic status and occlusion of the patient, a further option of orthodontic space closure was adopted. However, this approach requires the lateral incisors to assume the functional and esthetic role of central incisors; the canines become the lateral incisors and the first premolars take the role of canines, with all the prosthetic camouflage that the positional changes require.

This case report describes the treatment of a patient with class i malocclusion with bimaxillary dental protrusion with a missing right maxillary central incisor and treated with three first premolars extraction.

Diagnosis and Etiology

A male patient aged 15years reported with a chief complaint of a gap in front teeth and replacement of missing upper front tooth. No relevant medical history was reported. Patient reported with a history of fall 7 years ago with resultant avulsion of upper right central incisor (11) and fracture of the upper left central incisor (21) that was later endodontically treated and showed discoloration. The patient wore a removable denture to replace the missing tooth (11).

Extraoral examination indicated brachycephalic skull and europsopic face with a convex facial profile, average mandibular plane angle and acute nasolabial

angle. The frontal view showed increased interlabial gap and consciously competent lips at rest with sufficient incisor show on smiling and normal vertical relations (fig1a). Tmj examination did not reveal any pathology.

On intraoral examination, all teeth except the previously avulsed maxillary right central incisor and impacted third molars, were erupted in the oral cavity. Molar relationship was angle's class i on left side and end-on on right side. There was 5mm of overjet and deep overbite of 5mm. Maxillary midline was shifted by 2mm to the right. The mandibular incisors appeared proclined and moderately crowded (7.5mm tooth size-arch length discrepancy) (fig1b). Bolton's ratio showed mandibular anterior tooth material excess of 3mm.

The cephalometric analysis indicated class ii skeletal relationship with prognathic maxilla and retrognathic mandible, average growth direction, proclined, protruded and extruded maxillary and mandibular incisors, increased overjet and deep overbite. Standard pre-treatment panoramic and lateral cephalogram views were obtained (fig1c).

Treatment Objectives

- Correction of proclined and protruded maxillary and mandibular incisors.
- Relief of lower anterior crowding.
- Correction of deep overbite and leveling of curve of spee in the lower arch.
- Maintaining class, I molar and canine on left side and obtaining the same relationship on right side.
- Correction of maxillary midline relative to that of facial midline.
- Replacement of missing 11 and restoration of fractured 21.
- Reduction of upper and lower lips protrusion and obtaining lip competence with good vertical tooth-lip relations.

Treatment Alternatives

1. Extraction of all first premolars and prosthetic replacement of 11.
2. Extraction of 24,34 and 44 and utilization of edentulous space of 11 to correct incisor proclination and crowding that would avoid the need for permanent prosthesis and prevents extraction of an additional tooth

Treatment Plan

- Extraction of 24, 34, 44 and utilization of existing upper edentulous space to correct upper incisor protrusion and lower anterior crowding.
- Mesialisation of 12 into edentulous space of 11 and restorative treatment to simulate 11.
- Recontouring of 13 and 14 as 12 and 13 respectively. Recontouring of the canine cusp tip to simulate the lateral incisor and palatal cusp of 14 to function as canine.
- Restoration of fractured 21 and prosthetic full crown.

Treatment Progress

Following extraction of 24, 34 and 44 first permanent molars were banded and preadjusted edgewise fixed appliances (0.22" slot MBT prescription) were placed in upper and lower arches. The arches were leveled, aligned and coordinated for a period of six months with light 0.016" HANT wires. Thereafter 0.018" and 0.022" Australian stainless-steel wires with reverse spee in the lower arch were placed for a period of 2 months to aid in correction of deep overbite. Subsequently 0.019" × 0.025" rigid rectangular steel wires with curve of spee in upper and reverse spee in the lower were placed. Retraction hooks were incorporated in the upper and lower archwires. Enmass retraction was done by applying active tiebacks. Anchorage control was

accomplished by lacebacks, bendbacks and the use of light forces.

12, 13 and 14 were mesialised to simulate 11, 12 and 13 respectively. The case was completed on 0.019" × 0.025" SS archwire and finished on 0.016" SS and settling elastics (1/8") with total treatment time of approximately 22 months. Subsequently after debonding, the patient was placed on retention with upper and lower removable retainers.

Esthetics were enhanced by composite build-up of 12 to simulate 11. Mesiodistal width and contouring of cusp of 13 was done to simulate 12 along with extrusion to achieve ideal gingival height. Palatal cusp of 14 was recontoured to prevent functional interferences when simulating the role of 13.

Treatment Results

Clinically significant retraction of upper and lower anterior teeth was achieved. Intraorally, there was a dramatic improvement in dental esthetics. The tooth size-arch length discrepancy was eliminated in both arches, satisfactory tooth alignment was obtained and overjet and overbite were improved resulting in reduced lip protrusion and normal lip competency with adequate vertical tooth-lip relations (Fig2A). Extraction of three premolars and mesialisation of right segment facilitated coordination of the dental midlines with the facial midline. The class I relation was maintained on left side and class II canine relation was obtained on right side, with canine replacing right maxillary lateral incisor and premolar replacing the right maxillary canine (Fig2B).

Cephalometric analysis showed significant changes in the soft-tissue profile and maxillomandibular relationship (Table1). The post treatment panoramic radiograph showed healthy supporting tissue and adequate root parallelism in both arches (Fig 2C).

Discussion

Missing anterior teeth can interfere with facial esthetics and pose a clinical dilemma. The clinician is presented with a wide spectrum of treatment options such as orthodontic space closure, implant-supported prosthesis, tooth-supported restorations, however, for any of the opted treatment modality, many challenges are involved in obtaining and retaining the optimal results. The major advantages of orthodontic space closure for young patients with a missing incisor and co-existing malocclusion are the permanence of finished results and possibility to complete the treatment in early adolescence^{7,8}. With the selected treatment protocol in this patient, not only permanent prosthesis was avoided but also the final anterior esthetic appearance was satisfactory.

The four premolar extraction protocol is the most frequent treatment approach for Angle's class I malocclusion with crowding and dentoalveolar protrusion. However, this patient also had an edentulous space of missing maxillary central incisor along with lower anterior crowding and proclined anterior teeth. These characteristics and the concern about the esthetics suggested the option of extracting 3 premolars and closing the spaces by retraction of anterior teeth and substituting lateral incisor, canine and first premolar for central incisor, lateral incisor and canine respectively. This treatment alternative not only prevented extraction of additional tooth but also avoided permanent prosthesis that would have involved cutting of abutment teeth to replace the pontic.

Treatment time of these extraction protocols should also be considered. The number of extracted premolars has a direct relationship to treatment time, according to Fink and Smith⁹. Treatment time is increased by 0.9 months for each extracted premolar. The patient treated with

asymmetric three-premolars extraction can be treated faster than those having four-premolars extraction, not only because of the easier orthodontic mechanics but, also because of fewer extracted teeth.

In this patient, substitution with the lateral incisor facilitated correction of maxillary anterior esthetics. Furthermore, lateral incisor was intruded to the gingival height of the adjacent central incisor and composite build up was done to compensate for clinical crown height and width, thereby enhancing the microesthetics^{10,11}.

When the canines substitute the lateral incisors, greater labiolingual dimension can cause occlusal interference with mandibular teeth. Therefore, palatal trimming at every visit is necessary to alleviate occlusal prematurities. The cusp tip and labial surface were reduced to produce a flat incisal edge and composite build up at mesial and distal angles of the canine were done to complete canine transformation. Long-term studies have illustrated the benefits of canine substitution by presenting the advantages and disadvantages of space closure as well as the functional and esthetic limitations that accompany this treatment modality¹²⁻¹⁴.

When premolars occupy the canine positions, they should simulate esthetics and functions like canine. Canine-protected occlusion is not feasible when canine is replaced by a premolar. However, long-term periodontal and occlusal studies on congenitally missing lateral incisors have shown that space closure with premolars substituting canines was equally sound occlusally and preferable periodontally to orthodontic space opening with prosthetic replacement of missing lateral incisor¹⁵. The premolar roots were torqued buccally to simulate canine prominence. The palatal cusp was selectively reduced at each visit throughout the

treatment to provide smooth palatal surface for canine guidance.

The treatment plan for this patient addressed the problem of missing central incisor, which was replaced by adjacent teeth filling the edentulous space. All treatment objectives were satisfied and the patient was pleased with the end result.

Conclusion

There are several treatment options available for the replacement of missing anterior tooth, including canine substitution following orthodontic space closure, single-tooth implants and tooth-supported restorations. A team approach combining carefully performed orthodontic space closure and esthetic remodelling and restoration on substituted teeth will make it successful to treat patients with missing anterior tooth. The interdisciplinary approach can achieve not only an optimum occlusion, but also a well-balanced natural smile that will be stable over the long term.

References

1. Kinzer GA, Kokich VO. Managing congenitally missing lateral incisors. Part 1: canine substitution. *J Esthet Restor Dent* 2005; 17:5-10.
2. Kinzer GA, Kokich VO. Managing congenitally missing lateral incisors. Part II: tooth-supported restorations. *J Esthet Restor Dent* 2005; 17:76-84.
3. Kinzer GA, Kokich VO. Managing congenitally missing lateral incisors. Part III: single-tooth implants. *J Esthet Restor Dent* 2005; 17:202-10.
4. Kokich VG, Spear FM. Guidelines for managing the orthodontic-restorative patients. *Semin orthod* 1997; 3:3-20.
5. Thilander B, Odman J, Lekholm U. Orthodontic aspects of use of oral implants in adolescents:a 10-year follow-up study. *Eur J Orthod* 2001; 23:715-31.
6. Bernard JP, Schatz JP, Christou P, Belser U, Kiliaridis S. Long-term vertical changes of the anterior maxillary teeth adjacent to single implants in young and mature adults. A retrospective study. *J Clin Periodontol* 2004; 31:1024-8.
7. Rosa M, Zachrisson BU. Integrating esthetic dentistry and space closure for missing maxillary lateral incisors. *J Clin Orthod* 2001; 35:221-34.
8. Rosa M, Zachrisson BU. Integrating esthetic dentistry and space closure for missing maxillary lateral incisors:further improvements. *J Clin Orthod* 2007; 41:563-73.
9. Fink DF, Smith RJ. The duration of orthodontic treatment. *Am J Orthod Dentofacial Orthop* 1992; 102:45-51.
10. Rosa M, Zachrisson BU. Space-closure alternative for missing maxillary lateral incisors: an update. *J Clin Orthod* 2010; 44:540-9.
11. Kokich VG, Nappen DL, Shapiro PA. Gingival contour and clinical crown length: their effect on esthetic appearance of maxillary anterior teeth. *Am J Orthod* 1984; 86:89-94.
12. Thordarson A, Zachrisson BU, Mjor IA. Remodeling of canines to the shape of lateral incisors by grinding: a long term clinical and radiographic evaluation. *Am J Orthod Dentofacial Orthop* 1991; 100:123-32.
13. Tuverson DL. Orthodontic treatment using canines in place of missing maxillary lateral incisors. *Am J Orthod* 1970; 58:109-27.
14. Senty EL. The maxillary cuspid and missing lateral incisor: esthetics and occlusion. *Angle Orthod* 1976; 46:365-71.
15. Nordquist GG, McNeill RW. Orthodontic vs. Restorative treatment of the congenitally absent

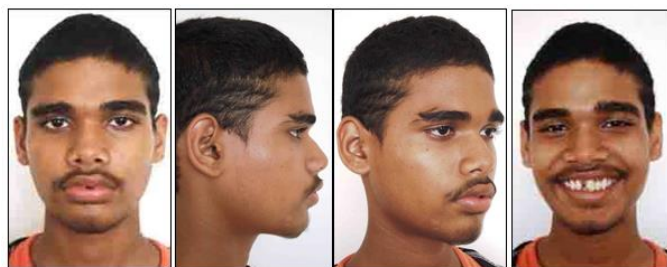lateral incisor long-term periodontal and occlusal evaluation. J Periodontol 1975; 46:139-43.

16. Spear FM, Kokich VG, Mathews DP. Interdisciplinary management of anterior esthetics. J Am Dent Assoc 2006; 137:160-69.
17. Steyn CL, du Preez RJ, Harris AMP. Differential premolar extractions. Am J Orthod Dentofacial Orthop 1997; 112:480-6.
18. Guilherme J, Eduardo AD, Jose FCH, Marcos FR, Karina JRS. Class II subdivision treatment success rate with symmetric and asymmetric extraction protocols. Am J Orthod Dentofacial Orthop 2003; 124:257-64.
19. Asl Aminabadi N, Erfanparast L, Sohrabi A, Ghertasi Oskouei S, Naghili A. The Impact of Virtual Reality Distraction on Pain and Anxiety during Dental Treatment in 4–6-Year-Old Children: a Randomized Controlled Clinical Trial. J Dent Res Dent Clin Dent Prospects. 2012 Fall;6(4):117-24.
20. Murphy, Nancy. (1997, May). A multisensory vs. Conventional approach to teaching spelling. Unpublished master's thesis, Kean College, New Jersey, USA. (Eric Document Reproduction Service No. ED 405 564)

Legends Tables and Figures

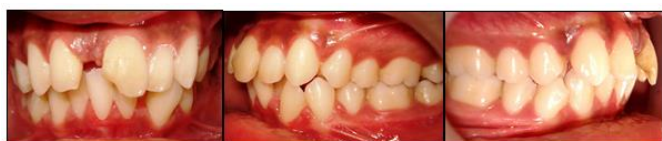Table 1

Parameters	Pre-treatment	Post-treatment
SN length (mm)	71.5	71.5
SN- FH	5 ⁰	4 ⁰
SNA	85 ⁰	84 ⁰
SNB	81 ⁰	81 ⁰
NB to Pg (mm)	+2.5	+2.5
ANB	4 ⁰	3 ⁰
Wits (mm)	+3	+3
Angle of convexity	7 ⁰	6 ⁰
FMA	25 ⁰	25 ⁰
SN – Go Gn	28 ⁰	28 ⁰
Jarabak's ratio	68.77%	68.90%
Mx OP to TVL	98 ⁰	98 ⁰
1 to NA (mm)	8	4
1 to NA (deg)	26 ⁰	20 ⁰
1 to SN	112 ⁰	103 ⁰
1 to TVL (mm)	-9	-12
1 to Mx OP (degree)	55 ⁰	60 ⁰
1 to NB (mm)	9.5	5.5
1 to NB (deg)	32 ⁰	25 ⁰
IMPA	101.5 ⁰	94 ⁰
1 to TVL (mm)	-14	-16
1 to Mn OP (degree)	53 ⁰	63 ⁰
Overjet	5	3
Overbite	5	3.5
Interincisal angle	116 ⁰	131 ⁰
Nasolabial angle	89 ⁰	99 ⁰
Upper lip angle	32 ⁰	21 ⁰
Mx 1 exposure	6	5
E line to Upper lip	+3.5	+2
E line to lower lip	+6.5	+3

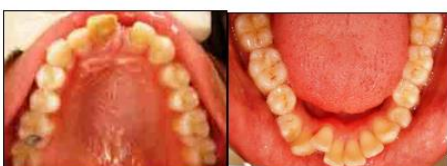

Frontal View Profile View Three-Quarter View Smiling View

Figure 1 A: Pre-treatment extra-oral photographs



Frontal View Left Lateral View Right lateral View



Maxillary Occlusal View Mandibular Occlusal View

Figure 1B: Pre-treatment Intra-oral photographs

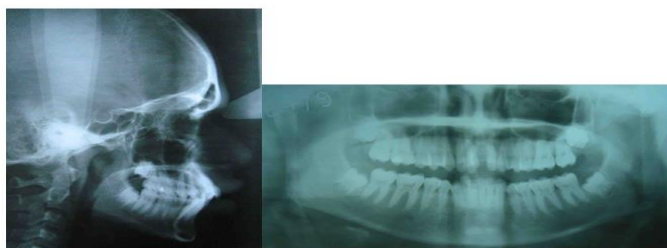
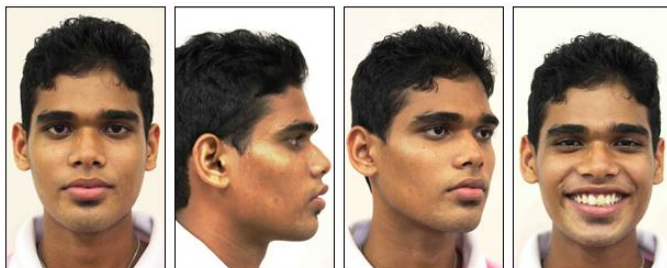
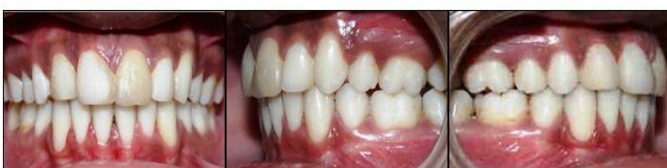
Figure 1C: Pre-Treatment Radiographs

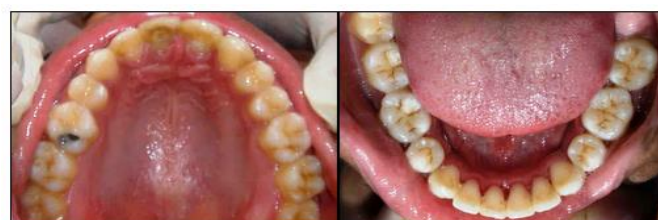

Frontal View Profile View Three-Quarter View Smiling View

Figure 2A: post-treatment extra-oral photographs



Frontal View Left Lateral View Right lateral View



Maxillary Occlusal View

Mandibular Occlusal View

Figure 2 B: Post treatment Intra-oral photographs

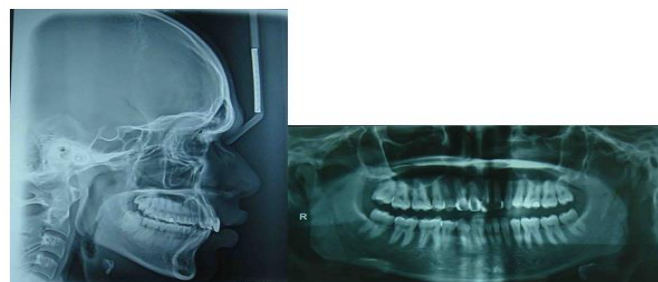
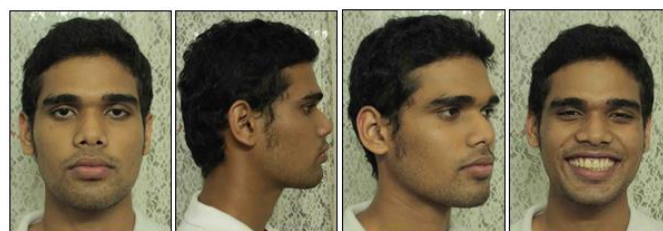
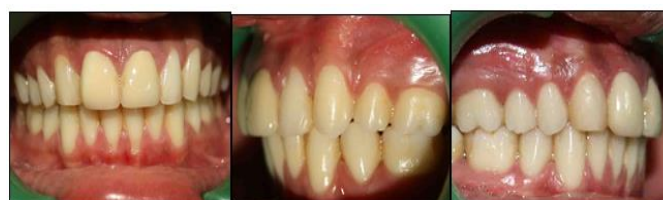
Figure 2 C: Post Treatment Radiographs



Frontal View Profile View Three-Quarter View Smiling View

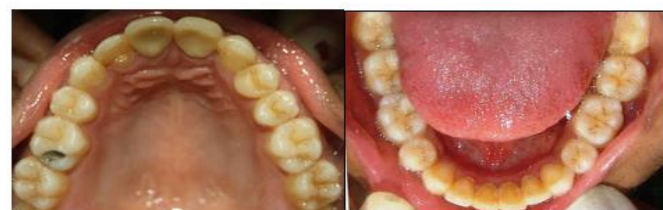Figure 3A; One-year post-treatment extra-oral photographs



Frontal View

Left Lateral View

Right lateral



Maxillary Occlusal View

Mandibular Occlusal View

Figure 3B: One year Post treatment Intra-oral photographs

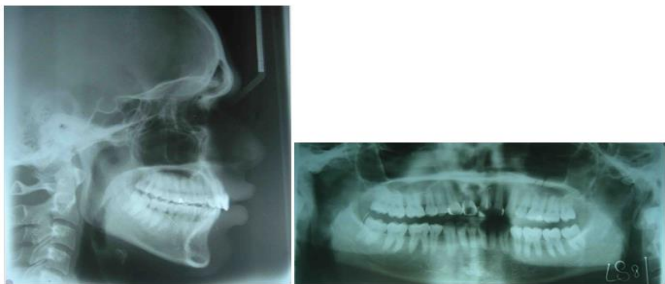

Figure 3 C: One year Post Treatment Radiographs