

Cleft palate.

¹Dr. Priya Yadav, MDS, OMFS, Department of Oral and Maxillofacial Surgery, District Hospital, Sagar, 470001 - M.P.

²Dr. Shaji Thomas, MDS, OMFS, FIBOMS, Professor and head of department, Department of Oral and Maxillofacial Surgery, People's College of Dental Sciences & Research Centre, Bhopal. 462037 - M.P.

³Dr. Ashutosh Dutt Pathak, MDS, OMFS, Professor, Department of Oral and Maxillofacial Surgery, People's College of Dental Sciences & Research Centre, Bhopal, 462037 - M.P.

⁴Dr. Pooja Khokhar, MDS, OMFS, Department of Oral and Maxillofacial Surgery, Civil Hospital, Berasia, Bhopal. 463106 - M.P.

⁵Dr. Vertika Dubey, MDS, OMFS, Department of Oral and Maxillofacial Surgery, District Hospital, Bhopal. 462030 - M.P.

⁶Dr. Ayush Kharia, Post graduate trainee, MDS in Oral and Maxillofacial Surgery, People's College of Dental Sciences & Research Centre, Bhopal, 462037 - M.P.

Corresponding Author: Dr. Priya Yadav, MDS, OMFS, Department of Oral and Maxillofacial Surgery, District Hospital, Sagar, 470001 - M.P.

Citation of this Article: Dr. Priya Yadav, Dr. Shaji Thomas, Dr. Ashutosh Dutt Pathak, Dr. Pooja Khokhar, Dr. Vertika Dubey, Dr. Ayush Kharia, “Cleft palate”, IJDSIR- May - 2023, Volume – 6, Issue - 3, P. No. 119 – 129.

Copyright: © 2023, Dr. Priya Yadav, et al. This is an open access journal and article distributed under the terms of the creative common's attribution non-commercial License. Which allows others to remix, tweak, and build upon the work non-commercially, as long as appropriate credit is given and the new creations are licensed under the identical terms.

Type of Publication: Original Research Article

Conflicts of Interest: Nil

Abstract

Orofacial clefts, including cleft lip with or without cleft palate, are the second most common congenital birth defect in the U.S., with an incidence of 0.28 to 3.74 per 1000 live births globally. Cleft lip is more common in males, while cleft palate is more common in females. Orofacial clefts can have various causes, including genetic factors (single gene defects, chromosomal Aberrations), environmental factors (teratogens, infections, nutrient deficiencies), and unknown factors. The incidence of cleft lip and palate worldwide is approximately 1 in 500 - 1500 live births. There are

various surgical techniques for the management of cleft palate repair including alveolar grafting along with speech therapy, orthodontic treatment, orthognathic surgery and secondary surgical procedures.

Keywords: Cleft palate, orofacial cleft, congenital anomaly, crestal cells, Vander Woude syndrome

Introduction

Congenital anomalies can be defined as birth defects, congenital disorders or congenital malformations, structural or functional anomalies, including metabolic disorders, which are present at the time of birth.

Approximately 2-3% of live births have major congenital malformations.

Approximately 50% of all congenital anomalies are of unknown origin. There are some known causes or risk factors like socio - economic factors, genetic factors, various infections at the time of pregnancy, maternal nutritional status and environmental factors.¹

Orofacial clefts include a range of congenital deformities most commonly presenting as cleft lip with or without cleft palate (CLP) or isolated cleft palate (CP). CLP is the second most common congenital birth defect in the U.S. trailing only Down syndrome. The majority of the CL/P is non- syndromic (70%) and other are syndromic cases. The high familial aggregation rates, recurrence risks and elevated concordance rates in monozygotic twins provide evidence for a strong genetic component in CL/P.² No exact mechanism has been discovered for the cause of non-syndromic cleft, and the cause is believed to be multifactorial.

The most common syndrome associated with cleft lip and palate is Vander Woude syndrome.

Epidemiology

In India the incidence of cleft lip and palate was ranged from 0 to 1.90 per 1000 live birth. This incidence of cleft lip and palate is increasing. In the third of this century, the incidence was 1:1000 live birth where as in the last few decades, the incidence was increased to 1.5 to 2:1000 live birth. The racial gradient in the incidence of cleft palate is shown in Table 1.

Table 1: Incidence of cleft palate in different races.

Caucasian	1:500 to 1:600 live births
Africans	1:1055 live birth
Negroes	1:1170 live birth
Japanese	1:373 live birth
American-Indian	1:276 live birth

Indonesia	1:600 live birth
Chinese	1:1000 live birth
Indian	1.7:1000 live birth
Afghani	4.9:1000 live birth

Seasonal Variation

Charlton found higher incidence rate in March for isolated clefts of lip in Australia; but for all type of clefts, April and august were highest. Charlton found highest incidence of cleft in January in USA. But in Japan, lowest incidence was in the month of December to February and highest was in the month of March and May. However, exact cause is not known to explain such seasonal variation of cleft lip and palate.

Sex Differences

Carter and Woolf found a little higher rate of occurrence of clefts for females than males. For combined cleft lip and palate, males were more affected than females. For isolated cleft of palate, females were affected more than males. However, severity of the defect was more in males.^{3,4}

Embryology

The development of the face, lip and palate is best understood by embryology, developmental biology and molecular biology. Morphogenesis of the facial region depends heavily on the timely differentiation, directed migration, selective proliferation of these crest cells which arise as a product of neural tube formation as the neural tube progressively pinches off from the overlying skin along the body's dorsal axis. Crest cells from the developing midbrain region migrate into upper facial regions, whereas crest cells from hindbrain migrate selectively into the lower facial regions. Importantly, once the crest cells migrate into specific facial regions, they differentiate into mesenchymal cells that subsequently give rise to connective tissue and muscle cells of those specific facial regions.⁴

When the embryo's cephalo-caudal axis is established at about 14 post conception days, the facial developmental field is one of the first of the head regions to appear.

Cleft Formation

Disruptions at any stage of the developmental process can result in clefts of the lip and palate. The process is complex and requires many steps to form a complete lip and palate. Any disturbance in timing of a particular step can result in formation of a cleft. Obstructions can result in abnormal positioning of the developing palate, which can prevent proper fusion of the palate. Pierre Robin Sequence is an example of when positioning prevents closure of

the palate. The micrognathia does not allow the tongue to move inferiorly which prevents the palatal shelves from migrating into a more horizontal position for fusion resulting in a wide U-shaped palate. Failure of fusion of the maxillary and nasal prominences on one side result in cleft lip with or without primary palate and failure of fusion bilaterally results in bilateral cleft lip with or without primary palate. The failure of fusion of the palatal shelves will result in clefts of the secondary palate.⁷

Applied surgical anatomy

Important structures of the embryo's mouth form at four to seven weeks of gestation. Development during this period migration and fusion of mesenchymal cells with facial structures. If this migration and fusion is interrupted, a cleft can develop along the lip and palate. The type of cleft varies with the embryonic stage when its development occurred. Mainly abnormality of mesoderm is responsible for cleft to occur.⁶

Development of palate

The palate is formed with the fusion of primary palate (median palatine process) which is derived from the fronto nasal process and the secondary palate (lateral

palatine processes) which are derived from the maxillary prominences on both sides. All these three elements are initially widely separated because of the presence of tongue. During the 8th week, the orientation of the lateral palatine processes alters from vertical to horizontal to initiate their fusion.⁵ During this process the mandible becomes more prognathic, thereby allowing the tongue to move down to avoid any interference for fusion to occur. Fusion then occurs between the secondary palate and primary palate.⁸

Ossification occurs in the primary palate and the anterior portion of the secondary palate to form the hard palate, while the posterior portion of the secondary palate does not undergo ossification and remains as the soft palate. Cleft of either the primary or secondary palate can be complete or incomplete, depending on the degree of fusion that occurred during embryonic development.⁷

A cleft of the lip and palate is the result of the failure of lip elements, and right and left palatal segment, to come together within the first 9 weeks of fetal life. The loss of muscular continuity of the orbicularis, buccinator-superior constrictor leads to complete unilateral and bilateral clefts changes the normal muscular force. The aberrant muscular forces act to displace tissue masses.⁷⁻⁸ In complete unilateral clefts of the lip and palate, the premaxillary portion on cleft segment is pulled antero-laterally. In addition to the lateral displacement of the lateral palatal segments, the premaxilla in the larger segment is carried forward in the facial skeleton. Alveolar bone deficiencies can be seen related to abnormal tooth development or their absence, as growth of alveolar bone is based on tooth development. Nose is also deviated to the normal side because of muscle pull except the alar base of cleft side because of which nose appears to be depressed as shown in figure. If a soft tissue, which collectively form Simon art band, bridges

the alveolar cleft, the attached palatal segments are limited in their degree of geometric displacement.⁹ Poor feeding also leads to improper growth of the child. Otitis media is also a common problem with cleft palate patients as ventilation of ear is affected due to abnormal muscle attachment blockage of Eustachian tube and its pull which leads to accumulation of fluid in ear and leading to inflammation.¹⁰ Children have speech related difficulties as there is no closure of nasopharynx, (velopharyngeal incompetence) hence a nasal escape of air & having difficulty in phonation.

Etiology

Both environmental and genetic factors are implicated in the genesis of cleft lip and palate. Facial clefts can occur as part of a syndrome or as isolated clefts. Factors most commonly cause cleft are as follows.

Genetic factors.

Environmental factors.

Syndromic clefts.

Genetic factors

With respect to cleft lip and palate, lots of genetic studies were done. These studies help to understand the cause and pathogenesis of this deformation.

Findings of genetic linkage studies have suggested various loci genes could have a causal role in cleft lip and palate, including regions on chromosomes 1, 2, 4, 6, 14, 17, and 19 (MTHFR, TGFA, D4S175, F13A1, TGFB3, D17S250, and APOC2) with potential loci suggested at 2q32–q35 and 9q21–q33.

The gene IRF6, which has a causal association with Vander Woude's syndrome, is also linked strongly to the isolated form of clefting. This finding has been replicated in many different populations and ethnic groups.

Environmental factors

A relation between some environmental factors (smoking, alcohol, anticonvulsants, steroids, radiation, viral infections and mechanical factors) during pregnancy and risk of having baby with an orofacial cleft is well established. Maternal smoking during pregnancy doubles the incidence of cleft lip. In literature it is summarized that risk of cleft with maternal smoking is 1:29 for CLP and 1:32 for CP.¹¹ There is increased risk of both Syndromic and non-syndromic cleft with higher quantities of alcohol consumption.¹² Role of steroid as a risk factor is well demonstrated. Therapeutic doses of Prednisone do increase the risk of cleft by 3-4 times.¹³ Radiation exposure during pregnancy and viral infections also predisposes to cleft lip and palate. Mechanical factors are like attempt to abort the baby by uterine manipulation and hormonal therapy.

Intrauterine exposure to the anticonvulsant Phenytoin¹⁴, Valproic acid, Oxazolidine is associated with a 10-fold increase in the incidence of cleft lip.

The drug Methotrexate which is used as a chemotherapeutic agent is also said to be associated with increase in the risk of clefts.¹⁵ Deficiency of folic acid also causes cleft in human beings but the exact etiopathogenesis forth is still unclear, most accepted is there is role of folate in nucleic acids synthesis and methylation cycle.¹⁶

Syndromic clefts

The most common syndrome associated with cleft lip and palate is Vander Woude syndrome with or without lower lip pits or blind sinuses. Micro deletions of chromosome 22-q resulting in velo cardio-facial Syndrome is the most common diagnoses associated with isolated cleft palate with congenital heart diseases, hyper nasal speech and learning disabilities.¹⁵

Management

The timing of cleft palate repair is controversial. Despite several meaningful advancements in the care of patients with cleft palate, a lack of consensus exists regarding the timing and surgical technique used during each stage of cleft reconstruction. Timing of surgery depends on the balance between functional needs, aesthetic concerns, and the issue of ongoing growth of the child. Due to many different treatment philosophies, the timing of treatment interventions is considerably variable amongst cleft centers. Therefore, it is difficult to produce a timing regimen that everyone agrees upon.

Table 2: Staged reconstruction of cleft palate deformities

Sn.	Procedure	Timing mentioned in the literature
1.	CP repair	9-18 months
2.	Pharyngeal flap/Pharyngoplasty	3-5 years or later based on speech Development
3.	Alveolar reconstruction With bone graft	6-9 years based on dental development.
4.	Cleft Orthognathic Surgery	14-16 years in girls, 16-18 years in boys.
5.	Cleft Rhinoplasty	After age of 18 years but preferably at skeletal maturity; after orthognathic surgery when possible.

Pre surgical evaluation

Before the patient undergoes surgical intervention a pre surgical evaluation of the patient is mandatory regarding fitness for surgery by paediatrician, physician and the anaesthetist. Routine haematological investigations are required including (complete blood count serum profiles, sickling, blood grouping, hepatitis B).¹⁷ According to Rule of Ten, patient must have at least 10 gm% of

hemoglobin, blood grouping is must if any trans fusion to be done during surgery or immediately after surgery for which cross matched blood should be ready before surgery.

Management protocols for the patients with cleft palate.

- Genetic counselling
- Feeding of child with cleft palate
- Naso alveolar molding
- Cleft palate repair
- Alveolar bone grafting
- Speech therapy
- Orthodontic treatment
- Orthognathic surgery
- Secondary surgical procedures

The child must be feed in sitting up position, and frequent burping is required as child is prone to engulf air also with the feed (aerophagia). As a result cleft children get fatigued early. Such patients require frequent small amount of feedings otherwise child may become undernourished. If the child cannot feed with this method, a palatal prosthesis which bridges the defect maybe required. These kind of prosthesis helps in feeding as well as act as Naso alveolar moulding (NAM) preoperatively to decrease the size of the cleft. Despite these attempts, more than 25% of cleft palate children have feeding difficulties with poor weight gain until palatal repair.¹⁸

Cleft palate repair

The surgical techniques of cleft palate repair which are presently practiced by different surgeons in various centres are below mentioned.¹⁹ There are many variations of each of these techniques. However, only a few of them which are most relevant and useful, are being presented.

- Von Langenbeck's bipedicle flap technique
- Veau-Wardill-Kilner Push back technique
- Bardach's two-flap technique
- Furlow Double opposing Z-Plasty
- Two- stage palatal repair
- Hole in one repair
- Raw area free palatoplasty
- Alveolar extension palatoplasty (AEP)
- Primary pharyngeal flap
- Intra velar velo plasty
- Vomer flap
- Buccal myo mucosal flap

Von Langen beck technique

In 1861, Bernard von Langenbeck described a method of uranoplasty (palatoplasty) using mucoperiosteal flaps for the repair of the hard palate region. He advocated that the anterior attachment of the mucoperiosteal flap should be maintained to the alveolar margin to make it a bipedicle flap.

Originally only the cleft edges were incised, a lateral incision was made, the flap was elevated from the hard palate, the palatine musculature was divided and finally the sutures were applied.

This technique is still used in isolated cleft palate repair. The muscle dissection and muscle suturing are done as additional procedures to create a muscle sling.

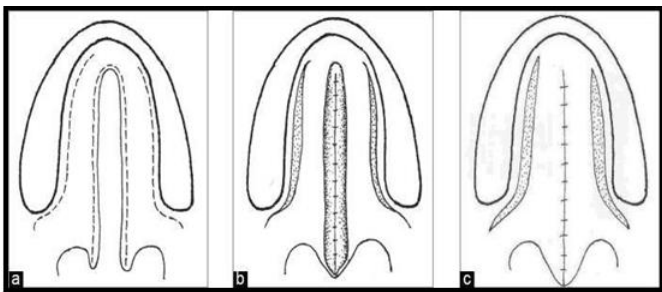


Fig 1: Line diagram of von Langenbeck palato plasty for an isolated complete cleft palate

Veau-Wardill-Kilner Palatoplasty

Till few years back this procedure was the commonest technique of palatoplasty. In this technique V-Y procedure is performed so that the whole muco periosteal flap and the soft palate are retroposed and the palate is lengthened. However, it leaves an extensive raw area anteriorly and laterally along the alveolar margin with exposed bare membranous bone. The raw area heals with secondary intention. This causes shortening of the palate and results in velopharyngeal incompetence. The raw area adjacent to the alveolar marginal so results in alveolar arch deformity and dental mal alignment.

To increase the length of the soft palate, George Dorrance advocated horizontal back-cut in the nasal lining at the junction of hard and soft palate. This leaves a large raw area on the nasal surface which is left open. This may contract after healing with secondary intention and may undo the palatal lengthening. Since there is single-layer repair in the region of the back- cut, the incidence of palatal fistula is high. Because of these drawbacks push back and V-Y techniques have fallen into disrepute and now less and less centres practice this technique.

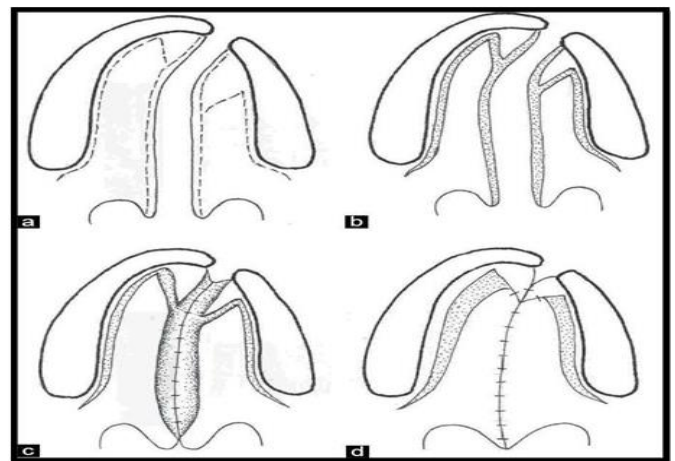


Fig 2: The Veau-Wardill-Kilner technique of palate repair in a unilateral Cleft lip and palate.

Bardach Two-flap Palatoplasty

This is a modification of the von Langenbeck technique in which the incision is made along the cleft margin and

the alveolar margin. These are joined anteriorly to free the mucoperiosteal flaps. These flaps are based on the greater palatine vessels. The soft plate is repaired in a straight line. The levator palate muscle dissection and reconstruction of the muscle sling is performed as in intravelarveloplasty.

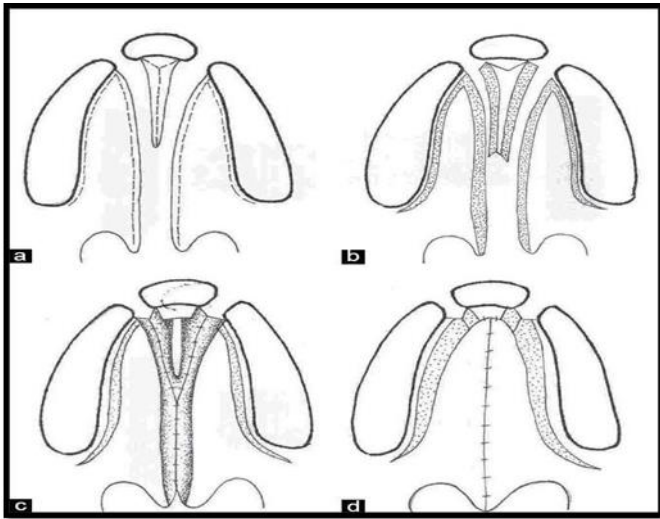


Fig 3: Line diagram showing Bardach two-flap technique of palatoplasty in a bilateral cleft lip and palate

Furrow Double Opposing Z-Plasty

Furrow adopted a double reverse Z-plasty for the oral and nasal surfaces of the soft palate. The cleft margin forms the central limb. The muscle is incorporated into the posteriorly based triangular flap on the left side for ease of dissection.

The hard palate region is closed by making an incision along the cleft margin, elevating the mucoperiosteum from the medial side and taking advantage of the high arch, the cleft is closed in two layers without making a lateral incision. Furrow described the use of the lateral relaxing incision only when necessary.

On transposition of the triangles there is an effective lengthening of the soft palate, the suture line is horizontal and there is good overlap of the levator muscle. Many surgeons claim to have better

speech outcome with Furrow repair technique. However, the studies have not proved this objectively. The major objection to the technique is the non-anatomic placement of the muscle.

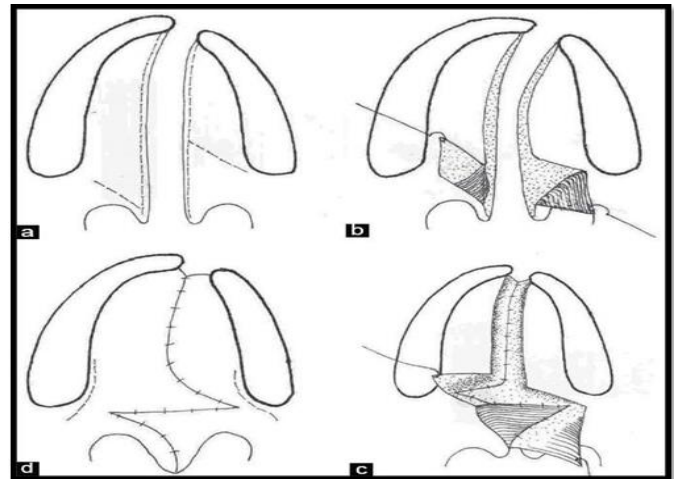


Fig 4: Line diagram showing Furrow Z-plasty technique of palatoplasty in a unilateral cleft lip and palate patient

Two-stage Palatoplasty

It is a well-established fact that un repaired cleft patients have better maxillary relationship and development. Early palatal surgical intervention causes maxillary hypoplasia. Because of this reason many surgeons used to perform palate repair in two stages. The soft palate was repaired early and later the hard palate was repaired. At the time of introduction of this protocol the soft palate was repaired along with the lip at around four to six months of age and the hard palate was repaired at the age of 10-12 years. This was later reduced to four to five years. This delay significantly reduced the cleft width in the hard palate region and was easy to close without the need for extensive dissection. This reduced the maxillary hypoplasia significantly. However, the speech result was compromised. Hence this technique fell into disrepute. Delaire introduced two-stage functional palatoplasty. A method of cleft palate repair is described, based on a functional repair of the soft palate, followed by closure of the hard palate later taking into account the anatomy and physiology of the palatal mucosa.

Hole in one repair (One-stage cleft lip and palate repair)

In developing countries repeated hospitalization is a drawback for independent surgery for cleft lip and cleft palate. To avoid this, some of the surgeons popularized a one-stage repair of the full extent of the cleft. This is performed in children above 10 months of age. The surgeons claim extremely good results without any complications. This is a good procedure and has gained popularity in our country. This term 'holeinone' is borrowed from the Game of Golf and popularized by Prof. K.S. Goleria

Raw area free palatoplasty

This technique is exactly like the two-flap palatoplasty. Here the palatal lengthening is performed by the nasal mucosa back-cut, however, the raw area is covered with a local flap like the vomer flap or the buccal mucosal flap. On the oral side too an attempt is made to suture all the lateral incisions. This way no raw area is left on either surface. Healing of the palate occurs with primary intention, hence secondary deformities and shortening of the palate is less likely to occur.

Alveolar Extension Palatoplasty

Michael Carsten recently described alveolar extension palatoplasty (AEP) technique for palatoplasty. In this technique the entire lingual gingiva periosteal tissue is incorporated into the mucoperiosteal flap. This is expected to lengthen and widen the flap to cover the larger defect. Carsten claims that this procedure is more favourable to angiosomes. This is expected to reduce the maxillary hypoplasia.

Primary Pharyngeal Flap

To improve the speech in children with cleft palate, primary pharyngeal flap pharyngoplasty is performed in a few centres. Since the majority of these patients will not develop velopharyngeal incompetence after classical

palatoplasty, this procedure seems to be an overkill. This creates an abnormal anatomy in all the cleft palate patients, which is not acceptable to most surgeons. This procedure is not popular presently, as it unnecessarily subjects the patients to the disadvantages of pharyngeal flap surgery like sleep apnea, hypo nasality etc.

Intravelar Veloplasty

In 1968 Braithwaite first described the dissection of the Levator Palati from the posterior border of the hard palate, nasal and oral mucosa and posterior repositioning.

He described independent suturing of the muscle with that of the opposite side for there construction of the Levator sling. Since then intravelar velo plasty has evolved considerably and many surgeons have modified the surgical details to achieve better anatomical muscle sling reconstruction. Sommer lad advocates radical muscle dissection under a microscope. Sommer lad dissects the levator palate belly separately and sutures independently as the levator is the dominant muscle for elevation of the soft palate during speech. Court Cutting transects the Tensor Palati and to keep its function intact, the cut end is transfixed with the hook of the hamulus.

During various meetings the discussion on "how much muscle dissection is optimum" remains inconclusive. The majority of the surgeons dissect the muscle but the extent varies. Probably, the end result remains the same.

Vomer flap

Vomerine mucoperiosteal tissue is very versatile. Most of the surgeons utilize the vomer flap only for repair of the cleft anteriorly in the hard palate region and the alveolar region. The vomer flap in this region is invariably used as a superiorly based turn over flap. This tissue has been revisited and has been extensively used for covering palatal defects. Many varieties of vomer flaps have been described for use in unilateral and

bilateral cleft palates for nasal lining and oral mucos are surfacing.

Buccal Myomucosal flap

The raw area left over the nasal surface after pushback has always been a matter of concern. Buccal myomucosal flap was used by Mukherjee MM, 1969 to take care of this raw area created after push back surgery after Veau-Wardill palatoplasty. He had also used bilateral buccal mucosal flaps simultaneously for covering the oral and nasal surfaces. This technique has been recently popularized by Jackson for covering the defect created after back-cut at the junction between hard and soft palate.

Alveolar bone grafting

Need for procedure

Merely joining soft tissue flaps over the bony defect through lip and palate surgery does not result in formation of bone to unite separate segments. Any abnormality or disruption of overlying soft tissues, adjacent skeletal elements and developing teeth is likely to influence growth and development of the premaxilla.

Primary bone grafting

Indication for primary bone grafting was- elimination of bone deficiency, stabilization of the pre-maxilla, creation of new bone matrix for eruption of teeth in the cleft area and augmentation of the alar base. There were also expectations of normalization or even stimulation of maxillary growth.²⁰

Secondary bone grafting

Secondary bone grafting, meaning bone grafting in the mixed dentition, became an established procedure after abandoning primary bone grafting. The pre-requisites were: precise timing, operating technique, and sufficiently vascularized soft tissue. The advantages of primary bone grafting allowing tooth eruption through the grafted bone could also be maintained.

Furthermore, secondary bone grafting can stabilize the dental maxillary arch, improving the conditions for prosthodontic treatment such as crowns, bridges and implants.

It will also facilitate eruption of teeth increasing the amount of bony tissue on the alveolar crest allowing orthodontic treatment. Management of cleft-related velopharyngeal insufficiency.

Once the diagnosis of VPI has been made, treatment may consist of non-surgical speech therapy, obturation with a speech bulb, placement of a palatal lift, or reconstructive surgery of the airway. Mild VPI may be treated successfully with speech therapy alone, but more significant VPI usually requires surgical management of the palate.

Conclusion

Cleft affecting the palate are a relatively common group of developmental anomalies that occurs in human population. They are seen in isolation or in combination with more widespread developmental disease, and can contribute towards significant morbidity for affected individuals, particularly in their formative years, which inevitably has an impact throughout their lifetime.

Cleft palate repair is a cosmetic and functional corrective treatment done in various time periods of the growth and development of child which also aids in psychological well-being of the both patient and parent.

There are various management protocols followed in different parts of the world which differ by patient management approaches, surgical and non-surgical techniques, materials used and timing of surgery. It also depends upon the severity of the defect, needs of the patient, socio-economic status, locality and physical and mental health of the patient. In this dissertation it has been overviewed about various surgical protocols and techniques used in the management of patients with cleft

palate and management protocols followed in various cleft centres in different parts of the world.

References

1. Gustavson KH, Hagberg B, Finley SC, Finley WH. An apparently identical extra autosome in two severely retarded sisters with multiple malformations. *Cyto genetic and Genome Research*. 1962;1(1):32-41.
2. Stanier P, Moore GE. Genetics of cleft lip and palate: syndromic genes contribute to the incidence of non-syndromic clefts. *Human molecular genetics*. 2004 Apr 1;13(suppl_1): R73-81.
3. Rajendran R. Shafer's textbook of oral pathology. Elsevier India; 2009.p.16-17.
4. Thompson JE. An artistic and mathematically accurate method of repairing the defect in cases of harelip. *Transactions of the Southern Surgical and Gynecological Association*. 1912; 24:367.
5. Mestre JC, DeJesus J, Subtelny JD. Unoperated oral clefts at maturation. *The Angle Orthodontist*. 1960 Apr;30(2):78-85.
6. Cosman B, Falk AS. Delayed hard palate repair and speech deficiencies: a cautionary report. *The Cleft Palate Journal*. 1980 Jan 1;17(1):27-33.
7. Shah CP, Wong D. Management of children with cleft lip and palate. *Canadian Medical Association Journal*. 1980 Jan 12;122(1):19.
8. Vargervik K. Orthodontic management of unilateral cleft lip and palate. *The Cleft Palate Journal*. 1981 Oct 1;18(4):256-70.
9. Hayward JR. Management of the premaxilla in bilateral clefts. *Journal of oral and maxillofacial surgery*. 1983 Aug 1;41(8):518-24.
10. Warren DW. Compensatory speech behaviours in individuals with cleft palate: a regulation/control phenomenon? *The Cleft Palate Journal*. 1986 Oct 1; 23 (4): 251-60.
11. Peterson-Falzone SJ. The relationship between timing of cleft palate surgery and speech outcome: what have we learned, and where do we stand in the 1990s?. In *Seminars in orthodontics* 1996 Sep 1 (Vol. 2, No. 3, pp. 185-191).
12. Posnick JC. Orthognathic surgery for the cleft lip and palate patient. In *Seminars in Orthodontics* 1996 Sep 1 (Vol. 2, No. 3, pp. 205-214). WB Saunders.
13. Millard Jr DR, Morovic CG. Primary unilateral cleft nose correction: a 10-year follow-up. *Plastic and reconstructive surgery*. 1998 Oct 1;102(5):1331-8.
14. Grayson BH, Santiago PE, Brecht LE, Cutting CB. Presurgical Naso alveolar molding in infants with cleft lip and palate. *The cleft palate-Craniofacial journal*. 1999 Nov;36(6):486-98.
15. Bhateja A, Kharbanda OP, Duggal R, Deka RC, Prakash H. Evaluation of surgical protocol and treatment need of operated unilateral cleft lip and palate patients in Delhi. *J Indian Soc Pedod Prev Dent*. 2001; 19:10-7.
16. Ahn JH, Kang WS, Kim JH, Koh KS, Yoon TH. Clinical manifestation and risk factors of children with cleft palate receiving repeated ventilating tube insertions for treatment of recurrent otitis media with effusion. *Acta oto-laryngologica*. 2012 Jul 1;132(7):702-7.
17. Rocha R, Ritter DE, Locks A, de Paula LK, Santana RM. Ideal treatment protocol for cleft lip and palate patient from mixed to permanent dentition. *American Journal of Orthodontics and Dentofacial Orthopedics*. 2012 Apr 1;141(4): S140-8.
18. Mukherji MM. Cheek flap for short palates. *The Cleft Palate Journal*. 1969 Sep 30;6(4):415-20.
19. Abeleira MT, Pazos E, Ramos I, Outumuro M, Limeres J, Seoane-Romero J, Diniz M, Diz P. Orthodontic treatment for disabled children: a survey of parents' attitudes and overall satisfaction. *BMC Oral Health*. 2014 Dec;14(1):1-8.

20. Singh K, Kumar D, Singh K, Singh J. Positive outcomes of Naso alveolar moulding in bilateral cleft lip and palate patient. National journal of maxillofacial surgery. 2013 Jan;4(1):123.