

**Comparative evaluation of soft and hard tissue changes of immediate and delayed loading of implants**

<sup>1</sup>Dr. D. Samyuktha, MDS, Prosthodontics, Department of Prosthodontics and Crown and Bridge and Oral Implantology, Sibar Institute of Dental Sciences, Takkellapadu, Guntur, Andhra Pradesh, India.

<sup>2</sup>Dr. T. Krishna Mohan, MDS, Professor, Department of Prosthodontics and Crown and Bridge and Oral Implantology, Sibar Institute of Dental Sciences, Takkellapadu, Guntur, Andhra Pradesh, India.

<sup>3</sup>Dr. Gade Phani Krishna, MDS, Professor, Department of Prosthodontics and Crown and Bridge and Oral Implantology, Sibar Institute of Dental Sciences, Takkellapadu, Guntur, Andhra Pradesh, India.

<sup>4</sup>Dr. K. Ramya Krishna, MDS, Senior Lecturer, Department of Prosthodontics and Crown and Bridge and Oral Implantology, Sibar Institute of Dental Sciences, Takkellapadu, Guntur, Andhra Pradesh, India.

<sup>5</sup>Dr. Prasanthi, MDS, Senior Lecturer, Department of Prosthodontics and Crown and Bridge and Oral Implantology, Sibar Institute of Dental Sciences, Takkellapadu, Guntur, Andhra Pradesh, India.

<sup>6</sup>Dr. P. Naga Sai Aneesha, MDS, Prosthodontics, Department of Prosthodontics and Crown and Bridge and Oral Implantology, Sibar Institute of Dental Sciences, Takkellapadu, Guntur, Andhra Pradesh, India.

**Corresponding Author:** Dr. D. Samyuktha, MDS, Prosthodontics, Department of Prosthodontics and Crown and Bridge and Oral Implantology, Sibar Institute of Dental Sciences, Takkellapadu, Guntur, Andhra Pradesh, India.

**Citation of this Article:** Dr. D. Samyuktha, Dr. T. Krishna Mohan, Dr. Gade Phani Krishna, Dr. K. Ramya Krishna, Dr. Prasanthi, Dr. P. Naga Sai Aneesha, “Comparative evaluation of soft and hard tissue changes of immediate and delayed loading of implants”, IJDSIR- May - 2023, Volume – 6, Issue - 3, P. No. 281 – 291.

**Copyright:** © 2023, Dr. D. Samyuktha, et al. This is an open access journal and article distributed under the terms of the creative common’s attribution non-commercial License. Which allows others to remix, tweak, and build upon the work non-commercially, as long as appropriate credit is given and the new creations are licensed under the identical terms.

**Type of Publication:** Original Research Article

**Conflicts of Interest:** Nil

**Abstract**

**Aim and Objectives:** The study aims to evaluate the soft and hard tissue changes between immediate loading and delayed loading of implants. The objectives of the study are to evaluate and compare the implant stability, crestal bone loss, presence and absence of bleeding on probing and mucosal thickness between immediately and delayed loading of implants.

**Materials and Methods:** The study was conducted in 20 patients, which were divided into two groups (Group

A and Group B) based on the insertion torque values. In Group A (10), implants were loaded using immediate loading protocol and Group B implants were loaded using delayed loading protocol. For both the groups, primary stability was measured by using resonance frequency analysis with Oss tell device and crestal bone loss was measured by using IOPA with grid at baseline, three months, and 6 months after implant placement. The associated soft tissue changes such as bleeding on probing and mucosal thickness was

evaluated by using the pressure-sensitive probe and endodontic file no.20 respectively at baseline, 3 months and 6 months of time interval.

**Results:** The mean ISQ values for implants loaded using immediate loading protocol is  $71.95 \pm 3.13$  and for implants loaded using delayed loading protocol is  $71.9 \pm 2.99$ . Overall, the bone loss for implants loaded using immediate loading protocol is  $0.84 \pm 0.25$  and for the group followed delayed loading protocol, the mean value is  $0.74 \pm 0.21$  at the end of six months. Mucosal thickness and bleeding on probing did not show much significant difference.

**Summary and Conclusion:** Within the limitations of the study, primary stability was comparable in both the loading protocols, however, secondary stability was comparatively higher for immediately loaded implants. Whereas, the crestal bone loss was lesser for implants loaded using delayed loading protocol than those with immediately loaded. The mucosal thickness and bleeding on probing did not show much difference between the two protocols. Though, there were differences between both the groups they were not statistically significant indicating that the immediate loading protocol is equally beneficial for restoration of missing tooth.

**Keywords:** Bleeding on probing, Crestal bone loss, Delayed loading, Immediate loading, Implant stability, Mucosal thickness,

## Introduction

Prosthodontists face the challenge of rebuilding lost structures in the oral and maxillofacial region using prosthetics.

Over time, implants have replaced traditional tooth replacement methods. Dental implants are essential for replacing a single tooth, particularly when preserving the adjacent healthy teeth is desired.<sup>1</sup>

Dental implants function as artificial roots in the jaw bones, providing mechanical support for fixed and removable dentures without harming natural teeth. Dental implantology is a highly sought - after treatment for edentulous conditions, offering established mechanical stability and earning the nickname "third dentition" due to its numerous benefits.<sup>2</sup>

Implant dentistry requires a direct bone-to-implant interaction, achieved through a strict surgical and prosthodontic regimen. Previously, Osseo - integrated dental implants were placed using a two - stage protocol, requiring a waiting period of 3-4 months in the mandible and 6-8 months in the maxillae for healing before fitting the prostheses.

However, advancements in implant technology have prompted a re-evaluation of the traditional protocol, leading to increased interest in different loading protocols.<sup>3</sup>

Loading protocols described in literature include Brånemark's, progressive, early and delayed, and immediate loading protocols. Factors influencing the choice of loading include time (dependent on bone density), patient's diet and chewing forces, occlusal material type, establishment of occlusal contacts, and prosthesis design. Implant treatment traditionally required a stress-free recovery period of three to six months, causing delays. However, an increasing number of articles advocate immediate loading (Chiapasco et al. 1997; Schnitman et al. 1997; Tarnow et al. 1997) due to its ability to stimulate bone and prevent crestal bone loss.<sup>1</sup>

Clinical studies have demonstrated positive outcomes with immediate or short-term loading, leading to its popularity among dental professionals. This approach enables combining surgical and prosthetic procedures in a single appointment, resulting in advancements in implant designs and treatment protocols.<sup>4</sup>

Factors such as durability, bone loss, gingival health, pocket depth, impact on neighboring teeth, function, esthetics, infection presence, comfort, mandibular canal intrusion, patient's emotional and psychological attitude, and satisfaction determine the long-term success of a dental implant. The type of loading can influence one or more of these parameters.<sup>4</sup>

Hence, the aim of the present study was to assess the effect of immediate and delayed loading protocols on implant stability, hard tissue and soft tissue changes. Parameters taken into consideration were implant stability, assessment of crestal bone loss, mucosal thickness, and bleeding on probing.

### **Aims and objectives**

#### **Aim**

The aim of this study is to compare the soft and hard tissue changes between implants that are loaded immediately and those that are loaded later.

#### **Objectives**

- To evaluate and compare the implant stability between immediate and delayed loading of implants.
- To evaluate and compare the crestal bone loss between immediate and delayed loading of implants.
- To evaluate and compare presence and absence of bleeding on probing between immediate and delayed loading of implants.
- To evaluate and compare the mucosal thickness between immediate and delayed loading of implants.

### **Materials and methodology**

20 partially edentulous patients who reported to the Department of Prosthodontics, SIBAR Institute of Dental Sciences, Guntur were selected based on the inclusion and exclusion criteria. Based on the Insertion Torque Values (ITV) which are recorded after the implant placement, patients are divided into 2 groups A and B respectively. Group A (immediate loading)

includes patients with insertion torque values above 30 Ncm and patients below it are included under Group B (Delayed loading). Standardization was done with respect to the system and dimensions of the implant i.e., Adin Touareg- S Implant of 3.5mm diameter and 10mm length.

Thorough case history (medical and dental history) of the patients was taken to rule out any contraindications for implant surgery. Complete blood investigations were done for all the patients before the surgery. Informed consent was taken after explaining the procedure.

### **Inclusion criteria**

- Patients aged 20-60 years
- Patients with partial edentulism in the posterior region
- Patients with D2 bone density
- Individuals having sufficient bone height and width
- Individuals giving consent form

### **Exclusion criteria**

- Medically compromised patient.
- Severe bleeding disorders and Uncontrolled diabetes.
- Patients subjected to recent radiation therapy to the head and neck region
- Pregnancy or lactating women
- Smokers and alcoholics
- Habitual substance abuse
- Uncontrolled acute or chronic infections of the tooth.

### **Pre-surgical phase**

Diagnostic impressions were made using alginate impression material and were poured with Type III dental stone and the diagnostic casts (Fig. 1) were obtained.

A pre-operative CBCT (Fig. 2) was taken for all the patients to determine the amount of bone available for the implant placement i.e., the available length and width of bone. Patients were prescribed prophylactic antibiotics one day before the surgery.

### **Stent fabrication - (Fig. 3)**

Reference lines were drawn on the diagnostic cast to determine the position of the implant. A line (Line A) represents the Center of the crest of the ridge over the edentulous site extending from the central fossa of the tooth mesial and distal to the edentulous site. At the centre of the edentulous space, another line (Line B) was drawn perpendicular to line A extending from the buccal to the lingual aspect. The point of intersection of line A and line B is used to determine the implant position in relation to the edentulous ridge. An acrylic tooth was then placed in the edentulous region and wax up was done. A separating medium was applied to the cast and auto-polymerising clear acrylic resin was used to fabricate the surgical stent. The above reference lines (line A and line B) were transferred from the diagnostic cast onto the stent. A 2 mm hole was drilled with no. 6-round tungsten carbide bur in the point of intersection which denotes the implant position and acts as a guide for the pilot drill.

### **Surgical phase**

After the patient is seated in the dental chair, the patient was instructed to rinse the mouth with 0.1% Chlorhexidine mouthwash for two minutes. The perioral mucosa was disinfected with Betadine solution and Local Anesthesia (2% lidocaine, 1:80,000 adrenaline) was administered based on the respective implant site. Before the incision in the surgical site, pre-surgical parameter evaluation of the mucosal thickness and bleeding on probing is done. Crestal and relieving incisions were given and a full-thickness mucoperiosteal flap was reflected. Then, the surgical stent was placed and a 2mm pilot drill was used to mark the implant site. The surgical stent then removed and parallelism was checked using paralleling pin. Once verified, sequential drilling was done under copious internal and external

irrigation of saline by using standard drills (2.8mm, 3.2mm) with the help of a Physio dispenser with a drilling speed of 800 – 2000 rpm. Angulation of the osteotomy drill was checked using a paralleling pin. After the desired osteotomy site preparation is achieved, preselected implants of length 10mm and a width of 3.5mm were threaded into the prepared site at a low speed of 25rpm with maximum torque of 50NCM till the implant is to the level of the alveolar crest.

Implant stability was measured using Resonance Frequency Analysis (RFA) with an Oss tell device by fitting the Oss tell smart peg to the implant. The machine gives implant stability quotient (ISQ) values between 0-100. Crestal bone loss was measured using periapical radio graphs along with an x-ray grid with paralleling technique and a ring holder. Mesial and distal crestal bone loss measurements were taken with the help of the grid.

Based on the Insertion Torque Values, the patients with ITV greater than 30Ncm were loaded following the immediate loading protocol (Group A), and those lesser than that value were loaded following the delayed loading protocol (Group B).

For Group A patients, an abutment is placed immediately after the implant placement along with an acrylic provisional crown without any occlusal contacts followed by suturing. After 1 week during the suture removal appointment, another provisional crown is given into full occlusion (Fig. 4). Whereas for Group B patients, cover screw (Fig.5) was placed followed by suturing and conventional prosthetic loading is followed after 3 months.

Medication was prescribed for all patients post-implant placement and was instructed to use Chlorhexidine mouthwash twice daily for 4 weeks and regular follow-up of the patient was done.

### **Evaluation of the clinical parameters**

The parameters such as implant stability, crestal bone loss, bleeding on probing, and mucosal thickness were measured at baseline, 3rd month, and 6th month for both the groups (bleeding on probing was not applicable at baseline).

#### **Mucosal thickness**

It was measured by using K-file no. 20 with a rubber stopper. The file is inserted at the midpoint of the attached gingiva between the mucogingival junction and an imaginary line from the adjacent tooth Cemento Enamel Junction (CEJ) to assess the mucosal thickness. The distance between the file tip and the rubber stopper will be recorded as mucosal thickness which is then measured using a digital caliper at baseline, 3rd, and 6th month.

#### **Bleeding on probing**

It was measured using a pressure-sensitive probe (0.5, 5.5, 8.5, 10.5 mm) at the 3rd, and 6th month post operatively. The probe is passed along the gingival sulcus with the force of 0.25N/cm and after 30 seconds the score of the bleeding index was recorded. The scoring criteria were adopted from the modified sulcular bleeding index given by Muhlemann and son as follows. Score 0- no bleeding, Score 1- pinpoint bleeding, Score 2- the thin linear rim of bleeding, and Score 3- profuse bleeding.

#### **Stability of implant**

Implant stability was measured using Resonance Frequency Analysis (RFA) with the Oss tell device by fitting the Oss tell smart peg to the implant.

#### **Crestal bone loss**

It was measured using standard IOPA with the help of a grid. The distance between the shoulder of the implant and alveolar crest (at the bone-implant contact point) was recorded at mesial and distal areas of implants

assessed at baseline, 3rd, and 6th months respectively. (Fig: 6)

### **Prosthodontic Protocol**

After 3 months for Group A, the provisional crown which was placed at the time of implant placement was removed and a final impression was made for the fabrication of the permanent crown.

Whereas for Group B, a cover screw was removed and replaced by a healing cap and left for 1 week for the contouring of the gingiva. Later, after 1 week the abutment was placed and a final impression was made for the fabrication of a permanent crown.

The final impression was made with elastomeric impression material using a stock tray. Transfer coping was placed in the impression, an implant analog was attached and the cast was poured over which screw-retained metal-ceramic crown was fabricated for both groups. The gauze was placed over the screw access hole and restored with glass ionomer cement.

The data obtained were analyzed using IBM SPSS version 20 software (IBM SPSS, IBM Corp., Armonk, NY, USA). Descriptive statistics and Shapiro-Wilk's tests for assessing normality were performed. Based on the results of normality tests ( $p > 0.05$ ), independent samples t-tests, repeated measures analyses of variance, chi-square tests, and Friedman's tests were done to analyze the study data.  $p \leq 0.05$  was considered statistically significant. Bar charts were used for data presentation.

### **Results**

Table 1 compares the primary stability (ISQ) of immediate (Group A) and delayed implants (Group B) at different time points. Although immediate implants had higher mean ISQ values, the differences between immediate and delayed implants were not statistically significant and Table 2 compares the crestal bone loss

(mm) between immediate and delayed implants at different time points. Immediate implants had slightly higher mean crestal bone loss, but the differences between the two groups were not statistically significant.

Table 3 compares bleeding on probing between immediate and delayed implants at different time points. At baseline, both groups had a score of 0. After 3 months, the immediate implants group had 80% with score 0 and 20% with score 1, while the delayed implants group had 70% with score 0, 20% with score 1, and 10% with score 2. However, these differences between the two groups were not statistically significant. and Table 4 compares the mucosal thickness (mm) between immediate and delayed implants at different time points. Immediate implants had slightly higher mean mucosal thickness, but the differences between the two groups were not statistically significant.

The study groups showed no significant differences in implant stability, crestal bone loss, bleeding on probing, or mucosal thickness at any of the time points considered. However, within each group, there was a significant increase in implant stability over time and a significant increase in crestal bone loss over time.

No significant changes in bleeding on probing were observed within either group. In terms of mucosal thickness, both study groups experienced a decrease from baseline to 3 months, followed by an increase from 3 months to 6 months.

## Discussion

Previous studies have developed criteria to assess the long-term success of dental implants, considering subjective, objective, and success-related factors.

Initially, success was determined by factors like implant mobility, peri-implant radiolucency, minimal bone loss, and absence of infection or discomfort. The criteria have expanded to include additional factors such as width of

attached gingiva, coexisting medical disorders, habits, and suture material. Various implant characteristics, including length, width, biomaterial, surface modifications, loading protocol, occlusion type, and prosthesis material, influence these factors. Loading protocols in implant dentistry include conventional, immediate, and early loading, with immediate loading gaining interest due to shorter treatment times and immediate restoration of function and aesthetics. These advancements have led to new implant designs and treatment protocols.<sup>5,6</sup>

The success of the immediate-loading protocol depends on various treatment planning and patient factors. Adequate bone density and dimensions, achieving primary stability (measured by Resonance Frequency Analysis), and an adequate anteroposterior spread are crucial.

Immediate loading offers advantages such as patient comfort, faster treatment, ideal soft tissue contour, immediate patient satisfaction, improved quality of life, and self-confidence.<sup>7</sup>

However, it requires increased skill, longer initial appointments, and carries the risk of implant bone loss or failure. Clinical studies have shown comparable results in terms of marginal bone loss and soft tissue reaction between immediate and conventional loading. Implant stability and absence of bleeding on probing are key factors for long-term success. Limited studies have compared immediate and delayed loading in terms of soft and hard tissue changes, prompting further research to evaluate stability, crestal bone loss, bleeding on probing, and mucosal thickness.<sup>8-12</sup>

This study included 20 patients of various ages and genders who had posterior partial edentulism. The inclusion criteria were based on bone density and consent forms. Pre-surgical evaluations were conducted, including radiographs and blood investigations. Surgical



stents were fabricated for clinical positioning of the implants. The surgery involved local anesthesia, incisions, and flap raising. A pre-made stent and pilot drill were used for verification. Sequential drilling prepared the osteotomy site, and a specific implant size was placed. Patients with certain values were grouped for immediate loading, while others received a cover screw. Suturing and medication followed the implant placement. After a week, sutures were removed, and parameters like implant stability, crestal bone loss, bleeding on probing, and mucosal thickness were examined at different follow-up intervals.

Primary stability of an implant is the mechanical interlocking between bone and the implant after placement. It is crucial for successful osseointegration, and factors such as bone quality, surgical technique, and implant design affect it. Implant stability can be measured using resonance frequency analysis (RFA), specifically the Implant Stability Quotient (ISQ) scale. High ISQ values indicate better primary stability. A study compared immediate and delayed implants, measuring ISQ values at baseline, 3 months, and 6 months. Immediate implants showed higher mean ISQ values, but the differences were not statistically significant. Primary stability plays a role in determining loading protocols for implants.<sup>13-16</sup>

Crestal bone level is an important factor in assessing implant prognosis. Measurements were taken using x-ray mesh with 1mm graduation on immediate and delayed implants at baseline, 3 months, and 6 months. While immediate implants showed slightly higher crestal bone loss, the differences were not statistically significant.

Contrary to our study, previous research suggested less bone loss with early loading compared to delayed loading. Another systematic review found no significant

difference in crestal bone loss between immediate and delayed implant loading. Immediate loading helps retain denser bone and reduces marginal bone loading, contributing to primary stability and minimal crestal bone loss. Another study observed crestal bone level changes of 0.84 for cylindrical implants and 0.73 for tapered implants after six months of loading.<sup>17,18</sup>

Mucosal thickness around implants plays a crucial role in maintaining gingival health and preventing Periodontal disease.

A study measured mucosal thickness using an endodontic file with a rubber stopper at baseline, 3 months, and 6 months. Adequate mucosal thickness, particularly 2mm with 1mm of keratinized and 1mm of attached mucosa, is associated with better peri-implant health. Insufficient attached mucosa can lead to plaque build-up, mucosal irritation, tissue recession, and implant failure. Thin soft tissues can affect aesthetics, color changes, and increase the risk of recession and marginal bone loss. Comparing immediate and delayed implants, there were slightly higher mean mucosal thickness values in immediate implants, but the differences were not statistically significant. Other studies have also found associations between mucosal thickness, gingival inflammation, plaque build-up, and bleeding on probing.<sup>19,20</sup>

Bleeding on probing was measured using a pressure-sensitive probe after three and six months of implant placement. The modified sulcular bleeding index was used to grade the bleeding. Comparing immediate and delayed implants, there were no statistically significant differences in bleeding on probing scores at baseline and 3 months. Another study found similar results, with no significant difference in bleeding on probing between immediate and delayed loading groups. Bleeding on probing can indicate inflammation and is associated with

implant failure. Intra-group comparison showed no significant change in bleeding on probing over time for both immediate and delayed implants. Immediate loading of implants has advantages in terms of patient comfort and function, and our study found that immediate loading showed a better prognosis and fewer signs of failure compared to delayed loading.<sup>21,22</sup>

#### Legend Tables & Figures

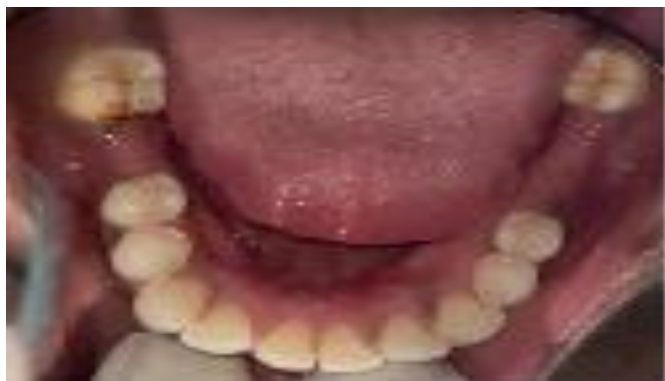

Fig 1: pre-operative photograph of the edentulous site

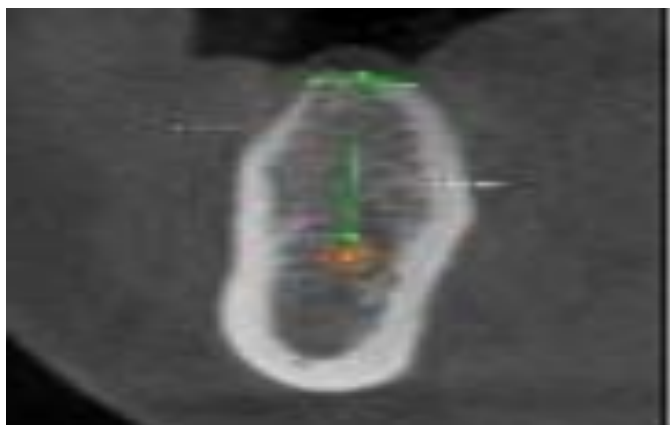


Fig 2: Pre-operative CBCT image



Fig 3: Diagnostic cast and Surgical Stent

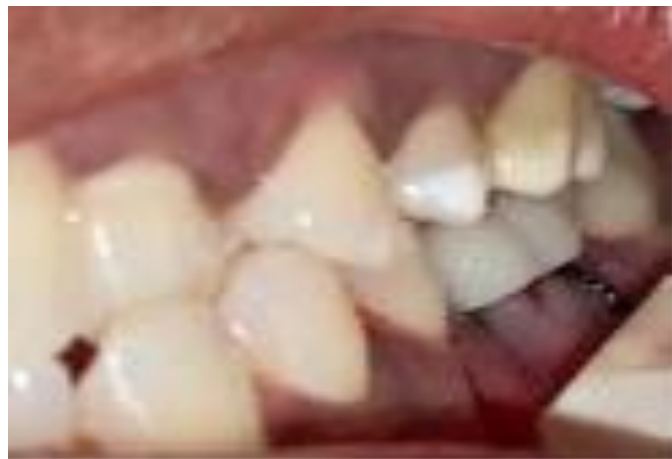

Fig 4: Provisional Restoration in occlusion

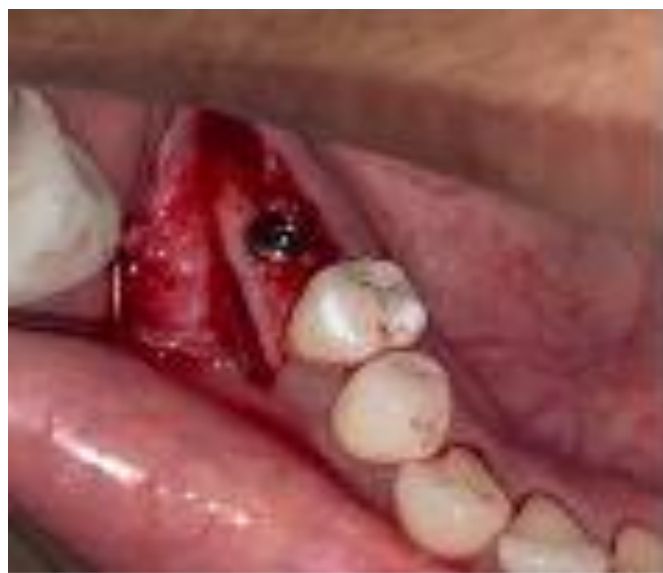

Fig 5: Cover screw tightened after implant placement

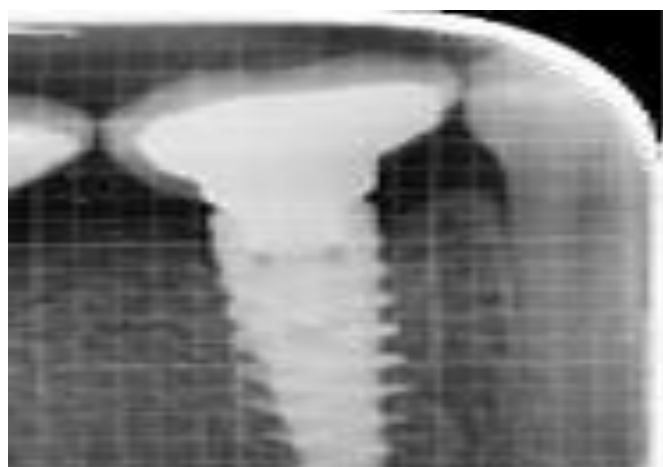

Fig 6: IOPAR with grid for crestal bone evaluation after 6 months



Table 1: Comparison of primary stability (ISQ) between the immediate and delayed implants at various time points.

Time point	Group	N	Mean	Std. Deviation	Std. Error Mean	t value	P value
Baseline	Immediate	10	68.100000	3.6575645	1.1566234	0.412	0.685
	Delayed	10	67.440000	3.5075157	1.1091739		
3 months	Immediate	10	70.050	3.0500	.9645	0.228	0.822
	Delayed	10	69.720	3.4149	1.0799		
6 months	Immediate	10	71.950	3.1398	.9929	0.036	0.971
	Delayed	10	71.900	2.9981	.9481		

Independent samples t test;  $p \leq 0.05$  considered statistically significant

Table 2: Comparison of crestal bone loss (mm) between the immediate and delayed implants at various time points

Time point	Group	N	Mean	Std. Deviation	Std. Error Mean	t value	P value
Baseline	Immediate	10	.00	.000	.000	NA	NA
	Delayed	10	.00	.000	.000		
3 months	Immediate	10	.7420	.33776	.10681	1.08	0.294
	Delayed	10	.5930	.27617	.08733		
6 months	Immediate	10	.8490	.25124	.07945	1.02	0.321
	Delayed	10	.7420	.21673	.06854		

Independent samples t test;  $p \leq 0.05$  considered statistically significant

Table 3: Comparison of bleeding on probing between the immediate and delayed implants at various time points

Time point	Group	N	Score 0	Score 1	Score 2	t value	P value
Baseline	Immediate	10	10 (100)	0	0	NA	NA
	Delayed	10	10 (100)	0	0		
3 months	Immediate	10	8 (80)	2 (20)	0	1.08	0.294
	Delayed	10	7 (70)	2 (20)	1 (10)		
6 months	Immediate	10	8 (80)	2 (20)	0	1.02	0.321
	Delayed	10	7 (70)	3 (30)	0		

Chi square test;  $p \leq 0.05$  considered statistically significant

Table 4: Comparison of mucosal thickness (mm) between the immediate and delayed implants at various time points

Time point	Group	N	Mean	Std. Deviation	Std. Error Mean	t value	P value
Baseline	Immediate	10	1.2220	.47511	.15024	0.952	0.354
	Delayed	10	1.0400	.37402	.11827		
3 months	Immediate	10	1.2100	.50211	.15878	0.569	0.576
	Delayed	10	1.1000	.34881	.11030		
6 months	Immediate	10	1.2000	.47376	.14981	0.629	0.537
	Delayed	10	1.0800	.37283	.11790		

Independent samples t test;  $p \leq 0.05$  considered statistically significant

## References

1. Pawar NN, Karkar PA. Loading protocol in implant dentistry: A review.
2. Huang H, Wu G, Hunziker E. The clinical significance of implant stability quotient (ISQ) measurements: A literature review. *Journal of oral biology and craniofacial research*. 2020 Oct 1;10(4):629-38.
3. Thapliyal GK, Pawar VR. A comparative analysis of peri implant bone levels of immediate and conventionally loaded implants. *Medical journal armed forces india*. 2013 Jan 1;69(1):41-7.
4. Karthik K, Siva raj S, Thang swamy V. Evaluation of implant success: A review of past and present concepts. *Journal of pharmacy & bio allied sciences*. 2013 Jun 2;5.
5. Carl E. Misch, *Contemporary Implant Dentistry*. 3rd edition. Elsevier: Mosby; 2008.
6. Smith DE, Zarb GA. Criteria for success of Osseo integrated endosseous implants. *J Prosthet Dent* 1989; 62:567-72.
7. Van Steenberghe D, Lekholm N, Bolender C, et al. The applicability of Osseo integrated oral implants in the rehabilitation of partial edentulism: a prospective multi-center study of 558 fixtures. *Int J Oral Maxillofac Implants*. 1990; 5:272-281.
8. Lazzara RJ, Testori T, Meltzer A, Craig M, Porter S, Goené RJ. "Immediate Occlusal Loading (IOL) of dental implants: predictable results through DIEM guidelines." *Pract Proceed Aesthet Dent: PPAD*. 2004;16(4):3-15.
9. Testori T, Szmukler-Moncler S, Francetti L, Del Fabbro M, Trisi P, Weinstein RL. Healing of Osseointegrated implants under submerged and immediate loading conditions in a single patient: a case report and interface analysis after 2 months. *Int J Periodontics Restorative Dent*. 2002; 22:345-353.
10. Henningsen A, Smeets R, Köppen K, Sehner S, Kornmann F, Gröbe A, Heiland M, Gerlach T. Immediate loading of subcrestally placed dental implants in anterior and premolar sites. *Journal of Cranio-Maxillofacial Surgery*. 2017 Nov 1;45(11):1898-905.
11. Al-Sawai AA, Labib H. Success of immediate loading implants compared to conventionally-loaded implants: a literature review. *Journal of investigative and clinical dentistry*. 2016 Aug;7(3):217-24.
12. Grunder U. Immediate functional loading of immediate implants in edentulous arches: two-year results. *Int J Periodontics Restorative Dent* 2002; 21: 545-51.
13. Valderrama P, Oates TW, Jones AA, Simpson J, Schoolfield JD, Cochran DL. Evaluation of two

different resonance frequency devices to detect implant stability: a clinical trial. *Journal of periodontology*. 2007 Feb;78(2):262-72.

14. Turk Yilmaz I, Mc Glumphy EA. Influence of bone density on implant stability parameters and implant success: a retrospective clinical study. *BMC oral health*. 2008 Dec;8(1):1-8.

15. Seong WJ, Holte JE, Holtan JR, Olin PS, Hodges JS, Ko CC. Initial stability measurement of dental implants placed in different anatomical regions of fresh human cadaver jawbone. *J Prosthet Dent*. 2008;99(6):425-34.

16. Gapski R, Wang HL, Mascarenhas P, Lang NP. Critical review of immediate implant loading. *Clin Oral Implants Res*. 2003;14(5):515-27

17. Szmukler-Moncler S, Piattelli A, Favero GA, Dubruille JH. Considerations preliminary to the application of early and immediate loading protocols in dental implantology. *Clin Oral Implants Res* 2000; 11: 12-25.

18. Mendonça G, Mendonça DBS, Aragão FJL, Cooper LF. Advancing dental implant surface technology –from micron- to nano topography. *Biomaterials* 2008; 29: 382-385.

19. Pardal-Peláez B, Flores-Fraile J, Pardal-Refoyo JL, Montero J. Implant loss and crestal bone loss in early loading versus delayed and immediate loading in edentulous mandibles. A systematic review and meta-analysis. *J Clin Exp Dent*. 2021;13(4): e397-e405.

20. Naser Sargolzaie, Evaluation of crestal bone resorption around cylindrical and conical implants following 6 months of loading: A randomized clinical trial. *Eur J Dent* 2017 Jul;11(3):317-22.

21. Singh K, Chand P, Chaurasia A, Solanki N, Pathak A. A randomized controlled trial for evaluation of bone density changes around immediate and nonfunctionally loaded implants using three-dimensional cone-beam

computed tomography. *The J Ind Prosthodontic Society*. 2022;22(1):74.

22. Brito C, Tenenbaum HC, Wong BK, Schmitt C, Nogueira-Filho G. Is keratinized mucosa indispensable to maintain peri-implant health? A systematic review of the literature. *J Biomed Mater Res B Appl Bio mater*. 2014; 102:643-650.