

Aesthetic rehabilitation of discoloured and extensively restored anterior teeth with e-max lithium disilicate laminate veneer and crowns - A Case Report¹Dr. Shwetha Sathish, ²Dr. Nivek Narayan R, ³Dr. Sharath Pare, ⁴Dr. Shreema Shetty, ⁵Dr. Rajaram Naik¹⁻⁵A J Institute of Dental Sciences and Hospital, Mangalore, Karnataka.**Corresponding Author:** Dr. Shwetha Sathish, A J Institute of Dental Sciences and Hospital, Mangalore, Karnataka.**Citation of this Article:** Dr. Shwetha Sathish, Dr. Nivek Narayan R, Dr. Sharath Pare, Dr. Shreema Shetty, Dr. Rajaram Naik, “Aesthetic rehabilitation of discoloured and extensively restored anterior teeth with e-max lithium disilicate laminate veneer and crowns - A Case Report”, IJDSIR- April - 2023, Volume – 6, Issue - 2, P. No. 479 – 485.**Copyright:** © 2023, Dr. Shwetha Sathish, et al. This is an open access journal and article distributed under the terms of the creative commons’ attribution non-commercial License. Which allows others to remix, tweak, and build upon the work non-commercially, as long as appropriate credit is given and the new creations are licensed under the identical terms.**Type of Publication:** Case Report**Conflicts of Interest:** Nil**Abstract**

All-ceramic systems represent an excellent restorative alternative for fixed dental prostheses, single crowns, and veneers in the anterior dentition. With respect to improved mechanical properties, lithium disilicate ceramic material provide a broad range of indications, which can be used in both full coverage crowns and veneers. Although ceramic veneers represent a more conservative approach compared to crowns, the correct indication is essential to achieving the ideal outcome. Additionally, improvements on physical properties and translucency for lithium disilicate ceramic have been made and a superior press ceramic material was introduced named as IPS e-max Press. The following case reports describes a case of replacing unsatisfactory, extensive and discoloured anterior composite restorations to re-establish the aesthetics and harmony of the patient’s smile, using a combination of lithium disilicate porcelain crowns and veneer.

Keywords: Lithium Disilicate, CAD-CAM, Veneers, IPS e-max press, Pulp space therapy**Introduction**

All clinicians and patients are in general agreement that colour of the tooth has a particular aesthetic value, tooth discoloration poses a serious aesthetic problem (1,2). The options to solve these problems range from composite resins to ceramics, each of which has advantages and limitations. For a long period, composite resin was the first option for cosmetic and conservative procedures, due to their conservation of tooth tissue, lower cost compared to ceramics, reversibility, and a relatively simple technique. However, such restorations have limited longevity, which compromises the long-term aesthetic results (3).

Therefore, the material of choice for patients with high aesthetic expectations and seeking for a long-lasting treatment have become the ceramics ⁽³⁾. The ceramics have several important characteristics, including colour

stability, translucency, reproduction of the optical properties of the dental structure, mechanical resistance, durability, adherence to the cementing agent and dental substrates, low plaque accumulation and biological compatibility. Lithium disilicate and zirconia are the most used, although zirconia has higher mechanical strength, the lithium disilicate has higher translucency (4,5,6).

Additionally, improvements on physical properties and translucency for lithium disilicate ceramic have been made and a superior press ceramic material was introduced named as IPS e-max Press (Ivoclar Vivadent) (7). The use of IPS e-max Press, relatively translucent high strength mono lithic ceramic material, is so widespread due to the increasing demand for aesthetic restorations (7).

The purpose of this paper is to present a case of replacing unsatisfactory, extensive and discoloured anterior composite restorations to re-establish the aesthetics and harmony of the patient's smile, using a combination of lithium disilicate porcelain crowns and veneer.

Case report

A 38-year-old female patient reported to the department of conservative dentistry and endodontics with a chief complaint of discoloration in the upper front tooth region. Her medical history was non-contributory. Intra oral examination showed the tooth 12,11,21,22 had extensive composite restorations, which was done nearly 3 years ago due to caries (FIGURE 1 AND 2). Upon, clinical examination the teeth were not sensitive to percussion and with normal probing depths. Radiographic examination showed proximal radiolucency's beneath the radiopacities approaching pulp in relation to the tooth 12, 11, 21 and 22 without any peri-apical changes (FIGURE 3 AND 4). Electric pulp testing and

cold test in relation to the tooth 12, showed no response whereas teeth 11,21 22 gave delayed response. The diagnosis was made as pulp necrosis with asymptomatic apical periodontitis with the tooth 12 and chronic irreversible pulpitis with normal Perio dontiumirt 11,21,22. So, the treatment possibilities for this case were a combination of composite resin re-restoration for the canines and root canal therapy for the tooth 12-22 followed by crowns or a combination of root canal therapy on the tooth 12-23 followed by crowns and veneer on the tooth 13 were proposed to the patient, as well as their advantages and limitations. The patient opted for the combination of ceramic crowns irt 12-23 and veneer on the tooth 13 as she wanted a more permanent aesthetic solution. Informed consent was obtained from the patient.

On the first visit, upon administration of local anesthesia (1: 80000 lignocaine) and rubber dam isolation, root canal therapy was initiated for the tooth 12-23 (FIGURE 5), working length was determined using electronic apex locator (Coltene Canalpro CL2i) and was confirmed with a radiograph. Canals were enlarged until size #F3 by Dentsply Protaper Gold file system.

The orifices were then provisionally sealed with Cavit. The patient was then recalled after 3 days, during which the patient remained asymptomatic. The provisional restoration was then removed and the canals were obturated with corresponding size master cone and AH plus root canal sealer (FIGURE 6 AND 7). Post- access restoration was done with composite resin (3M Filtek Bulk fill universal composite resin).

Following which, a maxillary occlusal record was fabricated for the purpose of temporization (FIGURE 8). Crown preparation was then done for the teeth 12-23 and butt-joint incisal veneer preparation was done for the tooth 13 (FIGURE 9,10 AND 11).

Gingival retraction was achieved using size 00 gingival retraction cord (FIGURE 12). CAD-CAM intra-oral scan was done by using CEREC system by Denstply and the necessary shade selection was done (FIGURE 13 AND 14). Temporisation was done using RelyX temporary – Non eugenol temporary material and was cemented using non-eugenol temporary luting cement (FIGURE 15).

Patient was recalled after 2 days following the fabrication of crowns and veneers from lithium disilicate by IPS-e. max CAD-CAM blocks. Try-in was done and necessary adjustments were made. Glazing and polishing procedure was then completed. Before the final cementation procedure, the veneer and crowns were treated by hydrofluoric acid and silane coupling agent and was cemented using RelyX resin luting cement (FIGURE 16). Post cementation instructions were given to the patient.

Discussion

In this case report, the patient's main complaint was about discoloured composite restorations in the upper front tooth region. So, the treatment possibilities for this case were a combination of composite resin restoration for the canines and root canal therapy for the tooth 12-22 followed by crowns or a combination of root canal therapy on the tooth 12-23 followed by crowns and veneer on the tooth 13 were proposed to the patient, as well as their advantages and limitations. The patient opted for the combination of ceramic crowns irt 12-23 and veneer on the tooth 13. According to Zandinejad et al, Lithium disilicate glass-ceramic is composed of 65% LD, which results in a relatively strong ceramic with a high flexural strength of about 400 MPa and fracture toughness of 3.3 MPa, and both values are approximately higher than the IPS empress 2(8). The LD system has a very clear translucency property that allows

light to reflect, due to the low refractive index of the crystals. This characteristic allows the use of the material for the manufacture of monolithic restorations, with a completely anatomical and integral contour⁽⁸⁾. In a study by Zarone et al, 74 anterior crowns and 20 posterior crowns made with LD (IPS-e. max) were evaluated and had a survival rate of 97.4% after five years and 94.8% after eight years of clinical service⁽⁹⁾. Veneers also exhibit natural fluorescence and absorb, reflect, and transmit light exactly as that of natural tooth⁽¹⁰⁾. According to Meijer Ing et al, survival rates for veneer restorations were 94% for porcelain, 90% for indirect composite, and 74% for direct composite restorations⁽¹¹⁾. In another study by Rotoli et al on the survival rate for bonded porcelain laminate veneer restorations is more than 90% over 10 years of clinical service⁽¹⁰⁾. As for the computer aided design (CAD)/computer-aided Manufacturing (CAM) system is a revolutionary technology in dentistry, as it allows ceramic restorations to be performed in the dental office through a milling machine, combining the benefits of direct restorations. The advantages are excellent adaptation and longevity, the use of newer materials with adequate mechanical properties, reduction of the operator's impact on the final quality of work, completion of treatment in a single consultation and making Provisionals and paying for the laboratory unnecessary⁽¹²⁾.

Conclusion

In this case, the use of LITHIUM DISILICATE glass-ceramic was an excellent treatment option in cases of anterior aesthetic rehabilitation as they exhibit natural fluorescence and absorb, reflect, and transmit light exactly as a natural tooth. However, we highlight that, to achieve this result, a detailed planning with a good communication between patient, dentist, as well as the

selection of appropriate dental materials along with the usage of latest technology such as CAD-CAM were essential.

References

1. Editorial. Prescribing a dental ceramics material: Zirconia vs lithium disilicate. The Saudi dental journal 2011; 23:165-166
2. Luke S. Kahng. Material Selection and shade Matching for a single Central incisor. The journal of cosmetic dentistry 2006; Vol 22; N 1:80-86
3. E. A. McLaren and Y. Y. Whiteman, "Ceramics: rationale for material selection," Compendium of Continuing Education in Dentistry, vol. 31, no. 9, pp. 666–668, 670, 672, 680, 700, 2010.
4. Kelly JR, Benetti P. Ceramic materials in dentistry: historical evolution and current practice. Australian Dental Journal 2011;56 Suppl 1:84-96.
5. Christensen GJ. The all-ceramic restoration dilemma: where are we? Journal of the American Dental Association 2011; 142:668-71.
6. Chu SJ. Current clinical strategies with lithium-disilicate restorations. Compendium of Continuing Education in Dentistry 2012; 33:64, 66-7.
7. Wolf art S, Eschbach S, Scherrer S, Kern M. Clinical outcome of three-unit lithiumdisilicate glass-ceramic fixed dental prostheses: up to 8 years results. Dental Materials 2009;25: e63-71.
8. Zandinejad A, Lin WS, Atarodi M, Abdel-Azim T, Metz MJ, Morton D. Digital workflow for virtually designing and milling ceramic lithium disilicate veneers: a clinical report. Operative dentistry. 2015;40(3):241-6
9. Zarone F., Ferrari M., Mangano FG., Leone R., Sorrentino R. 2016. "Digitally Oriented Materials": Focus on Lithium Disilicate Ceramics. Int J Dent.,1-10.
10. Josué Junior Araujo Pierote, Priscila Regis Pedreira, Giselle Maria Marchi and Luis Alexandre Maffei Sartini

Paulillo. 2020. "Esthetic rehabilitation with lithium disilicate porcelain veneers: Clinical Report", International Journal of Development Research.

11. Meijer Ing AC, Creugers NH, Roeters FJ, Mulder J. Survival of three types of veneer restorations in a clinical trial: a 2.5-year interim evaluation. Journal of dentistry. 1998 Sep 1;26(7):563-8.

12. Pie rote JJA, Cámara JVF, Barbosa IF, de Araújo CTP, Carvalho GAO, de Castro AN, Pereira GDS, Prieto LT. Esthetic rehabilitation with porcelain crowns using digital planning. Int J Case Rep Images 2020; 11: 10116 8Z01 JP 2020.

Legend Figure

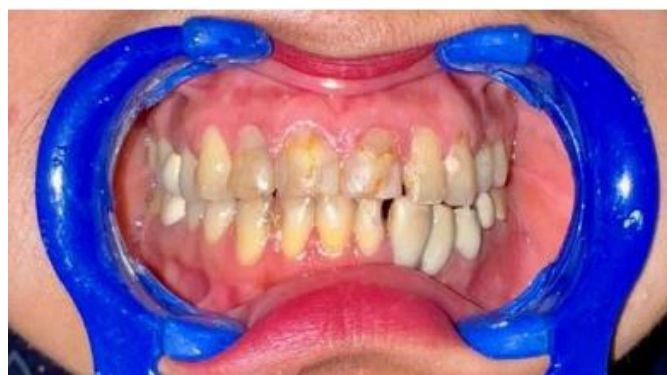

Figure 1:

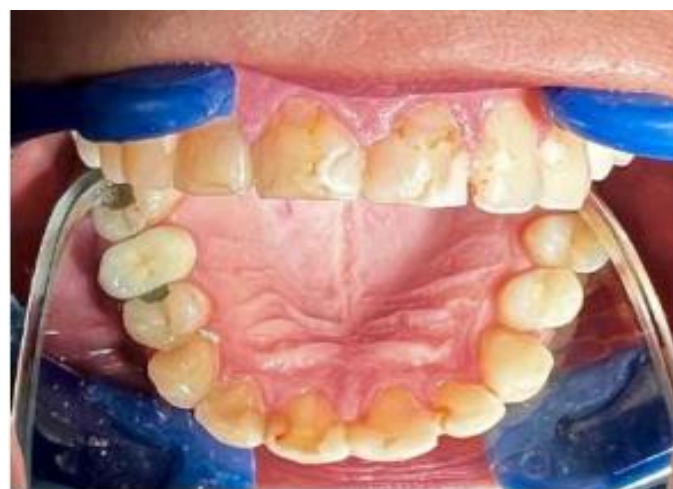

Figure 2:

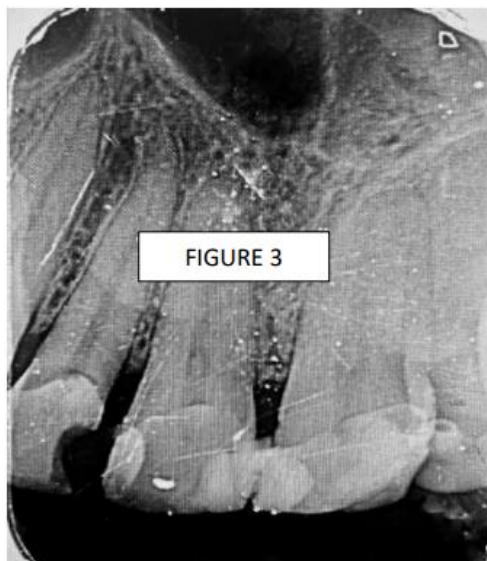


Figure 3:

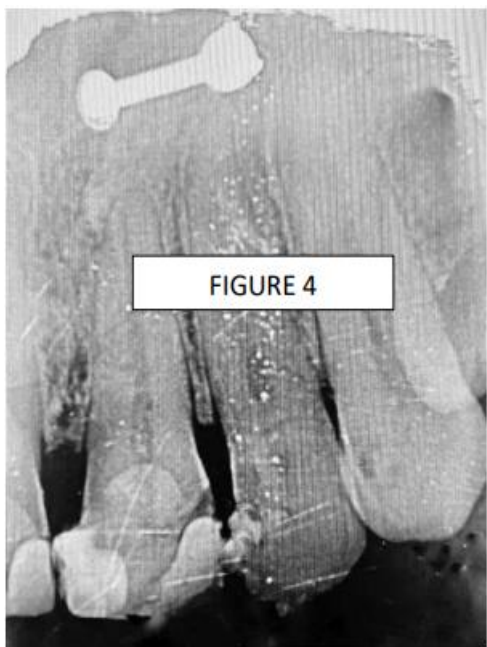


Figure 4:

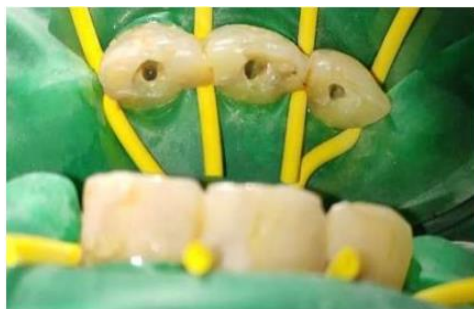

Figure 5:

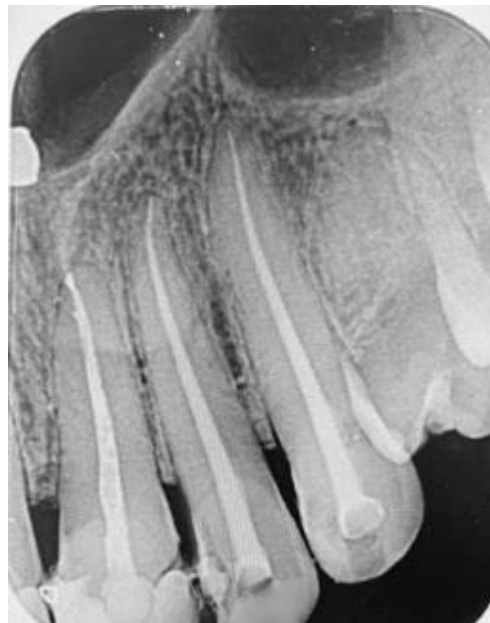

Figure 6:

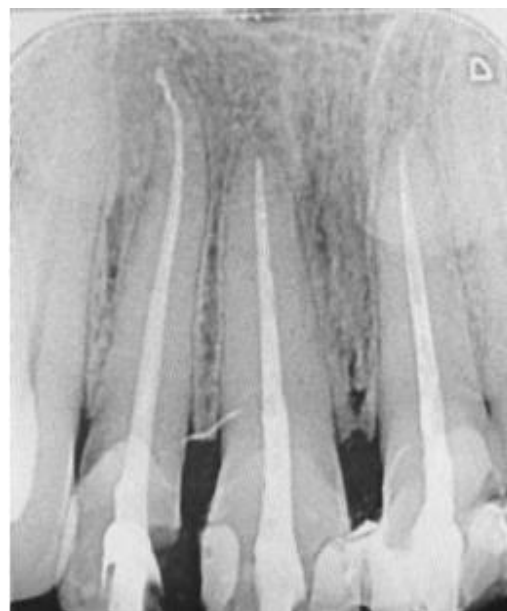

Figure 7:

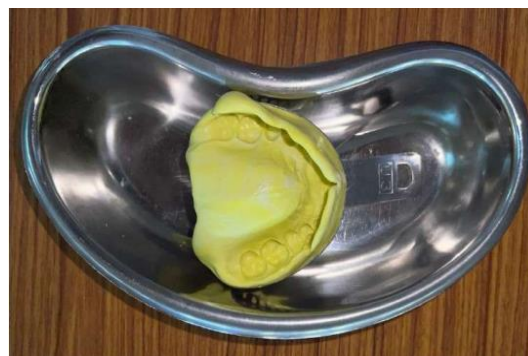

Figure 8:

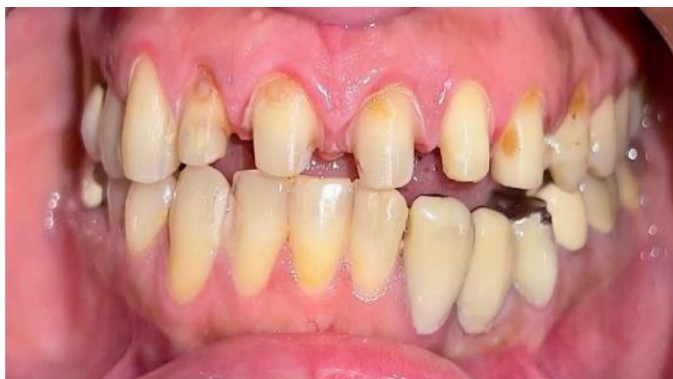

Figure 9:

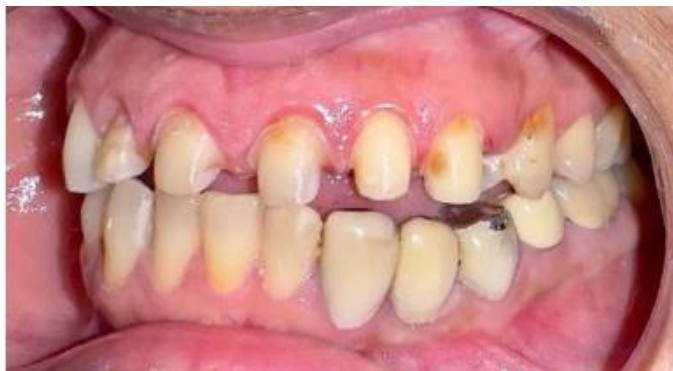

Figure 10:

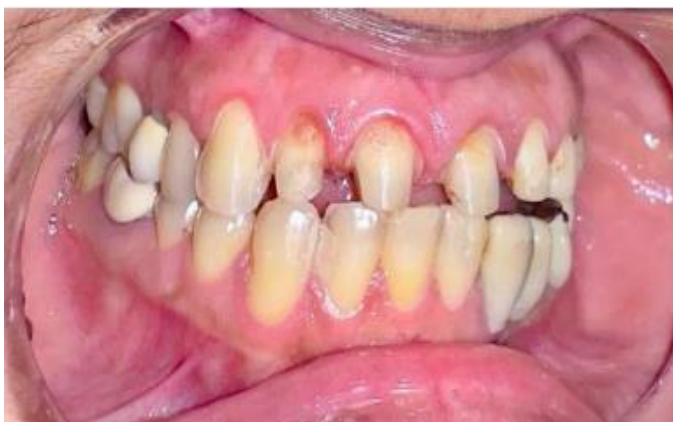

Figure 11:

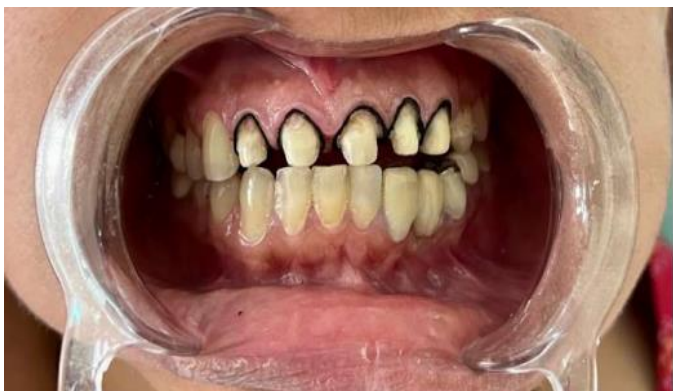

Figure 12:

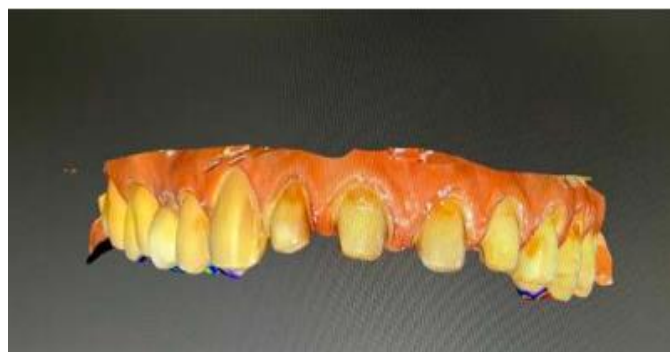

Figure 13:

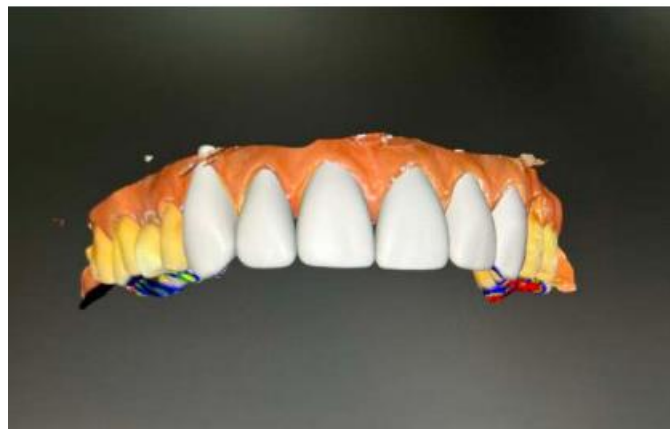

Figure 14:

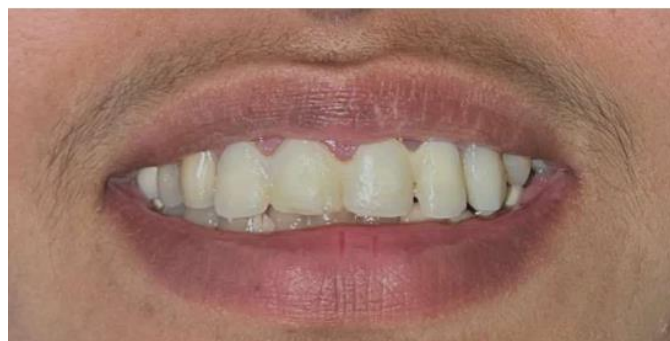

Figure 15:

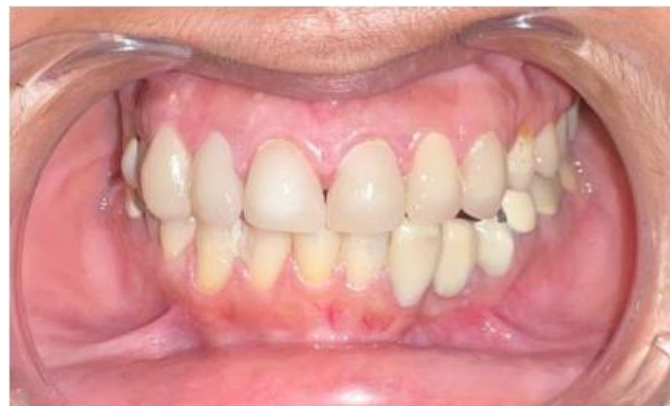

Figure 16:

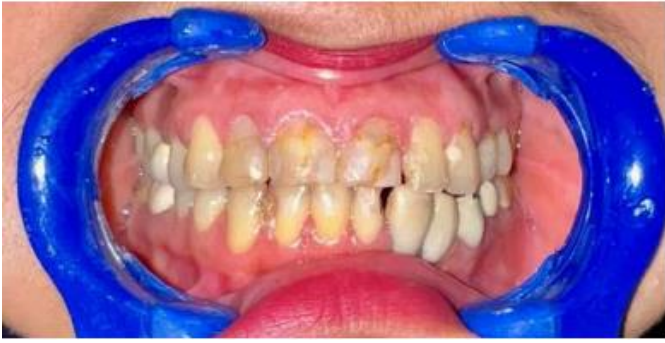

Figure 17:

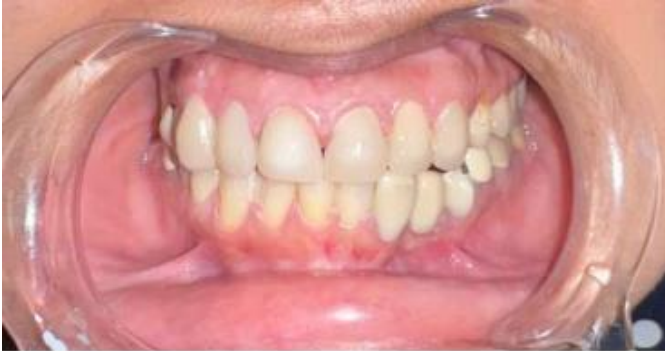

Figure 18: