

**A prospective study of role of autogenous bone graft in bone regeneration in bone deficit sites requiring dental implants.**

<sup>1</sup>Dr. Pradeep Singh, Junior Resident, Department of Oral & Maxillofacial Surgery, Punjab Government Dental College & Hospital, Amritsar, Punjab, India.

<sup>2</sup>Dr. Nitin Verma, Professor & Head, Department of Oral & Maxillofacial Surgery, Punjab Government Dental College & Hospital, Amritsar, Punjab, India.

<sup>3</sup>Dr. Puneet Girdhar, Professor, Department of Oral & Maxillofacial Surgery, Government Dental College & Hospital, Patiala, India.

<sup>4</sup>Dr. Ramninder Bawa, Reader, Department of Prosthodontics and Crown & Bridge, SGRD Institute of Dental Sciences and Research, Amritsar, Punjab, India.

<sup>5</sup>Dr. Zeniya Hashmi, Junior Resident, Department of Oral & Maxillofacial Surgery, Punjab Government Dental College & Hospital, Amritsar, Punjab, India.

**Corresponding Author:** Dr. Ramninder Bawa, Reader, Department of Prosthodontics and Crown & Bridge, SGRD Institute of Dental Sciences and Research, Amritsar, Punjab, India.

**Citation of this Article:** Dr. Pradeep Singh, Dr. Nitin Verma, Dr. Puneet Girdhar, Dr. Ramninder Bawa, Dr. Zeniya Hashmi, “A prospective study of role of autogenous bone graft in bone regeneration in bone deficit sites requiring dental implants”, IJDSIR- June - 2023, Volume – 6, Issue - 3, P. No. 400 – 408.

**Copyright:** © 2023, Dr. Ramninder Bawa, et al. This is an open access journal and article distributed under the terms of the creative common's attribution non-commercial License. Which allows others to remix, tweak, and build upon the work non-commercially, as long as appropriate credit is given and the new creations are licensed under the identical terms.

**Type of Publication:** Original Research Article

**Conflicts of Interest:** Nil

**Abstract**

**Introduction:** Oral rehabilitation of partially or fully edentulous patients with dental implants is a highly predictable treatment modality. Implant dentistry, due to its ability to achieve this goal, regardless of the atrophy of alveolar ridges, diseases or injury to stomatognathic system makes it unique treatment modality.

**Aim and Objectives:** The aim of this study was to evaluate the role of autogenous bone graft in bone

regeneration in the bone deficit sites requiring dental implants.

**Method:** Total ten patients will be evaluated for the role of autogenous bone graft in bone regeneration in bone deficit sites requiring dental implants. Evaluation will be done on 1) linear and volumetric changes in grafted site seen on CBCT pre and post operatively at 1 month and 6-month interval. 3) Patient discomfort. 3) soft tissue thickness and keratinized mucosa width. 4) inflammation.

**Results:** There was significant gain in the overall bone volume at the grafted site and significant percentage resorption of the graft. However, the average linear height change was insignificant. The soft tissue analysis showed significant change in the keratinized tissue width, However, the change in soft tissue thickness was insignificant.

**Conclusion:** The role of autogenous bone graft in bone regeneration placed in bone deficit sites requiring dental implants was noteworthy as there was a significant gain in the overall volume of the bone after placement of the autogenous bone graft. Additionally, the study found that there was a significant amount of percentage resorption (62.5%) of the autogenous bone graft placed, which was more than the amount proposed (50%) in the null hypothesis.

**Keywords:** Autogenous bone graft, cone beam computed tomography (CBCT), soft tissue thickness, keratinized tissue width

## Introduction

Oral rehabilitation of partially or fully edentulous patients with dental implants is a highly predictable treatment modality with reliable long-term<sup>1</sup>. The goal of modern dentistry is to restore the patient to normal contour, functions, esthetics, speech and health whether by removing caries from a tooth or replacing several missing teeth. Implant dentistry, due to its ability to achieve this goal, regardless of the atrophy of alveolar ridges, diseases or injury to stomatognathic system makes it unique treatment modality<sup>2</sup>.

There are various bone grafting materials available, and each one has its own risks and benefits. Autogenous bone grafting materials are the preferred ones among the options available, when it comes to choosing the graft material.

Since, autogenous bone grafts are osteoinductive, osteogenic, and osteoconductive, with a strong regenerative potential compared to other graft types. Thus, autogenous bone remains the gold standard for the repair of major lateral or vertical defects in the maxillofacial region<sup>3</sup>. However, acquiring autogenous bone graft requires additional surgical procedure. Hence, postoperative morbidity (eg. Edema, hematoma, pain and neuropathy) is inevitable in both surgical and donor sites<sup>4</sup>.

An inherent disadvantage of the autogenous bone graft is its known resorption potential, which varies between 24% and 51% after the first year<sup>5</sup>. So, the null hypothesis of the study was that the autogenous bone graft undergoes 50% of resorption from the original amount.

Autografts can be cancellous, cortical, corticocancellous, vascularized bone or aspirated bone marrow. The main advantage of autogenous bone is retention of at least some osteogenic cells without triggering the immune system. On the other hand, donor site morbidity and limited amount of available bone are basic disadvantages. Ideally, the bone graft should be incorporated into the recipient bed; the space that the bone graft occupies should finally become viable bone with physiological remodelling mechanisms. Many factors are involved in the incorporation process namely the graft type, graft bed (recipient site), and interface in between. Graft related factors including the type of graft, porosity and mechanism of incorporation. Recipient site viability and vascularity are very important in any autogenous grafting procedures<sup>6</sup>.

Several methods are available to harvest autogenous bone. In this study, a disposable, manual device (safescrapers curve, meta, reggio emilia, italy) was used to harvest bone. The safescrapers furnishes autologous

bone, avoiding the need for traditional incision-based techniques and cortico-cancellous bone block harvesting with associated post-operative discomfort<sup>7</sup>. Soft tissue thickness is essential for an esthetically pleasing implant restoration and has become of vital importance for both esthetic and functional success in implant dentistry. Also, the peri-implant soft tissue thickness (stt) and keratinized tissue width (ktw) are associated with the health of the periodontal tissues and clinical parameters.

### Materials and methodology

The present study was conducted on ten randomly selected subjects presenting in the outpatient department of oral and maxillofacial surgery, Punjab govt. Dental college and hospital, Amritsar. The ethical clearance for conducting the study was obtained from ethical committee of the institution.

**Null hypothesis:** Autogenous bone graft may undergo progressive resorption up to 50% of original volume.

### Method of collection of data

**Inclusion criteria:** Patients who require teeth replacement and are willing for implant supported prosthesis.

**Exclusion criteria:** Systemic diseases in which implant placement is contraindicated. Patients who are smokers or medically compromised.

**Radiographic evaluation:** Cone beam computed tomography (CBCT) was used for:

- A. Implant planning was done by measuring the dimensions.
- B. Based upon preoperative CBCT data, the linear and volumetric measurements of the site requiring the dental implant was taken and the bone deficiency, if any, was calculated. Further, double the amount of bone deficiency, autogenous bone graft was decided to be taken.

### Surgical technique

Patient was prepared following the strict aseptic precautions. The planned implant was placed, based on the clinical and preoperative cbct evaluation of dimensions of the implant and covered with cover screw.

The bone graft from the donor site was collected by bone scraper from same or different incision. A calibrated spoon was used to measure the amount of bone graft collected, so as to ensure that the amount of bone graft collected was at least two times the required volume as per the cbct assessment. Membrane was fixed and stabilized with bone tacks (tack-3-pt made in u.s.a) or 3-0 vicryl sutures. Graft was filled on the recipient site under the stabilized membrane. After achieving proper hemostasis, a tension free primary wound closure was done.

### Postoperative instructions

Patients were advised to follow the standard postoperative instructions. And at 6 months postoperatively. In order to ensure the reproducibility of volumetric measurements, the grafted sites were analysed with reference to the anatomic landmarks.

### CBCT analysis

CBCT scans were performed using a scanner ez3d-i vatech Samsung 1-ro 2-gil, hwaseongsi, Gyeonggi do, Korea.

### Linear analysis

For standardization of the examinations in order to obtain the same position at the different time points, positioning of the mandible was reoriented for vertical alignment of the long axis of the tooth adjacent to the graft receptor site in the sagittal and coronal sections.

The width was measured (in mm) from one cortical surface to the other in the buccolingual direction and the height was measured from crest of the edentulous

ridge to underlying anatomic landmark (roof of the mandibular canal or floor of maxillary sinus) pre-operatively and 1 month and 6 months postoperatively.

### Volumetric analysis

Volumetric analysis was performed at three different time points

- Pre-operatively, to confirm the available bone.
- Then at 1 month after the bone graft procedure.

### Soft tissue analysis

Soft tissue thickness was measured (in mm) using the endodontic spreader with stopper. The spreader was inserted, perforating the gingiva all the way to the cortical bone mid-facially from the crest of the edentulous ridge to the mucogingival junction. The measurements were taken using a digital calliper preoperatively, and repeated at 1 month and 6 months postoperatively. Keratinized tissue width of the edentulous sites was measured in millimeters from the central point of the planned implant site to the buccal mucogingival junction using a periodontal probe unc15. The measurements were taken using a digital calliper preoperatively and repeated at 1 month and 6 months postoperatively.

**Patient discomfort:** Patient discomfort was measured by using McGill pain questionnaire.

### Volumetric analysis using CBCT.

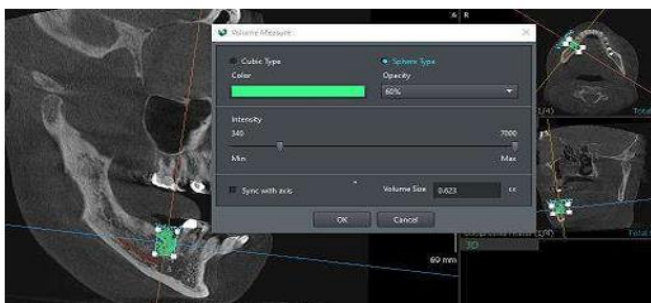


Figure 1: Preoperative bone volume

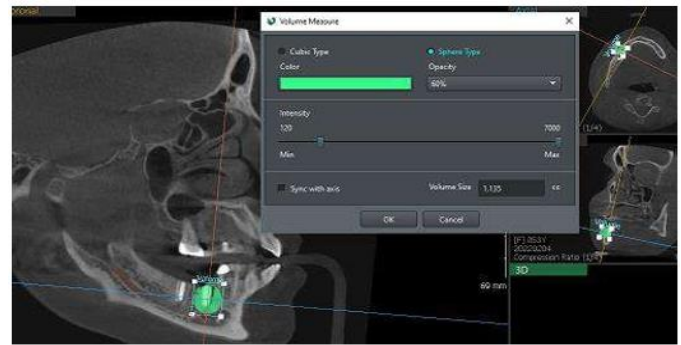


Figure 2: Postoperative Bone volume (6 months)

### Observation and results

#### Volumetric analysis

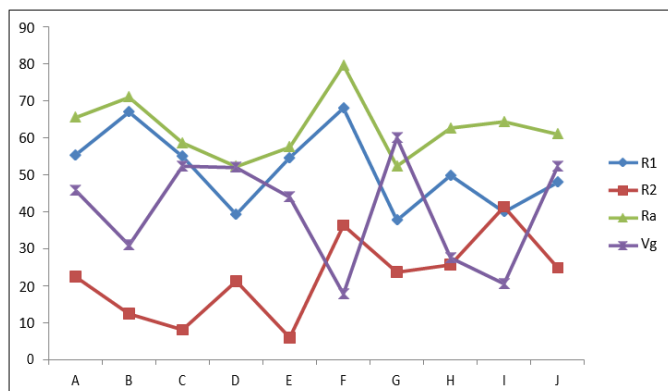
The volume of autogenous graft required was measured, and twice the measured amount (tg) of autogenous graft was taken.

- The total volume of grafted site (V) was obtained as  $T_o + T_g$ .
- Bone volume gain (Vg) was measured, and Vg %age was calculated as  $\frac{V_g}{T_o} \times 100$
- Bone resorption at 1 month (R1) postoperatively was measured, and R1 percentage was calculated as  $\frac{R_1}{T_g} \times 100$
- Bone resorption after 6 months (R2) postoperatively was measured, and R2 %age was calculated as  $\frac{R_2}{T_g - R_1} \times 100$
- Average bone resorption (Ra) was calculated as  $R_1 + R_2$ .
- Average bone resorption (Ra %age) was calculated as  $\frac{R_1 + R_2}{T_g} \times 100$

Table 1: Volume Analysis

Patient	To mm <sup>3</sup>	Tg mm <sup>3</sup>	V mm <sup>3</sup>	T <sup>1</sup> mm <sup>3</sup>	T <sup>2</sup> mm <sup>3</sup>	R <sup>1</sup> mm <sup>3</sup> & R1%	R <sup>2</sup> mm <sup>3</sup> & R2%	Ra mm <sup>3</sup> & Ra%	Vg mm <sup>3</sup> & Vg %
A	657.6	877.2	1534.8	1048.1	960	486.7 55.4%	88.1 22.5%	574.8 65.5%	302.4 45.9%
B	773.8	832	1605.8	1048	1014	557.7 67%	34.1 12.4%	591.8 71%	240.2 31%
C	550.36	698.54	1248.9	864.1	838.65	384.8 55%	25.45 8.1%	410.25 58.7%	288.29 52.38%
D	666.93	727.56	1394.49	1108.26	1014.26	286.23 39.34%	94 21.29%	380.23 52.26%	347.33 52%
E	709.63	734.98	1444.61	1041.9	1021.9	402.7 54.7%	20 6%	422.7 57.5%	312.27 44%
F	835.2	736.16	1571.36	1069.5	984.06	501.86 68.1%	85.44 36.4%	587.3 79.7%	148.86 17.8%
G	616.6	782.6	1399.2	1103.8	988.4	295.4 37.75%	115.4 23.7%	409.8 52.4%	371.8 60%
H	792	588.29	1380.26	1087	1011	293.26 49.9%	76 25.7%	369.26 62.7%	219 27.6%
I	680.2	724	1290.2	1000.1	820.1	290 40%	180 41.4%	470 64.4%	139.9 20.56%
J	780.8	850	1708.8	1300.2	1190	408.6 48%	110.2 24.9%	518.8 61%	409.2 52.4%

Graph 1: Volumetric Analysis



Linear analysis

Table 2: Width measurement (in mm)

Width	Mean	SD	Mean Difference	P - Value
Preoperative	5.130	0.31287	-2.640	0.001
At 6 months	7.770	0.37727		

Table 3: Height measurement (in mm)

Height	Mean	SD	Mean Difference	P - Value
Preoperative	11.360	1.936	-0.920	0.216
At 6 months	12.280	1.179		

## Discussion

For a favourable long-term prognosis in patients treated with Osseo integrated implants, sufficient bone volume is an important prerequisite<sup>10</sup>. After reviewing 109 literatures proposed the new classification system based on anatomical and radiological jawbone quantity and quality which is used for evaluation and planning of strategy in endosseous dental implant treatment. According to this new classification system, implant planning should be done on three- dimensional edentulous jaw segment (ejs) pattern<sup>10</sup>. Therefore, on account of this new classification system, we selected bone deficit sites in patients requiring dental implants and measured the amount of bone graft required using CBCT in terms of preoperative linear and volumetric analysis.

Autogenous bone grafts are considered the gold standard for the rehabilitation of atrophic areas with good reliability and predictability for the placement of implants<sup>11</sup>. However, an inherent disadvantage of the autogenous bone graft is its known resorption potential, which varies between 24% and 51% after the first year<sup>5</sup>. There are several methods available for harvesting the particulate autogenous bone. The most common method used, is to mill bone by rotating electrical instruments which apparently reduces the amount of viable bone cells supplied<sup>12</sup>. Surgical requirements, such as milling cannot always be met in the dental office and these types of bone treatments, surely deplete bone quality<sup>13</sup>. According to a study, the bone chips obtained using a disposable,

Manual device (safescrapers curve, meta) contains live osteocytes, when examined microscopically, indicating a good quality of the bone harvest along with appreciable amount of bone formation<sup>14</sup>. In the present study we used a safescraper to harvest good quantities

of uncontaminated autogenous bone graft in form of cortical bone particulates from donor site. Also, the safescrapers furnishes autologous bone, avoiding the need for traditional incision-based techniques and cortico-cancellous bone block harvesting with associated post-operative discomfort<sup>15</sup>.

Accuracy of CBCT images for assessing 3d linear measurements and volume of bone in the maxilla or mandible has been demonstrated in a few studies<sup>16</sup>. With this new technology, implant sites can be properly planned before surgery according to bone volume and quality, precise location of anatomical structures (nerves, vessels, sinuses), prosthetic and esthetic evaluation leading to higher success rates<sup>17</sup>.

So, we used CBCT to measure amount of bone graft required in the bone deficit sites preoperatively and to analyze postoperatively the volumetric and linear changes in the grafted sites after using autogenous bone grafts in 10 patients requiring dental implants. The measurements were taken at the interval of one month and six months postoperatively. Manual device (Safescrapers curve, Meta) contain live osteocytes, when examined microscopically, indicating a good quality of the bone harvest along with appreciable amount of bone formation<sup>14</sup>. In the present study we used a Safescraper to harvest good quantities of uncontaminated autogenous bone graft in form of cortical bone particulates from donor site. Also, the safescrapers furnishes autologous bone, avoiding the need for traditional incision-based techniques and cortico-cancellous bone block harvesting with associated post-operative discomfort<sup>15</sup>. On volumetric analysis of the grafted sites in all patients, the average bone resorption after 6 months came out to be 62.5%, which is more than the expected amount hypothesized in our study. This was in concurrence to the study



conducted, which suggested that the bone scraper harvests cortical bone graft, and resorption occurs before deposition of new bone<sup>18</sup>.

Additionally, the new bone volume gained 6 months postoperatively came out to be 40.4%. The result is in accordance with the study conducted, which evaluated volumetric and clinical outcomes of atrophic posterior mandibles treated with inlay or only bone grafting technique and reported a final volume gain of 40%<sup>19</sup>. On linear analysis of the grafted sites in all the patients, the average gain in the linear width was found to be 2.64 mm after 6 months. The result is in accordance with the study conducted, which analyzed the clinical outcome of horizontal ridge augmentation using autogenous block grafts in 42 patients and reported an average gain in bone width of 2-7 mm<sup>15</sup>. Change in height seen preoperatively and postoperatively was clinically non-significant. This is due to the fact that vertical bone defects were not addressed in our study because the majority of the implant placement sites had horizontal bone defect with crest width <5.5 mm.

In our study, the postoperative soft tissue thickness as compared to preoperative measurements came out to be non-significant. Furthermore, only one clinical study conducted, concluded that there was no statistically significant change in the soft tissue thickness after the sub crestal placement of implant<sup>20</sup>. The keratinized tissue width (KTW) was another soft tissue parameter evaluated in our study. The results showed significant decrease in KTW with average decrease of 2.24 mm.

It has been found that the mean bone loss was higher for implants with narrow band of keratinized mucosa, which was in accordance with our study. This suggests that the bone grafting procedures require preimplant soft tissue enhancement procedures such as connective tissue

graft for better soft tissue health and longevity of implants<sup>21 22</sup>.

The patient discomfort was also evaluated in our study using McGill Pain Questionnaire<sup>23</sup>. In our study, the pain rating index (PRI) was computed to be 7.5. Also, the present pain index (PPI) was found to be 1.5 suggestive of mild discomfort/pain to the patient.

The inflammation was also evaluated postoperatively at 3<sup>rd</sup> and 7<sup>th</sup> day. The result shows presence of erythema at 3<sup>rd</sup> day postoperative was present in 100% cases and at 7<sup>th</sup> day of follow up absence of erythema was in 50% cases, presence of erythema in 30% cases and ulceration at surgical site in 20% cases.

In the present study, the autogenous bone grafts were obtained from the ipsilateral area of the recipient area, avoiding the need for a second donor site. Hence, this would suffice less patient discomfort and minimum postoperative inflammation reported in our study.

It's noteworthy that further studies are required to assess the significance of soft tissue thickness in bone grafting procedures. Also, additional studies with longer follow up period are required to analyze probable future bone loss around the implant/grafted site due to decrease in KTW.

### Conclusion

The study concluded that the role of autogenous bone graft in bone regeneration was noteworthy as there was a significant gain in the overall volume of the bone after placement of the autogenous bone graft. Additionally, the study found that there was a significant amount of percentage resorption (62.5%) of the autogenous bone graft placed, which was more than the amount proposed (50%) in the null hypothesis. Although, based on the sample size and methodology used, our study has

shown definitive conclusion, however, we wish to point out the following facts,

1. A large sample size could have further validated the results.
2. Further studies in terms of soft tissue evaluation around the grafted sites would be quite helpful in more comprehensive observation and results.

## References

1. Nielsen HB, Starch-Jensen T. Lateral ridge augmentation in the posterior part of the mandible with an autogenous bone block graft harvested from the ascending mandibular ramus. A 10-year retrospective study. *Journal of stomatology, oral and maxillofacial surgery*. 2021 Apr 1;122(2):141-6
2. Misch CE. Contemporary implant dentistry. *Implant Dentistry*. 1999 Jan 1;8(1):90.
3. Novy LF, Aguiar EG, de Arruda JA, de Castro MA, Moreira AN, Dos Santos EG, de Magalhães CS, Moreno A. Linear and volumetric gain after vertical bone augmentation in the posterior mandible using an autologous cortical tenting method. *International Journal of Oral and Maxillofacial Surgery*. 2019 Nov 1;48(11):1485-91
4. Chaushu L, Silva ER, Balan VF, Chaushu G, Xavier SP. Sinus augmentation-autograft vs. Fresh frozen allograft: Bone density dynamics and implant stability. *Journal of Stomatology, Oral and Maxillofacial Surgery*. 2021 Nov 1;122(5):467-71
5. Borba AM, Borges AH, da Silva CS, Brozoski MA, da Graça Naclério-Homem M, Miloro M. Predictors of complication for alveolar cleft bone graft. *British Journal of Oral and Maxillofacial Surgery*. 2014 Feb 1;52(2):174-8.
6. Bauer, T.W. and Muschler, G.F., 2000. Bone graft materials: an overview of the basic science. *Clinical Orthopaedics and Related Research*®, 371, pp.10-27
7. Von Arx T, Buser D. Horizontal ridge augmentation using autogenous block grafts and the guided bone regeneration technique with collagen membranes: a clinical study with 42 patients. *Clinical oral implants research*. 2006 Aug;17(4):359-66.
8. Abrahams JJ, Hayt MW, Rock R. Sinus lift procedure of the maxilla in patients with inadequate bone for dental implants: radiographic appearance. *American Journal of Roentgenology*. 2000 May;174(5):1289-92.
9. Misch CE. Contemporary implant dentistry. *Implant Dentistry*. 1999 Jan 1;8(1):90
10. Juodzbalsys G, Daugela P. Mandibular third molar impaction: review of literature and a proposal of a classification. *Journal of oral & maxillofacial research*. 2013 Apr;4(2).
11. Esposito M, Grusovin MG, Felice P, Karatzopoulos G, Worthington HV, Coulthard P. Interventions for replacing missing teeth: horizontal and vertical bone augmentation techniques for dental implant treatment. *Cochrane database of systematic reviews*. 2009(4).
12. Springer IN, Terheyden H, Geiß S, Härle F, Hedderich J, Açıl Y. Particulated bone grafts—effectiveness of bone cell supply. *Clinical Oral Implants Research*. 2004 Apr;15(2):205-12
13. Young MP, Carter DH, Worthington H, Korachi M, Drucker DB. Microbial analysis of bone collected during implant surgery: a clinical and laboratory study. *Clinical oral implants research*. 2001 Apr;12(2):95-103
14. Zaffe D, D'Avenia F. A novel bone scraper for intraoral harvesting: a device for filling small bone



- defects. *Clinical Oral Implants Research*. 2007 Aug;18(4):525-33.
15. Von Arx T, Buser D. Horizontal ridge augmentation using autogenous block grafts and the guided bone regeneration technique with collagen membranes: a clinical study with 42 patients. *Clinical oral implants research*. 2006 Aug;17(4):359-66
16. Veyre-Goulet S, Fortin T, Thierry A. Accuracy of linear measurement provided by cone beam computed tomography to assess bone quantity in the posterior maxilla: a human cadaver study. *Clinical implant dentistry and related research*. 2008 Dec;10(4):226-30
17. Cristache, C.M. and Gurbanescu, S., 2017. Accuracy evaluation of a stereolithographic surgical template for dental implant insertion using 3D superimposition protocol. *International journal of dentistry*, 2017
18. Finkemeier CG. Bone-grafting and bone-graft substitutes. *JBJS*. 2002 Mar 1;84(3):454-64.
19. Barone A, Toti P, Menchini-Fabris GB, Felice P, Marchionni S, Covani U. Early volumetric changes after vertical augmentation of the atrophic posterior mandible with interpositional block graft versus onlay bone graft: A retrospective radiological study. *Journal of Cranio-Maxillofacial Surgery*. 2017 Sep 1;45(9):1438-47.
20. Koh RU, Oh TJ, Rudek I, Neiva GF, Misch CE, Rothman ED, Wang HL. Hard and soft tissue changes after crestal and subcrestal immediate implant placement. *Journal of Periodontology*. 2011 Aug;82(8):1112-20
21. Bouri Jr A, Bissada N, Al-Zahrani MS, Faddoul F, Nouneh I. Width of keratinized gingiva and the health status of the supporting tissues around dental implants. *International Journal of Oral & Maxillofacial Implants*. 2008 Apr 1;23(2).).
22. Kim BS, Kim YK, Yun PY, Yi YJ, Lee HJ, Kim SG, Son JS. Evaluation of peri-implant tissue response according to the presence of keratinized mucosa. *Oral Surgery, Oral Medicine, Oral Pathology, Oral Radiology, and Endodontology*. 2009 Mar 1;107(3):e24-8.
23. Melzack R. The McGill Pain Questionnaire: major properties and scoring methods. *pain*. 1975 Sep 1;1(3):277-99.