

## **Surgical Approach to A Rare Idiopathic Masseteric Hypertrophy: A Case Report**

<sup>1</sup>Dr. KS Manjunath, Professor and Head of the Department, Oral and Maxillofacial Surgery, Sri Hasanamba Dental College and Hospital.

<sup>2</sup>Dr. Adhithia Govind, Postgraduate, Department of Oral and Maxillofacial Surgery, Sri Hasanamba Dental College and Hospital.

<sup>3</sup>Dr. N. R Madhusuthan, Senior Lecturer, Department of Oral and Maxillofacial Surgery, Sri Hasanamba Dental College and Hospital.

<sup>4</sup>Dr. Shashidara Kamath K, Professor, Department of Oral and Maxillofacial Surgery, Sri Hasanamba Dental College and Hospital

<sup>5</sup>Dr. Kubendran, Postgraduate, Department of Oral and Maxillofacial Surgery, Sri Hasanamba Dental College and Hospital

**Corresponding Author:** Dr. Adhithia Govind, Postgraduate, Department of Oral and Maxillofacial Surgery, Sri Hasanamba Dental College and Hospital.

**Citation of this Article:** Dr. KS Manjunath, Dr. Adhithia Govind, Dr. N. R Madhusuthan, Dr. Shashidara Kamath K, Dr. Kubendran, "Surgical Approach to A Rare Idiopathic Masseteric Hypertrophy: A Case Report", IJDSIR- June - 2023, Volume – 6, Issue - 3, P. No. 325 – 330.

**Copyright:** © 2023, Dr. Abhishek R, et al. This is an open access journal and article distributed under the terms of the creative common's attribution non-commercial License. Which allows others to remix, tweak, and build upon the work non-commercially, as long as appropriate credit is given and the new creations are licensed under the identical terms.

**Type of Publication:** Case Report

**Conflicts of Interest:** Nil

### **Abstract**

Idiopathic masseter hypertrophy is one of the rare conditions which results in enlargement of the masseter muscle and which is sometimes associated with bony exostosis at the mandibular angle region. It can be unilateral or bilateral. Most patients complain of facial asymmetry; however, symptoms such as trismus, protrusion, and bruxism may also occur. Here is a case report of a 19 year old female patient with unilateral masseteric hypertrophy with bony exostosis at the mandibular angle on the right side, where surgical excision of the deep fibers of masseter muscle along with removal of excess bone at the outer cortex was

carried out intraorally and patient was followed up for a period of 2 months at a weekly interval post operatively.

**Keywords:** MMH, IMM, TMJ, Etiology.

### **Introduction**

Masseter muscle hypertrophy (MMH) is an abnormal enlargement of the masseter muscle, either unilaterally or bilaterally characterized by an increase in the volume of the muscle mass. Idiopathic masseter muscle hypertrophy (IMMH) was first described by Legg in 1880. It is usually an asymptomatic enlargement of one or both masseter muscles. In some cases, patients may report signs and symptoms of well-localized pain, trismus and altered facial line. The highest incidence is

seen in the 2<sup>nd</sup> and 3<sup>rd</sup> decades of life with no gender predilection<sup>1</sup>. It is not often seen in older patients because dental deterioration which inhibits the ability to forcefully clench or grind teeth<sup>2</sup>. A congenital variety also exists, but acquired masseter hypertrophy is more common.

The etiology of masseter hypertrophy has been attributed to many factors such as tensions and clenching caused by emotional stress, chronic bruxism and parafunctional habits<sup>3</sup>. The diagnosis is mainly based on clinical history, physical examination, radiographs including OPG and PA view. It may even include complementary imaging resources such as magnetic resonance (MR) and computed tomography (CT) scans to exclude other disorders. The differential diagnosis includes parotiditis, parotid tumor, lipoma, benign or malignant muscle tumors, vascular tumors, benign, and malignant mandibular tumors<sup>1</sup>.

### Case Report

A 19 year old female patient visited our unit with the chief complaint of growth in the right lower 1/3<sup>rd</sup> of face since 6 month which is gradually increasing in size. Patient gave no history of pain or difficulty in opening the mouth. Patient gives history of chewing from both the sides equally but predominantly on the right side. On clinical examination a diffused swelling was noted at the right lower 1/3<sup>rd</sup> of the face extending anteroposteriorly 3cm from the corner of the mouth to 0.5cm posterior to the posterior border of the ramus of the mandible in the right side. Superoinferiorly the swelling extends from the alar tragal line to inferior border of the mandible. On palpation the mass is mobile and non tender, firm to soft in consistency which is more prominent on chewing. Temporomandibular joint (TMJ) showed well-coordinated and symmetrical movements with no clicking, crepitus or deviation. On intraoral examination

a diffused swelling was noted at the right buccal mucosa extending from the distal portion of 46 to the retromolar region measuring roughly about 2x2cm in size.

Investigations like routine blood investigations, OPG and MRI was done to confirm the diagnosis.

Patient was educated about both the conservative and surgical management and the patient had opted for the surgical line of treatment under general anesthesia. A vestibular incision extending to the anterior border of the ramus of the mandible was placed and full thickness mucoperiosteal flap was reflected exposing the temporalis muscle and hypertrophied masseter muscle on the right side. Angle of the mandible was identified and osteotomy at the right angle region was carried out. Deep and middle fibres of the masseter muscle was clamped and excised. Primary closure was achieved using 3-0 vicryl. Patient was followed up weekly for a period of 2 months.

### Discussion

The masseter, a thick quadrangle masticatory muscle, arises from the zygomatic arch and inserts into the inferior lateral aspect and angle area of the mandibular ramus<sup>1</sup>. Several theories have been proposed to explain the aetiology of masseter hypertrophy ranging from its description as a 'work hypertrophy' due to excessive grinding/chewing or an inability to chew from other side due to dental diseases like caries, periodontal problems or missing teeth, to masseter fatigue and lack of uniform enlargement of the muscle hold<sup>4</sup>. Although the etiology of this condition is still unclear, certain factors, such as temporomandibular joint disorders, stomatognathic system dysfunction, bruxism, mental disorders, or excessive use of chewing gum are thought to be involved; unilateral occurrence can be seen when patients chew or clench primarily on one side. Zachariades et al. speculated that a vascular lesion may

gradually subside to a residual muscular hypertrophy; they reported two cases in which phleboliths were associated with masseteric hypertrophy<sup>5</sup>.

Diagnosis of masseter hypertrophy can be achieved from clinical examination, history, panoramic X-ray, and muscle palpation. The best diagnostic test is to palpate the masseter muscle with fingers, while the patient clenches his/her teeth so the muscle is more prominent during contraction<sup>6</sup>. However, clenching commonly leads to formation of a tumour like mass on lateral surface of the masseter. Palpation, at rest reveals a soft, non-tender and ill-defined mass along the direction of muscle fibres<sup>4</sup>. Before deciding on the treatment plan, a MRI or CT should be taken to exclude possible pathologies such as muscle tumors, salivary gland disorders, parotid tumors, parotid inflammatory diseases, and intrinsic masseter myopathy. In our case the MRI of the patient revealed diffused enlargement of the right masseter muscle with no focal lesion and the OPG showed a bony spur at the angle region with prominent antegonial notch which is suggestive of angular exostosis.

There is not yet a standard protocol in the literature about the treatment of masseter hypertrophy. The treatment modalities for masseter hypertrophy can be nonsurgical and surgical<sup>5</sup>. Management of the idiopathic masseter hypertrophy is based on psychological counselling, use of mouth guards, muscle relaxant, and anxiolytic drugs, analgesics, physical therapy, dental restorations, and occlusal adjustments to correct premature contacts<sup>1</sup>. A good result can be achieved in the patients with mild hypertrophy but there is no reliable report on the literature on the success rates of isolated clinical therapy.<sup>2</sup> Injection of botulinum toxin type A into the masseter muscle is generally considered a less invasive modality and has been advocated for

cosmetic sculpting of the lower face. Botulinum toxin type A is a powerful neurotoxin which is produced by the anaerobic organism *Clostridium botulinum* and when injected into a muscle causes interference with the neurotransmitter mechanism producing selective paralysis and subsequent atrophy of the muscle<sup>4</sup>. Perhaps the biggest disadvantage of botulinum toxin therapy is that the treatment effect wears away and reverts to the original condition in 6 months<sup>6</sup>.

The traditional method of treatment for masseter hypertrophy is the surgical partial excision of masseter muscle under general anesthesia, proposed for the first time by Gurney in 1947<sup>6</sup>. The surgical treatment is based on intra- and extra-oral approaches. Both techniques revolve around the removal of excessive muscle fibres from the inner third of the masseter muscle. Reduction osteoplasty may be performed in cases of bony hyperplasia of the mandibular angle, which was carried out in our case. Excision of the inner layer of the hypertrophied muscle bundle was considered to be a more essential approach as hyperactivity of the masseter muscle was considered to be the key etiology behind excessive bone deposition at the mandibular angle. So, muscular resection was acknowledged as prime, followed by mandibular anguloplasty, as and when required. In the beginning, the extraoral approach was widely indicated, because it offered better visualization. However, with the development of new surgical materials and techniques (rotation instruments, surgical saws, specific retractors, and, more recently, intraoral endoscopy), the intraoral approach has become a good option. The procedure carried out in our case was through intraoral approach which is aesthetically superior with no scar compared to the extra-oral approach. Another advantage of using the intraoral approach is that resecting the bone subperiosteally leaves

the muscle sling intact, minimizing the possibility of nerve damage<sup>1</sup>. The surgical technique employed in this case, allowed shaving of the bony exostosis, smoothing of the spur formation and osseous recontouring of the mandibular angle, thus enabling simultaneous muscle debulking as well as reduction osteoplasty so as to achieve an ideal lower facial contour and shape, by addressing both hard and soft tissues in the region. This approach requires operator expertise, is much more technique-sensitive, tedious and time-consuming, and is limited in applicability for only those cases which can be managed by minor bony angle contouring or resection of small amounts of the masseter muscle mass. Traction injuries to branches of the facial nerve and intraoperative hemorrhage to the facial vessels in the vicinity, in addition to a prolonged operating time are distinct drawbacks of the intraoral approach<sup>8</sup>.

There are both intraoperative and post operative complications for the surgery such as mandibular fracture, hematoma, persistent asymmetry, damage to Stensen's duct and trismus. The patient in this case experienced trismus and pain, for which patient underwent physiotherapy and the mouth opening was improved to normal range within one month.

### Conclusion

Masseteric muscle hypertrophy is a disease of unknown etiology. Even though there are many approaches for the treatment of idiopathic masseteric hypertrophy, the surgical excision of the masseter muscle remains as the most effective treatment modality.

### References

1. Singh S, Shivamurthy DM, Agrawal G, Varghese D. Surgical management of masseteric hypertrophy and mandibular retrognathism. *National journal of maxillofacial surgery*. 2011 Jan;2(1):96.
2. Almkhatar RM, Fabi SG. The masseter muscle and its role in facial contouring, aging, and quality of life: a literature review. *Plastic and Reconstructive Surgery*. 2019 Jan 1;143(1):39e-48e.
3. Ayhan M, İşler SC, Kasapoglu C. Combination of medical and surgical treatments for masseter hypertrophy. *Case Reports in Dentistry*. 2018 Apr 5;2018.
4. Mohanty S, Kumar P, Gulati U, Dabas J, Kohli S, Choudhary Z. Anatomic and functional changes after myotomy with or without mandibular anguloplasty in masseter hypertrophy patients: A prospective study. *Journal of Oral and Maxillofacial Surgery, Medicine, and Pathology*. 2019 May 1;31(3):163-8.
5. Țarcă E, Cojocaru E, Luca AC, Trandafir LM, Roșu ST, Munteanu V, Țarcă V, Budacu CC, Costea CF. Unusual Case of Masseter Muscle Hypertrophy in Adolescence—Case Report and Literature Overview. *Diagnostics*. 2022 Feb 16;12(2):505.
6. Shetty N, Malaviya RK, Gupta MK. Management of unilateral masseter hypertrophy and hypertrophic scar—a case report. *Case reports in dentistry*. 2012 Jul 10;2012.
7. Beckers HL. Masseteric muscle hypertrophy and its intraoral surgical correction. *Journal of maxillofacial surgery*. 1977 Jan 1;5:28-35.
8. Jeyaraj CD. Angle Osteoplasty and Cosmetic Debulking for Correction of a Case of Unilateral Masseteric Hypertrophy. *The American Journal of Cosmetic Surgery*. 2021 Dec;38(4):217-24.
9. Kebede B, Megersa S. Idiopathic masseter muscle hypertrophy. *Ethiopian Journal of Health Sciences*. 2011;21(3).



## Legend Figures

### Pre Operative Photographs

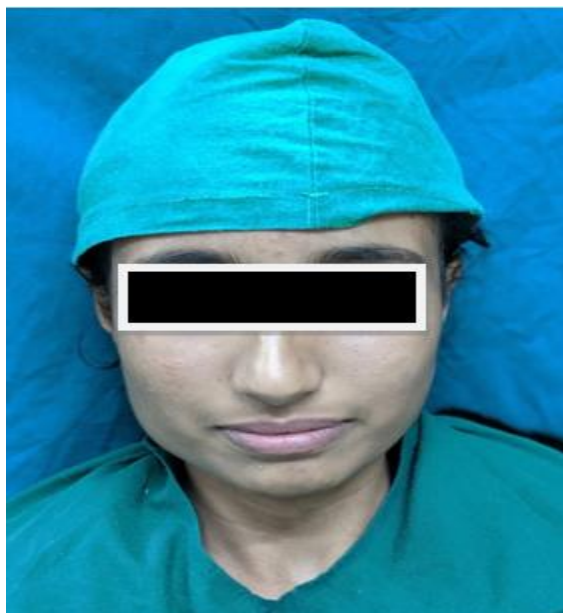

Figure 1: Frontal View

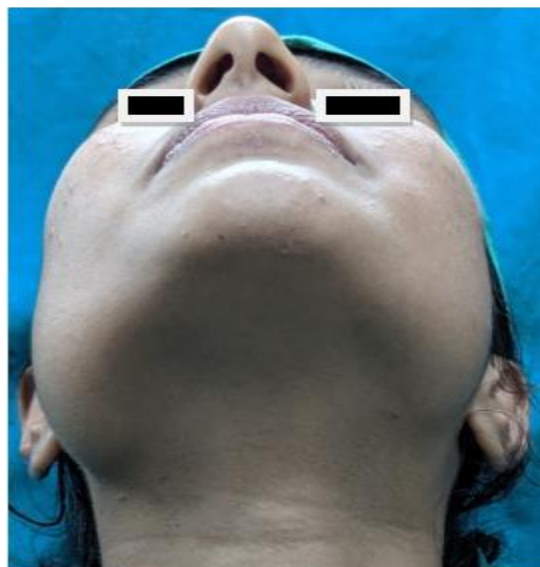

Figure 2: Worms View

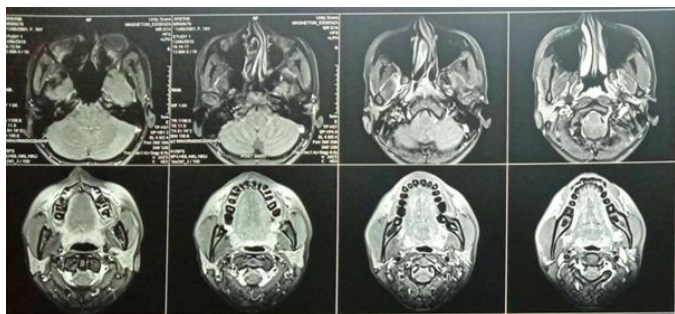


Figure 3: MRI Revealing Hypertrophic Masseter Muscle At The Right Side

### Intra Operative Photographs

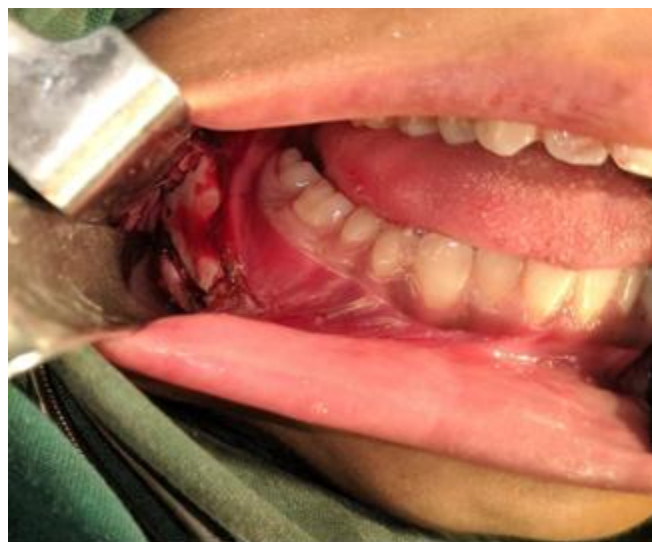

Figure 4: Incision Placed And Mandibular Angle Exposed

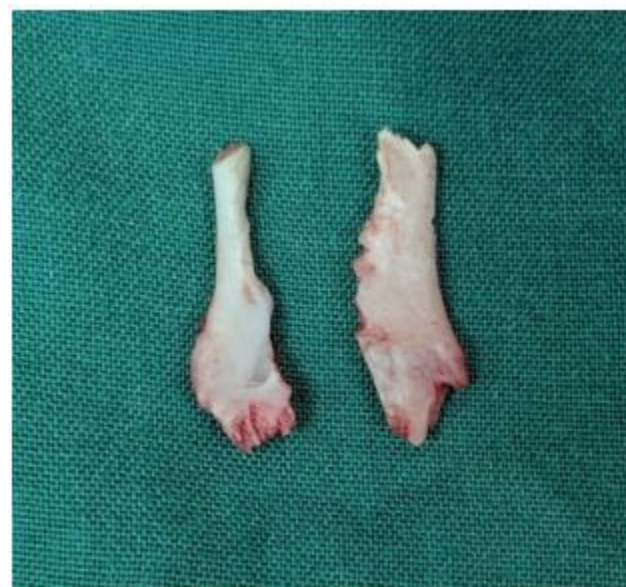

Figure 5: Removal of Excessive Bont Spruts At Right Mandibular Angle

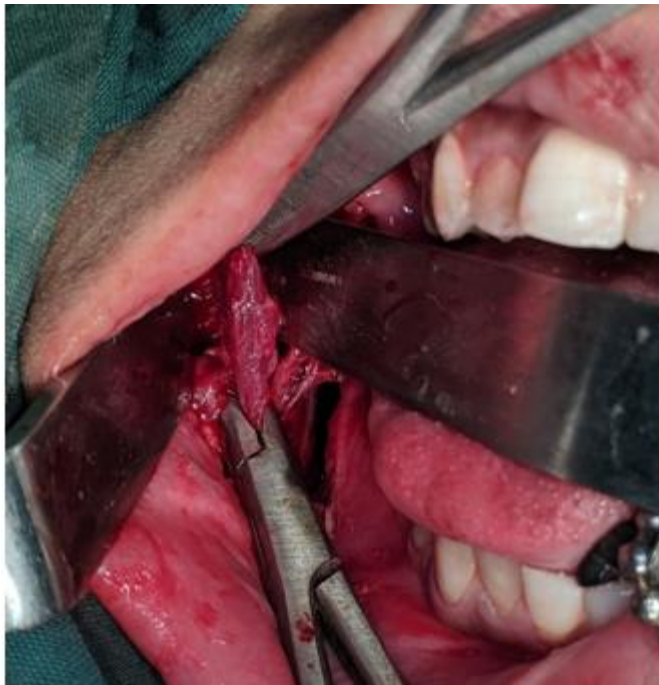


Figure 6: Masseter Muscle Clamped With Hemostat

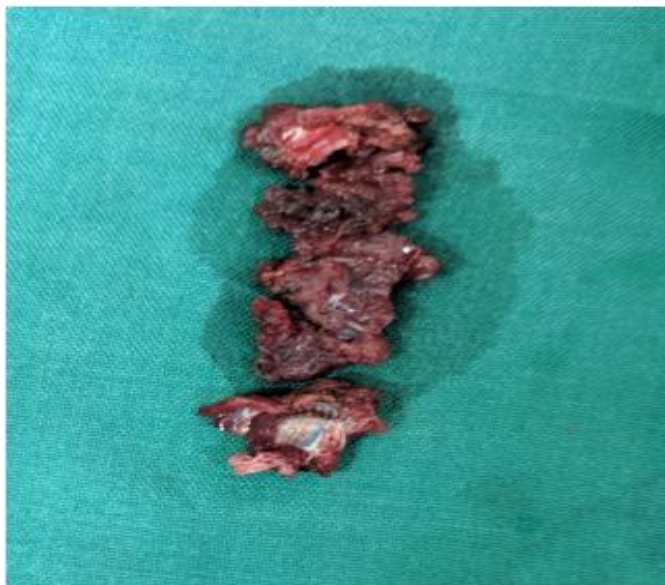


Figure 7: Deep And Middle Fibres Of Masseter Muscle  
Excised