

Interdisciplinary approach to improve esthetics - A Case Report

¹Dr. Dibya Deepika Mohapatra, PGT, Department of Prosthodontics and crown & bridge, Kalinga Institute of Dental Sciences, KIIT Deemed to be University.

²Dr. Sonali Perti, Professor, Department of Prosthodontics and crown & bridge, Kalinga Institute of Dental Sciences, KIIT Deemed to be University.

³Dr. Subhalaxmi Baral, PGT, Department of Periodontics & Oral Implantology, Kalinga Institute of Dental Sciences, KIIT Deemed to be University.

⁴Dr. Solanki Bhavini, PGT, Department of Prosthodontics and crown & bridge, Kalinga Institute of Dental Sciences, KIIT Deemed to be University.

⁵Dr. Pritam Das, PGT, Department of Prosthodontics and crown & bridge, Kalinga Institute of Dental Sciences, KIIT Deemed to be University.

Corresponding Author: Dr. Dibya Deepika Mohapatra, PGT, Department of Prosthodontics and crown & bridge, Kalinga Institute of Dental Sciences, KIIT Deemed to be University.

Citation of this Article: Dr. Dibya Deepika Mohapatra, Dr. Sonali Perti, Dr. Subhalaxmi Baral, Dr. Solanki Bhavini, Dr. Pritam Das, “Interdisciplinary approach to improve esthetics - A Case Report”, IJDSIR- February - 2023, Volume – 6, Issue - 1, P. No. 59 – 64.

Copyright: © 2023, Dr. Dibya Deepika Mohapatra, et al. This is an open access journal and article distributed under the terms of the creative commons’ attribution non-commercial License. Which allows others to remix, tweak, and build upon the work non-commercially, as long as appropriate credit is given and the new creations are licensed under the identical terms.

Type of Publication: Case Report

Conflicts of Interest: Nil

Abstract

Maxillary midline diastema is a common Esthetic problem requiring treatment. This case presentation shows the treatment of a patient with a midline diastema using combination of both frenectomy procedure and fixed prosthesis. A 28-year-old female patient, whose chief complaint was a unpleasant, unesthetic smile due to fractured anterior restoration and midline diastema. For the closure of midline diastema, here we use frenectomy followed by replacement of old prosthesis with all ceramic restoration to improve esthetics.

Keywords: Midline diastema, Frenectomy, All ceramic restoration, CAD-CAM, Anterior Esthetics.

Introduction

Patients' primary concerns are with aesthetics because it significantly affects their sense of self-worth. For aesthetic reasons dentistry is in high demand because people want their teeth to look like natural teeth. The diastema between the maxillary central incisors is seen as an aesthetic issue. It might result from a wide dental arch, congenital tooth absence, abnormal tooth size, and/or labial frenum hypertrophy, but the cause of

midline diastema has generated debate over the years. The aberrant frenum is one of the most common etiological causes of midline diastema. There are various treatment options are available for correction of unpleasant smile due to midline diastema including surgical, orthodontic, and restorative procedures¹.

This case report focuses on rehabilitation of a patient with unpleasant smile with frenectomy followed by restoration of maxillary incisors.

Case report

A female patient aged 28 years reported to the Department of Prosthodontics at Kalinga Institute of Dental Sciences, with chief complaint of unpleasant, unesthetic smile due to fractured anterior restoration and midline diastema (fig-1). The past dental history revealed endodontically treated followed by PFM crowns in maxillary incisors 4 years back. The intraoral examination revealed the presence of high frenal attachment (fig-2) and midline spacing between maxillary central incisors which was nearly 4mm. Keeping the clinical findings in mind, the treatment plan included frenectomy, removal of faulty crowns followed by all ceramic restoration in the upper four anterior teeth. Frenectomy was carried out in the department of Periodontology, Kalinga Institute of Dental Sciences (fig-3). The faulty metal ceramic crowns were removed and a diagnostic maxillary and mandibular impression were made. A diagnostic mounting was done and wax mock-up was planned.

All the incisors were prepared with an equigingival deep chamfer finish line (Fig-4). Mechanical gingival retraction was done with a knitted cord impregnated with 23% aluminium chloride. Final impression was made using poly vinyl siloxane impression material by the two-stage double-mix technique.

Final impression was poured in type IV Gypsum. With the help of Putty index provisional restorations was fabricated by indirect technique by using temporary resin cement (Protemp).

Patient's perception about her facial appearance and smile was considered before cementation of the provisional restoration (Fig-5). Any change in shape and position of the four maxillary anteriors was done as per patients desire and this outcome was shown to the patient and her approval was taken for replicate in final restoration. Porcelain lithium disilicate restorations for full coverage crowns were fabricated by the CAD/CAM technique and using the correct shade guide (Fig-6). The bisque trial of restorations was done for checking the shade, fit, marginal adaptation, shape, size, symmetry, contacts, and the amount of visibility of the restoration at rest position and when the patient smiles (fig. 7). The final glazing was carried out. To prevent improper placement, the restorations were positioned at the luting appointment to indicate the position of the tooth in the arch. Dual cure luting agent fluoride releasing self-adhesive resin cement (Beauticem SA) was used for luting.

The lithium disilicate restorations were etched with 10% hydrofluoric acid for 20 seconds. They were properly cleansed with plenty of water after being etched. After drying, a coat of silane coupling agent was applied for 60 seconds. The prepared teeth were etched using 37% hydrochloric acid for 15 seconds and they were washed and air-dried. Then bonding agent was applied and light cured for 10 seconds on all prepared teeth. The restorations were spot cured for 5 seconds initially. Excess cement was removed with explorer and then complete curing was done for 20 seconds. The patient was satisfied and happy with her new smile (Fig- 8, 9).



Fig.1: Pre-Operative Extra Oral Photograph.

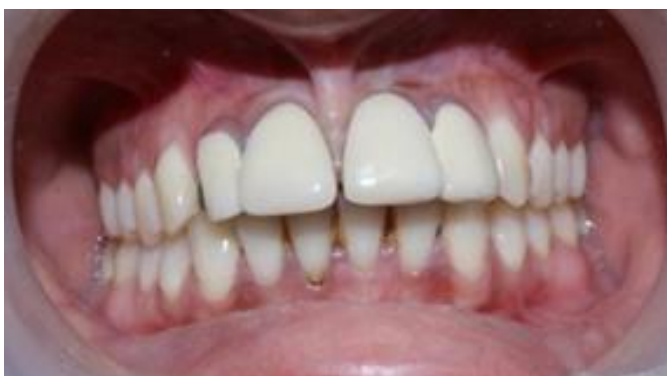

Fig 2: Pre-Operative Intra Oral Photograph.

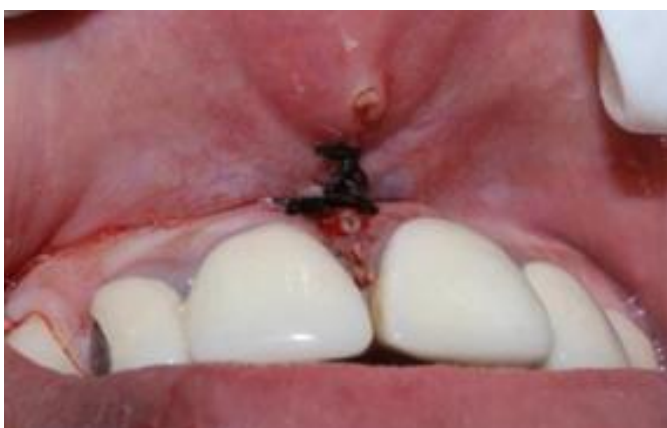

Fig.3: Frenectomy

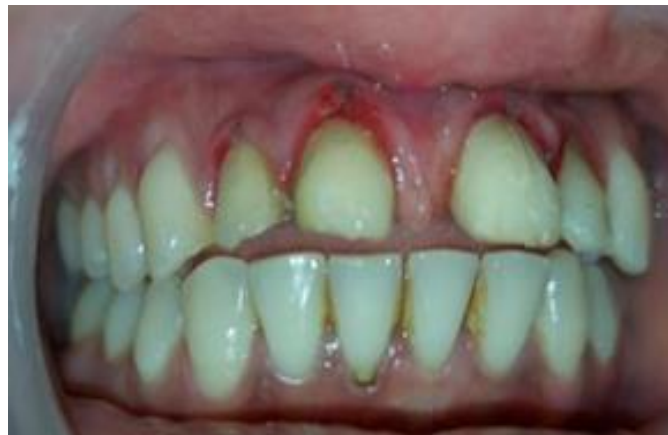

Fig.4: Teeth Preparation

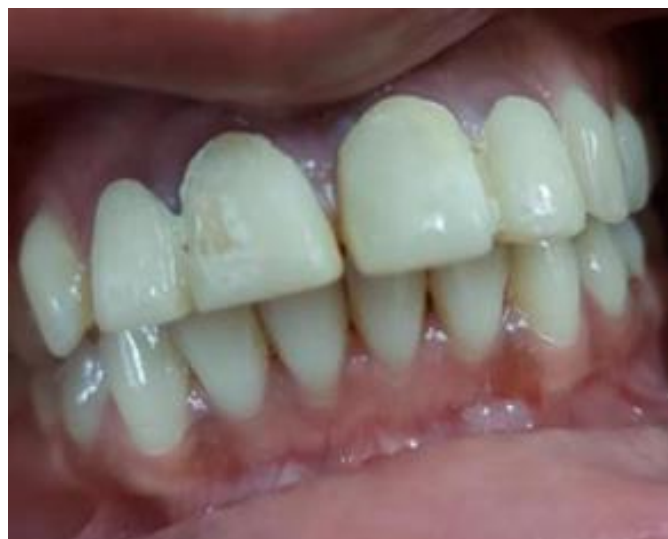

Fig.5: Temporization

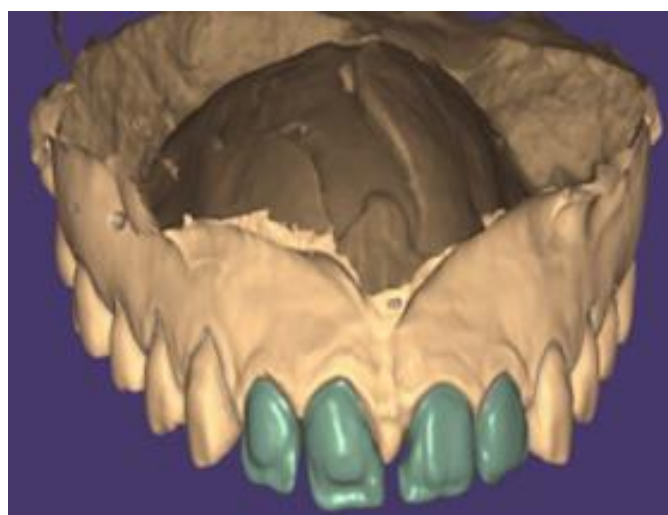


Fig.6: CAD/CAM Photo.

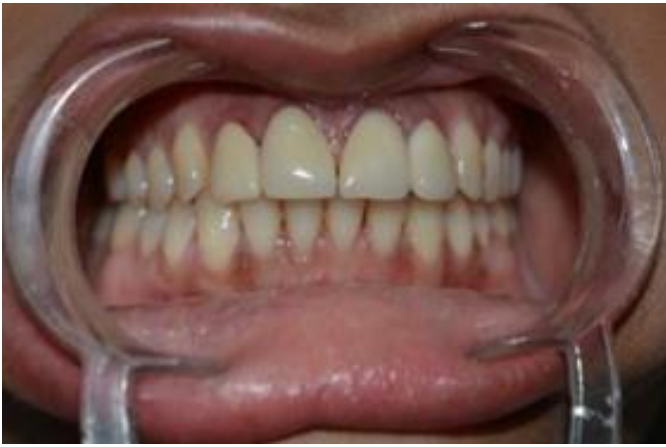

Fig.7: Bisque Trial

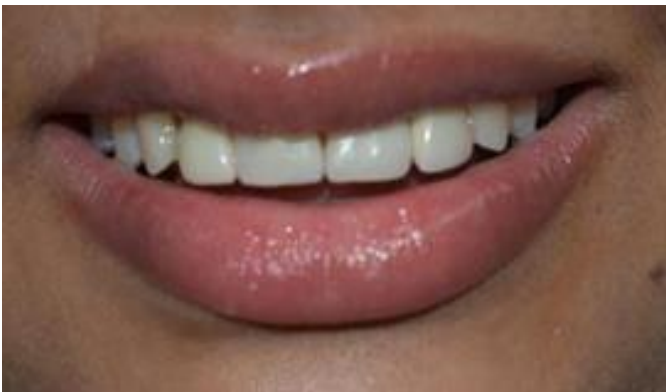

Fig.8: Final Prosthesis



Fig.9: Esthetic Smile.

Discussion

Nowadays, a progressive demand of patients for a high level of Esthetic treatments is observed on clinical routinely. Frenum should be correctly assessed during oral examination to avoid misdiagnosis of normal variations as abnormal frenum and to correctly diagnose the etiological factors behind a malformed labial frenum in order to proceed with best possible treatment. Its relevance in smile esthetics and being one of the leading causes of diastema further makes it important to properly identify the frenum before choosing any other treatment modalities. Bergstrom et al studied patients with maxillary midline frenums and stated that there was a statistically significant decrease in the distance between central teeth after frenectomy². Tanık A, Çiçek Y et al stated that the removal of abnormal frenums with frenectomy can contribute to the reduction in the distance between the teeth. In addition, frenectomy increases the amount of gingiva and decreases the depth of the pocket, gingival recession, amount of plaque, and bleeding³. In this present case, clinical examination showed high frenum attachment hence frenectomy was planned.

Although metal ceramic restorations gained popularity for their predictable performance and reasonable esthetics for more than three decades, the demand for improved esthetics has led to introduction of all ceramic restorations (Kelley, 2011; Hatai, 2014)⁴.

Thus, metal-free ceramic prosthesis replacing the metal ceramic fixed prosthesis have become a bio mechanical and aesthetically viable option in view of biologic, physical, and Esthetic properties. Since its identification by the German chemist Klaproth, zirconia based all ceramic restorations have found place in both single crowns and short span anterior fixed partial dentures. Zirconia or yttrium oxide partially stabilized zirconia

(3Y TZP) is a crystalline dioxide of zirconium. Zirconia-based dental ceramics are stronger than conventional glass-ceramic restorations and have excellent mechanical strength properties⁵. However, a zirconia core is opaque and lacks translucency. For this reason, IPS Emax Ceram was used over the zirconia copings to improve the Esthetic appearance. This system consists of a nano fluorapatite glass ceramic distinguished from all previous ceramic systems by specific features, such as improved translucency and unique opalescent shades that are achieved with the help of opacifiers and ion colouring, while also providing high strength⁶. The use of such all ceramic systems has become increasingly common in the clinical practice, to come across patients who are in search of cosmetic procedures since the presence of an aesthetically pleasing smile directly affects the individual's social life. These restorations have potential to replicate the life like appearance of the natural dentition. Understanding patient's perception to the Esthetic criteria is very important during treatment planning for a restoration in Esthetic zone area. Tjan et al stated that beauty is usually expressed by social elements and personal choice⁷. Jannike et al interviewed 78 patients about Esthetic features of their face and smile. They found that patients' opinions of their own smiles were significantly higher than the dentist's assessments, and dentists should be aware of patient's perception to their smile⁸. Tortopidis et al found that the relative difference between patient's perception and professional assessment of Esthetic treatment need the importance of communication between dentist and patient in the Esthetic dental treatment planning process⁹. The appealing smile is a perfect harmonization between facial and dental elements. The facial elements include the hard and soft tissues of the face. The dental elements are related more specifically to dentitions

themselves and their relationship with gingiva. For evaluation of the perception of smile, criteria used in this study were uniformity of dental versus facial midline, size and shape of maxillary anterior teeth, shape of face and its relation to personality of an individual, color of teeth, lip position and subsequent display of soft tissue and teeth in the maxillary anterior region, and position of the gingival zenith of the six maxillary anterior teeth.

Conclusion

All-ceramic restorations along with frenectomy were employed to optimally rejuvenate an unesthetic smile. The patient was more confident with the aesthetically pleasing outcome and did not experience any phonetic problems resulting from the correction of the tooth alignment. The new smile of the patient was satisfactory with excellent Esthetic appearance. Detailed planning, correct selection of dental materials, and quality communication with the prosthetic technician contributed to a harmonious smile and the evident satisfaction of both patient and dental professionals.

References

1. Koora K, Muthu MS, Rathna PV. Spontaneous closure of midline diastema following frenectomy. Journal of Indian Society of Pedodontics and Preventive Dentistry. 2007 Jan 1; 25(1):23.
2. Bergstrom K, Jensen R, Mårtensson B. The effect of superior labial frenectomy in cases with midline diastema. American journal of orthodontics. 1973 Jun 1; 63(6):633-8.
3. Tanik A, Cicek Y. Evaluation of the distance between the central teeth after frenectomy: a randomized clinical study. European Oral Research. 2021 May 1; 55(2):99-103.
4. Kelly JR, Benetti P. Ceramic materials in dentistry: historical evolution and current practice. Australian dental journal. 2011 Jun; 56:84-96.

5. Dudhekar AU, Nimonkar SV, Belkhode VM, Borle A, Bhola R. Enhancing the esthetics with all-ceramic prosthesis. *Journal of Datta Meghe Institute of Medical Sciences University*. 2018 Jul 1;13(3):155.
6. Vichi A, Louca C, Corciolani G, Ferrari M. Color related to ceramic and zirconia restorations: a review. *Dental materials*. 2011 Jan 1; 27(1):97-108.
7. Tjan AH, Miller GD. Some Esthetic factors in a smile. *The Journal of prosthetic dentistry*. 1984 Jan 1; 51(1):24-8.
8. Jørnung J, Fardal Ø. Perceptions of patients' smiles: a comparison of patients' and dentists' opinions. *The Journal of the American Dental Association*. 2007 Dec 1; 138(12):1544-53.
9. Tortopidis D, Hatzikyriakos A, Kokoti M, Menexes G, Tsiggos N. Evaluation of the relationship between subjects' perception and professional assessment of Esthetic treatment needs. *Journal of Esthetic and Restorative Dentistry*. 2007 Jun; 19(3):154-62.
10. Anari S. Aesthetic dentistry: Changing public perceptions. *Br Dent J*. 2017 Sep 22;223(6):390. doi: 10.1038/sj.bdj.2017.791. PMID: 28937114.