

Clinical management of aberrant canal anatomy in Mandibular 1st molar

¹Dr. Anita J. Kale, ²Dr. Vaishali R. Wankhede, ³Dr. Sunanda L. Gaddalay, ⁴Dr. Ramchandra Kabir, ⁵Dr. Amol Badgire, ⁶Dr. Pravin Dhore

Corresponding Author: Dr. Vaishali R. Wankhede

Citation of this Article: Dr. Anita J. Kale, Dr. Vaishali R. Wankhede, Dr. Sunanda L. Gaddalay, Dr. Ramchandra Kabir, Dr. Amol Badgire, Dr. Pravin Dhore, “Clinical management of aberrant canal anatomy in Mandibular 1st molar”, IJDSIR- January - 2023, Volume –6, Issue - 1, P. No.104– 107.

Copyright: © 2023, Dr. Vaishali Wankhede, et al. This is an open access journal and article distributed under the terms of the creative commons’ attribution non-commercial License. Which allows others to remix, tweak, and build upon the work non-commercially, as long as appropriate credit is given and the new creations are licensed under the identical terms.

Type of Publication: Case Report

Conflicts of Interest: Nil

Abstract

Mandibular molars are frequently affected by dental caries. They exhibit variation in their internal anatomy, thus mandatory to understand in detail about their complex anatomy. Middle mesial canal is the third canal located between mesiolingual and mesiobuccal. Its detection and negotiation is an important practical issue in endodontics. Accordingly, the uses of magnifying aids are indicated to enhance the long-term favourable outcome of endodontic treatment. This case series defines two cases encountered for endodontic management during routine endodontic procedure.

Keywords: Mandibular First Molar, Middle Mesial Canal, Root Canal Treatment.

Introduction

Successful root canal therapy can be attained by accomplishing complete negotiating, shaping, cleaning and obturation to the entire root canal space.¹ The chamber of pulp should be uncontaminated and obturated with the help of inert obturating material for

the successful result of endodontic therapy. Thus, the main objective of endodontic therapy is to obtain and maintain the hermetic seal of the root canal space. For clinicians, the biggest challenges are to face the complexity of the root canal morphology. Thus, in-depth knowledge of the pulp chamber is required.²

In literature, it is mentioned that there are many studies that were carried out to study the mandibular molars morphology, still there is limited facts about internal anatomy of middle mesial canal.³ The variations are as follows; a C-shaped root canal anatomy, radix entamolaris, isthmus (ribbon-shaped communication) between mesiolingual and mesiobuccal canal and third canal (middle mesial canal) first mentioned by Vertucci.⁴ As per reports of different studies, the prevalence of middle mesial canal was shown to have a range between 0-46%.³

An identification of the topographic location of the additional canals is the matter of prime importance for the dentists. To detect and treat the entire root canal

space, it is extremely important to use all armamentarium by the dentist. Additional diagnostic aids like CBCT, magnifying loupes, micro-CT, dental operating microscope and so forth can also be use to locate and negotiate the middle mesial canal.⁵ The following reports describe the successful endodontic treatment of three mandibular first molars having middle mesial canal.

Case Report 1

A 35-year-old female patient presented with a history of pain since 7 months in the lower left molar area. The mandibular left first molar was tender on vertical percussion. A radiograph revealed a deep carious lesion in mesial proximal area approaching the pulp space and periodontal ligament widening was seen in apical region of mesial and distal root. A diagnosis of chronic irreversible pulpitis was made for the mandibular left first molar #36 and root canal therapy was planned. Local anaesthesia (2% lidocaine with 1:80,000 adrenaline) was administered. Under rubber dam, all carious tissue was removed. An adequate access cavity was prepared under a 3.5X magnifying loupe. Using a DG16 Endodontic explorer (Hu-Friedy, USA), the extra middle mesial canal was located. The working length was determined by an apex locator (Denta Port; J.Morita Mfg. Corp, Kyoto, Japan). All canals were cleaned with Protaper next NiTi rotary instruments (Dentsply-Maillefer, Ballaigues, Switzerland).

Irrigation with 3% sodium hypochlorite, 17% EDTA (Prime Dental Products Pvt Ltd, Mumbai India) and saline was performed. Canals were dried with sterile paper point and temporized with calcium hydroxide (Pulp dent, USA). At the second appointment after a week, tooth was asymptomatic. All the canals were irrigated, dried with paper points and master-cone radiograph was taken. The canals were obturated with

cold lateral condensation of gutta-percha using resin sealer (Dentsply Tulsa). A post operative radiograph was taken showing the confluent type, and during the follow-up period patient was asymptomatic.

Discussion

Proper knowledge of root canal anatomy variations helps in the success of multi-step process i.e. root canal treatment. Missing canals is one of the most common reasons for the root canal failure.³ Unprepared and unrevealed portion of root canal might contain bacteria which lead to unhealed periapical lesions and chronic symptoms.¹ As per previous studies missing canal decreases the long-term success of the endodontic treatment.⁴ Due to missed canal there were 42% of fail endodontic cases. In north India, presence of MM canal is quite high.⁶

In younger patients the incidence of middle mesial canal is higher as compared to old aged patients. Patients who are less than 20 years showed 32.1% incidence of negotiating canals.⁴ Pomeran et al. classified MM canal into 3 configurations: fine, confluent and independent.⁷

(i) Fin: in between main canal (mesiobuccal or mesiolingual) and middle mesial canal file passes freely, (ii) confluent: MM canal joins mesiolingual or mesiobuccal canal apical but originates separately, and (iii) independent: MM canal originates and terminates separately.

Fabra et al. observed that percentage of presence of three canals in mesial root canal of molars is 2.6%, in apical third 1.7% of extra canal (middle mesial) canal joined mesiobuccal canal, and 0.13% are independent canal, and converged with mesiolingual canal by 1.6%.⁸ MM canal may be present deep into isthmus and have small orifices, thus need troughing to widen isthmus along with developmental grooves exploration which increases the chances of canal detection. It has been observed that

in mandibular first molar, after troughing incidence of presence of extra canal increases by 12.4%. Troughing is not required more than 2mm.² Sometimes the MM canal orifices are located at the centre of mesiolingual and mesiobuccal canal and generally, the orifices is located more towards the mesiolingual canal.⁶

Missed canal anatomy prevention can be done with good preoperative radiographs. Radiographs with two different angles with cautious interpretation can help in detection of hidden canals.⁵ Champagne bubble test, use of different dyes, bleeding spots in chamber and pulpal floor inspected with explorer are some conventional techniques for the noticing of root canal orifices when there is no magnification aid available.⁴

Loupes and dental operating microscope provide excellent illumination and magnification which improves the visualization of canal orifices in the operating field.⁴ In the presented case series, we were equipped with magnification device, magnifying loupes which helped in managing the cases. Dental operating microscope, 3- dimensional radiographic technique is a major boom in locating the extra or missed canals. Micro-CT shows its high definition and accurate details of scans.⁶ Acar et al. compared micro-CT and CBCT to detect accessory canals and stated that the micro-CT shows the high resolution and details than CBCT.⁹ Morphology of endodontic system is quite complicated, thus a better understanding of root canal anatomy is essential. A thorough knowledge of complex anatomy would be more useful to detect the extra canal orifices using magnification.¹⁰

Conclusion

The significance of looking for middle mesial canal is a high clinical relevance, though it has low incidence. The additional third canal (middle mesial canal) is located between the mesio-lingual and mesio-buccal root canal

of mandibular first molars. The user of periapical radiographs in two different horizontal projections and modified endodontic access, use of magnification aids are advisable to amplify the long-term favourable end result of the endodontic treatment.

References

1. Wang L, Hong L. Clinical management of mandibular second molar with three mesial canals: A case study. AJCRMH 2018;1(1):1-7
2. Chavda SM, Garg SA. Advanced methods for identification of middle mesial canal in mandibular molar: An in vitro study. Endodontology. 2016; 28:92-6.
3. Alashiry MK, Zeitoun R, Elashiry MM. Prevalance of middle mesial and middle distal cnals in mandibular molars in an Egyptian sub population using microcomputed tomography. Niger J Clin Pract. 2020; 23:534-8.
4. Penukonda R, Saraf PA, Patil TN, Vanaki SS. A clinical approach to the successful management of variations of middle mesial canals: A case series. Saudi Endod J 2018; 8:139-43.
5. Mittal R, Singh R, Thareja P. A rare case of three mesial and two distal independent canals in mandibular first molar. Ann Prosthodont Restor Dent 2016;2(2):42-45.
6. Sherwani OA, Kumar A, Tiwari RK, Mishra SK, Andrabi SM, Alam S. Frequency of middle mesial canals in mandibular first molars in North Indian population- An in vitro study. Saudi Endod J 2016; 6:66-70.
7. Pomeranz HH, Eidelman DL, Goldberg MG. Treatment considerations of middle mesial canal of mandibular first and second molars. J Endod 1981; 7:565- 568.

8. Fabra-Canpos H. Three canals in mesial root of mandibular molar: a clinical study. *Int. Endod J.*1989; 22:39-43.
9. Acar B, Kamburoglu K, Tatar I, Arik an V, Celik HH, Yuksel S, ET AL. Comparison of micro-computerized tomography and cone-beam computerized tomography in the detection of accessory canals in primary molars. *Imaging Sci Dent* 2015;45(4):205-211.
10. Karapinar-Kazandag M, Basrani BR, Friedman S. The operating microscope enhances detection and negotiation of accessory canals in mandibular molars. *J Endod*, 2010;36(8):1289-1294.

Legend Figures

Figure 1: Preoperative radiograph

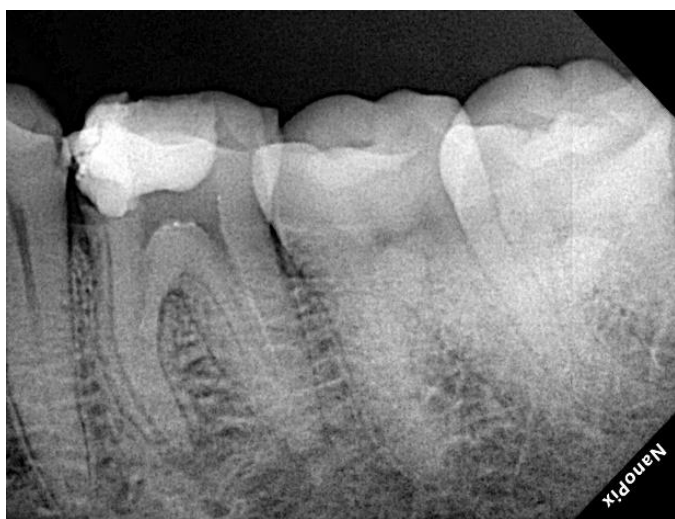

Figure 2: Master cone radiograph.

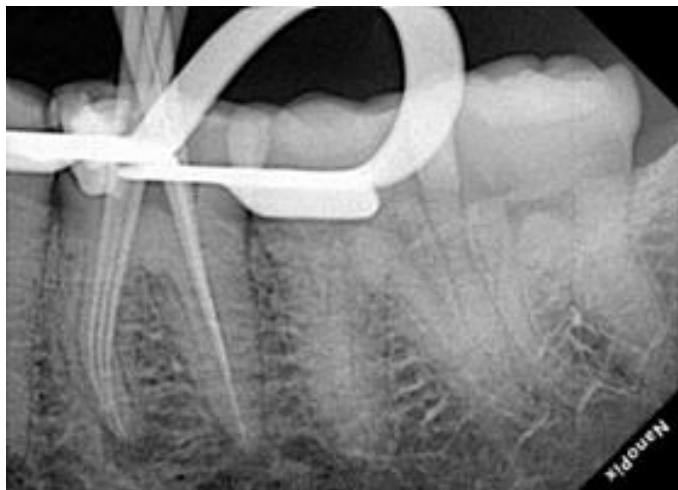


Figure 3: Working length radiograph.

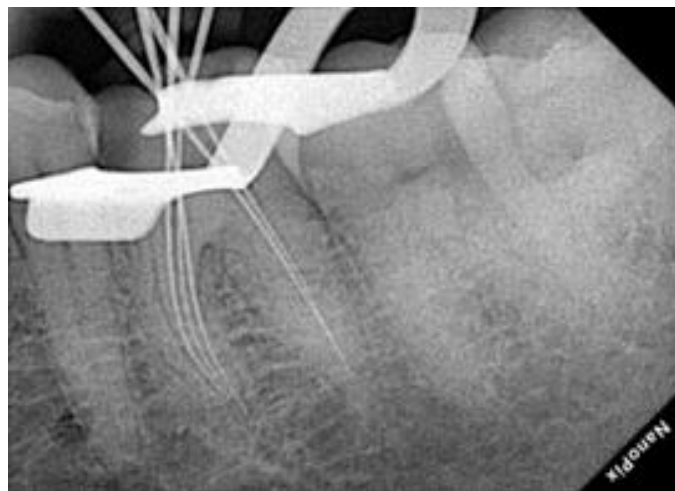


Figure 4: Post obturation radiograph.

