

**Determination of gender by jug handle radiograph – A Retrospective Study**<sup>1</sup>Dr. Navreet Kaur, BDS, Dasmesh Institute of Research and Dental Sciences, Faridkot, India**Corresponding Author:** Dr. Navreet Kaur, BDS, Dasmesh Institute of Research and Dental Sciences, Faridkot, India**Citation of this Article:** Dr. Navreet Kaur, “Determination of gender by jug handle radiograph – A Retrospective Study”, IJDSIR- October - 2022, Vol. – 5, Issue - 5, P. No. 74 – 79.**Copyright:** © 2022, Dr. Navreet Kaur, et al. This is an open access journal and article distributed under the terms of the creative commons attribution non-commercial License. Which allows others to remix, tweak, and build upon the work non-commercially, as long as appropriate credit is given and the new creations are licensed under the identical terms.**Type of Publication:** Original Research Article**Conflicts of Interest:** Nil**Abstract****Background:** Present study used the alternate methods for gender estimation by using measurements of denser areas of such unknown skull especially measure bizygomatic and intervault distance.**Aim:** To assess the efficacy and reliability of jug handle view radiographs in gender determination**Settings and Design:** Eighty individuals (40 males and 40 females) between age group of 20 to 40 years were included in the study. Bizygomatic and inter vault distances were measured, and the results obtained were later subjected to statistical evaluation.**Materials and Methods:** Jug handle radiograph was taken by Kodak8000C digital panoramic and cephalometric machine (70kVp and 6.3 mA). Using the Universal Desktop Ruler software bizygomatic and inter vault distances were measured and expressed in linear millimetres.**Statistical Analysis:** The statistical analysis was done using the Statistical Package for the Social Sciences (SPSS) version 23 IBM Corporations statistical analysis software and independent Student's *t*-test was used.**Results:** The average bizygomatic distance of male was 72.91 and for female was 64.66, and intervault distance for male was 65.45 and for female was 60.29, which was found to be statistically significant.**Conclusion:** Males have more bizygomatic distance and intervault distance. Also, bizygomatic distance gave better result as compare to intervault distance.**Keywords:** Craniometric, bizygomatic distance, forensic anthropology, intervault distance, zygomatic arches.**Introduction**

Human identification is important for legal as well as for humanitarian purpose. Gender determination is one of the major parameter used for an identification of an individual. Correct gender determination regulates the pool of missing persons to just one half of the population. As radiographs are able to capture their distinct anatomical features, they become an invaluable tool in identification<sup>[1]</sup>.

Sex determination is a major challenge for forensic anthropologist in the medico-legal context. It constitutes initial step in personal identification from skeletal remains and is indispensable further to define age and stature of the deceased. There have been several studies

on sex determination from different skeletal parts using osteometric and morphological approaches. Degree of sexual dimorphism and osteological standards vary across time and space<sup>[2]</sup>.

The pelvis is the best skeletal indicator for any sex determination, while the skull is the second best indicator due to its better preservation. Sexual dimorphism of an individual can be identified accurately in 80% of cases using skull alone and in 98% cases using pelvis and skull together<sup>[3]</sup>.

Gender determination by radiographs has long been in use and the technique is efficient, comparatively easy, records can be obtained in both living and dead, and is economical than DNA technology. So, expertise knowledge and proper application of maxillofacial radiological techniques has a valuable role in forensic identification and solving medico-legal cases<sup>[4]</sup>.

Among the various skull radiographs, jug handle radiograph, which is a modification of the submentovertex view, provides the best view of zygomatic arches and vault area. Hence the present study has been undertaken to assess the efficacy and reliability of bizygomatic and intervault distance for gender determination using jug handle via radiographs.

## Materials and Methods

The study group was selected from the routine dental OPD.

### Inclusion criteria

- Jug handle radiograph showing bilateral presence of zygomatic arch and vault area.

## Results

Table: 1: Predicted Gender						
	Gender	N	Mean	Standard deviation	T	P
Bizygomatic distance	Males	40	72.91	3.15	8.2500	0.001
	Females	40	64.66	3.25		

- Subjects with normal growth, development and dental conditions.
- Radiographs of diagnostic quality.

### Exclusion criteria

- Developmental anomalies of the facial bones.
- Previous history of any surgery or trauma.
- Presence of any pathologies.

Eighty individuals (40 males and 40 females), between age group of 20 and 40 years were included in the study. The ethical clearance was taken before performing the study and a written consent in patient's own language were taken for every subject after explaining the nature of the study. Jug handle radiograph was taken by Kodak8000C digital panoramic and cephalometric machine (70kVp and 6.3 mA).

The head of the subject was centred on the receptor and tipped back as far as possible so that the vertex of the skull touches the cassette. The midsagittal plane was kept perpendicular to the plane of the film and the radiographic baseline parallel to the film. Exposure was made under adequate radiation protection measures. Using the Universal Desktop Ruler software bizygomatic and inter vault distances were measured and expressed in linear millimetres. The obtained results were later subjected to statistical evaluation (independent Student's *t*-test).

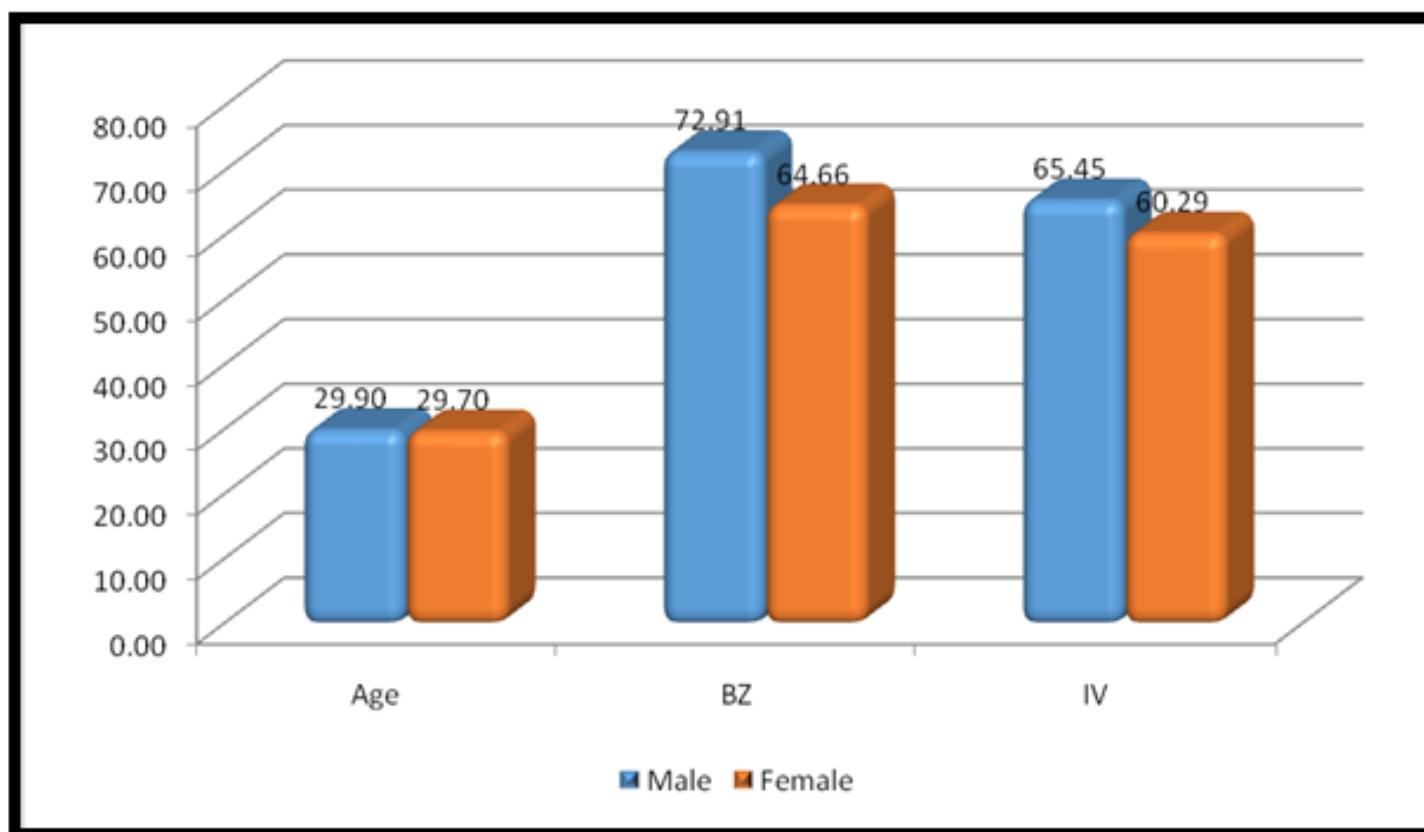
The statistical analysis was done using the Statistical Package for the Social Sciences (SPSS) version 23 IBM Corporations statistical analysis software and independent Student's *t*-test was used for statistical evaluation.

Intervault distance	Males	40	65.45	2.66	5.1600	0.001
	Females	40	60.29	2.07		

The mean value of bizygomatic distance for male was  $72.91 \pm 3.15$  and for female was  $64.66 \pm 3.25$  along with p value  $<0.001$  and t value of 8.25. For inter vault distance the mean value for male was  $65.45 \pm 2.66$  and

for female was  $60.29 \pm 2.07$ , with t value 5.16 and p value  $< 0.001$ , which was found to be statistically significant for both the dimensions. (Table 1)

Graph 1: Comparison of bizygomatic & intervault distance in male & female



Bar diagram 1 shows the comparison of bizygomatic distance and intervault distance between males (n=40) and females (n=40), and also the mean age of the both genders.

Table 2: Multivariate analysis for gender determination using bizygomatic distance

	Regression analysis (r)	Std. error of the estimate	t	P value	Significance
Bizygomatic distance	0.794	0.3080	14.776	0.001	Significance

Table 2 depicts that multivariate regression analysis test was performed for checking reliability of gender determination using bizygomatic distance, which shows that regression analysis using bizygomatic distance for

gender estimation was 79% with a standard error of 0.3080 and t value was 14.776, which was found to be statistically significant at  $p=0.001$

Table 3: Multivariate Analysis for Gender Determination Using Intervault Distance

	Regression analysis (r)	Std. error of the estimate	t	P value	Significance
Intervault distance	0.739	0.3412	11.849	0.001	Significance

Table 3 depicts that multivariate regression analysis test was performed for checking reliability of gender determination using intervault distance, which shows that regression analysis using intervault distance for

gender estimation was 73% with a standard error of 0.3412 and t value was 11.849, which was found to be statistically significant at  $p=0.001$

Table 4: Multivariate Analysis for Gender Determination Using Both Bizygomatic & Intervault Distance

	Regression analysis (r)	Std. error of the estimate	t	P value	Significance
Bizygomatic & Intervault distance	0.833	0.2822	14.559	0.001	Significance

Table 4 depicts that multivariate regression analysis test was used for analyzing reliability of both parameters i.e., bizygomatic & intervault distance for gender determination was 83% accurate with a standard error of 0.282 and t value was 14.559, which was found to be statistically significant at  $p=0.001$

years, and jug handle radiographs were taken for determination of sexual identification through bizygomatic and intervault distance. Data obtained was subjected to statistical analysis and it was observed that bizygomatic distance for male was  $72.91 \pm 3.15$  and for female was  $64.66 \pm 3.25$  along with p value  $<0.001$  and t value of 8.25, stating that males have more bizygomatic distance than female. For inter vault distance the mean value for male was  $65.45 \pm 2.66$  and for female was  $60.29 \pm 2.07$ , with t value 5.16 and p value  $< 0.001$ , again stating that males have more intervault distance than females.

## Discussion

The main motto of forensic sciences is human identification, defined as “individualisation by attribution of birth name or other appropriate name to human remains”. Forensic dentists along with forensic anthropologists analyse the calcified structures of the body like bones and teeth. This aids in determining the race and gender (sexual dimorphism) of the deceased persons<sup>[5,6]</sup>.

Accurate determination of sex from the human skulls of great importance in anthropologic and forensic investigations<sup>6</sup>. The pelvis and the skull are the most reliable bones for sex determination<sup>[7]</sup>. Dentofacial radiography also aids in the field of forensic odontology. Comparison of ante mortem and postmortem radiographs is one of the cornerstones of positive identification of human remains<sup>[8]</sup>.

In the present study, 80 subjects were selected (40 males and 40 females), with age criteria between 20 and 40

However, in the study conducted by Jehan et al<sup>[9]</sup>, on 191 subjects, including 106 males and 85 females, using computed tomography of head and paranasal sinus. Bizygomatic distance, AP diameter and width of the maxillary sinus and intermaxillary distance was calculated to determine sexual dimorphism. Statistically significant difference with  $P < 0.0001$  was observed in the bizygomatic distance with mean  $\pm$  SD of  $9.55 \pm 0.41$  cm for male and  $9.262 \pm 0.52$  for female.

Moreover study conducted by Mahakkanukrauh et al<sup>[10]</sup> took 200 Thai dried skulls (100 males and 100 females) of known gender, with the mean age of 65.65 years for males and 66.81 years for females. A total of

25 standard cranial measurements were examined on the samples, with result giving 90.6% accuracy (91.1% in male and 90.0% in female) which can provide valuable application when used in sex determination from skull in a Thai population.

Another study conducted by Saini R & Saini V<sup>[11]</sup> on 483 crania (316 male and 167 females) with age range of 18-70 years of North Indian origin were studied using twenty one traditional variables were measured. The *p* - value shows that all parameters were statistically significant and higher in males. The best parameters are bizygomatic breadth (BZBr) and mastoid bregma height (MBrHt) which were reflected by highest *t* values and highest classification accuracies i.e. 82.2 and 80.5% respectively.

The study conducted by Chandra S et al, on 60 individuals (30 males and 30 females) between age group of 18 to 25 years. Jug handle radiographs were taken under standardized manner. Bizygomatic and inter vault distances were measured. The average bizygomatic distance of male was found to be 72.594 and for female was 65.3583, and inter vault distance for male was 63.8693 and for female was 59.664, which was found to be statistically significant. Concluded that observed that males have more bizygomatic distance and inter vault distance when compared to females.

### Conclusion

Based on the observations from the present study we can conclude that bizygomatic distance and inter vault distance are useful and can aid in gender determination. However, bizygomatic distance is a more reliable parameter to determine gender as compare to inter vault distance. Further research should be aimed at, with a larger sample size to further acknowledge the accuracy of our observations.

### References

1. Singh J, Gupta KD, Malhotra G. Sex determination using cheiloscopy & mandibular canine index as a tool in forensic dentistry. J Forensic Dent Sci 2012; 4:70-4.
2. Saini R and Saini V (2016) Sexual Dimorphism of North Indian Crania and its Forensic Application. J For Med Leg Aff 1(2): 108.
3. Kavitha B, Einstein A, Sivapathasundharam B, Saraswathi TR. Limitations in forensic odontology. J Forensic Dent Sci 2009; 1:8-10.
4. Kumar R, Athota A, Rastogi T, Karumuri SK. Forensic radiology: An emerging tool in identification. J Indian Acad Oral Med Radiol 2015; 27:416-22.
5. Herschaft EE. Forensic dentistry. In: Neville BW, Damm DD, Allen CM, Bouquot JE, editors. Oral and Maxillofacial Pathology. 3rd ed. Saunders: Philadelphia; 2010. p. 887-916.
6. Fortes de Oliveira O, Lima Ribeiro Tinoco R, Daruge Júnior E, Silveira Dias Terada AS, Alves da Silva RH, Paranhos LR. Sexual dimorphism in Brazilian human skulls: Discriminant function analysis. J Forensic Odontostomatol 2012; 30:26-33.
7. Shiva Kumar B, Deepthi BC. A digital radiographic study for gender prediction using mandibular Indices. Int J Sci Res (IJSR) 2016; 5:1490-93.
8. Patil KR, Mody RN. Determination of sex by discriminant function analysis and stature by regression analysis: A lateral cephalometric study. Forensic Sci Int 2005; 147:175-80.
9. Jehan M, Bhadkaria V, Trivedi A, Sharma S K. Sexual Dimorphism of Bizygomatic distance & Maxillary sinus using CT Scan. IOSR Journal of Dental and Medical Sciences (IOSR-JDMS) e-ISSN:

2279-0853, p-ISSN: 2279-0861. Volume 13, Issue 3

Ver. II. (Mar. 2014), PP 91-95.

10. Mahakkanukrauh P, Sinthubua A, Prasitwattanaseree S, Ruengdit S, Singsuwan P, Praneatpolgrang S, Duangto P. Craniometric study for sex determination in a Thai population. *Anat Cell Biol* 2015; 48:275-283.
11. Saini R and Saini V (2016) Sexual Dimorphism of North Indian Crania and its Forensic Application. *J For Med Leg Aff* 1(2): 108.
12. Chandra S, Chaturvedi N, Sah K, Sinha S, Hamza A. Craniometric measurement by jug handle view: An aid for gender determination. *J Indian Acad Oral Med Radiol* 2018; 30:398-401.