

Releasing The Tongue Tie by Laser - A Case Report

¹Preeti Upadhyay, Professor, Department of Periodontology, Inderprastha Dental College & Hospital, Ghaziabad, Uttar Pradesh, India

²Vikram Blaggana, Head of the Department, Department of Periodontology, Inderprastha Dental College & Hospital, Ghaziabad, Uttar Pradesh, India

³Pragya Tripathi, Professor, Department of Periodontology, Inderprastha Dental College & Hospital, Ghaziabad, Uttar Pradesh, India

⁴Samistha Sinha, Post Graduate Student, Department of Periodontology, Inderprastha Dental College & Hospital, Ghaziabad, Uttar Pradesh, India

Corresponding Author: Dr. Preeti Upadhyay, Professor, Department of Periodontology, Inderprastha Dental College & Hospital, Sahibabad Industrial Area, Ghaziabad, Uttar Pradesh- 201010

Citation of this Article: Preeti Upadhyay, Vikram Blaggana, Pragya Tripathi, Samistha Sinha, “Releasing The Tongue Tie by Laser- A Case Report”, IJDSIR- September - 2022, Vol. – 5, Issue - 5, P. No. 15 – 19.

Copyright: © 2022, Dr. Preeti Upadhyay, et al. This is an open access journal and article distributed under the terms of the creative commons attribution non-commercial License. Which allows others to remix, tweak, and build upon the work non-commercially, as long as appropriate credit is given and the new creations are licensed under the identical terms.

Type of Publication: Case Report

Conflicts of Interest: Nil

Abstract

The tongue is an important organ that affects speech, position of the teeth, periodontal tissue, nutrition, and swallowing. Ankyloglossia is defined as a developmental anomaly of the tongue characterized by an abnormally short, thick lingual frenum. Ankyloglossia host a number of problems including infant feeding difficulties, speech disorders, and various social issues due to the inability of the tongue to protrude. This paper reports management of ankyloglossia with surgical intervention using diode laser.

Keywords: Ankyloglossia; diode laser; lingual frenectomy; tongue-tie.

Introduction

Ankyloglossia, commonly known as tongue tie, is a congenital oral anomaly which may decrease mobility of the tongue tip. It is commonly caused by an unusually short, thick lingual frenulum, a membrane connecting the underside of the tongue to the floor of the mouth.¹ Ankyloglossia, or tongue-tie, can be observed in neonates, children, or adults. The prevalence of ankyloglossia is well established in newborn and is seen in approximately 4%–5% in the newborn population with a 3:1 male-to-female ratio.⁷ As most of the studies have focused on infants and young children regarding ankyloglossia, there is a scarcity of literature in reflecting incidence of ankyloglossia in adolescent and adult.

Many affected children or adults do not complain about their anatomic peculiarity, although anatomic or functional problems can be associated with tongue tie in different stages of life.²

Functional problems associated with tongue tie may exist from birth with resultant difficulty in suckling and swallowing during infancy, to problems which may persist through lifetime such as dysarthria, mechanical problems and social issues.

Tongue tie may also be associated with anatomic related problem. An abnormally low position of the tongue may cause mandibular prognathism with maxillary hypo development due to an exaggerated anterior thrust leading to Class III malocclusion.⁵ Moreover, excessive forces while retrusion of tongue by patient may cause blanching of tissues, gingival recession, and midline diastema in lower central incisors.⁶ Some ankyloglossia cases might cause forward and upward displacement of the larynx and the epiglottis resulting in dyspnoea.

The anatomical and functional limitation of the tongue necessitates the surgical intervention and correction of the condition.

In our case report, we reported a 27-year-old male with tongue-tie who complained of difficulty in protruding his tongue, following which he underwent frenectomy procedure under local anaesthesia with laser, without any complications.

Case Report

A 27-year-old healthy male patient reported to the Department of Periodontology, IPDC Sahibabad with the complaint of difficulty in protruding tongue completely since childhood. On oral examination, it was observed that the patient was unable to touch the palate with the tip of the tongue. Further, it was observed that patient had difficulty in speech. Patient was found to have short lingual frenum with restricted tongue

movements, which was classified as Kotlow's Class II moderate ankyloglossia (10mm).

Table 1: Classification of ankyloglossia – Kotlow's

Classification of ankyloglossia	Range of free tongue*
Normal	>16 mm
Class I: Mild ankyloglossia	12-16 mm
Class II: Moderate	8-11 mm
Class III: Severe	3-7 mm
Class IV: Complete ankyloglossia	<3 mm

*Free-tongue is measured from the insertion of the lingual frenum into the base of the tongue to the tip of the tongue

A written informed consent was obtained from the patient and a lingual frenectomy was planned by using soft tissue diode laser. Topical anesthetic gel was applied to the tip and floor of the tongue near frenum attachment. 2% lignocaine 1:80,000 was administered on the tip of the tongue and along the sides of frenum.

The tongue was retracted and after achieving adequate anesthesia, Diode laser (Biolase, 2.0 W, 940 nm) was used for the frenectomy procedure in contact mode. Frenectomy was started by activating the laser tip from the apex of the frenum to the base in brushing strokes to avoid thermal damage to the tissues.

The laser tip was mopped continuously using wet gauze piece.

Patient was advised to protrude his tongue from time to time during the procedure to check for the release of frenal pull and gain in the movement of tongue. No bleeding was observed, therefore suturing was not done.

The patient was prescribed analgesics and antibiotics, capsule amoxicillin (500 mg) thrice a day for 5 days, and nonsteroidal anti-inflammatory drug tablet ibuprofen (400 mg) + paracetamol (325 mg) thrice a day for 5 days was prescribed to prevent postoperative infection and pain respectively.

Patient was advised “sticking out the tongue” for exercises right after the day of surgery for every 15 mins.

Follow-up at 10 days showed uneventful healing in progress with “white soft slough” formation and complete healing at 3 months with increase in tongue mobility of ≥ 16 mm. Speech articulation was noticeably improved after the speech therapy.

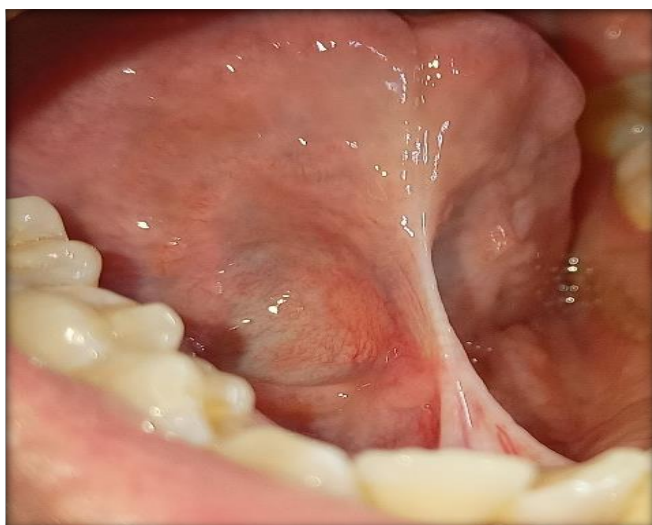


Figure 1: Pre Operative Occlusal View

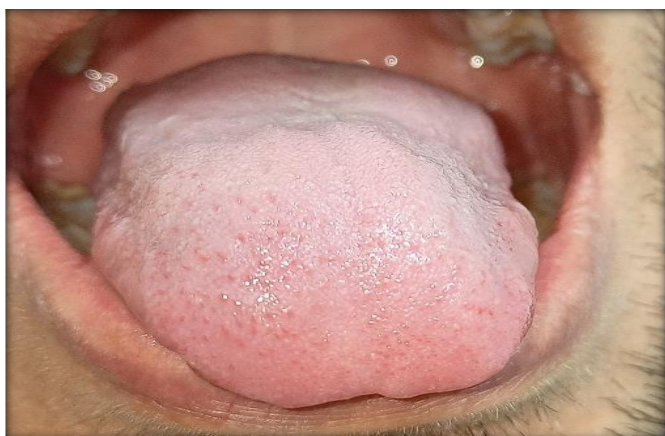

Figure 2: Pre Operative Frontal View

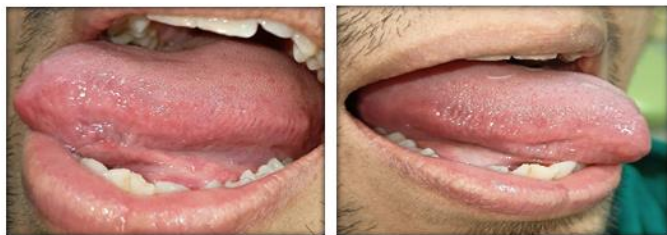

Figure 3: Pre-Operative Left & Right Lateral Views

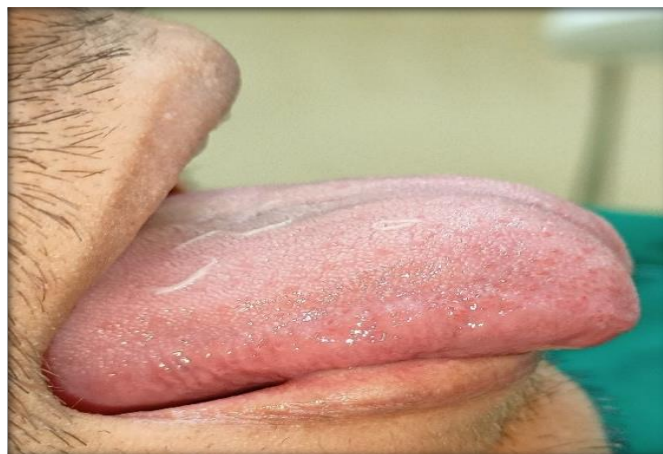

Figure 4: Pre Operative Maximum Protrusion

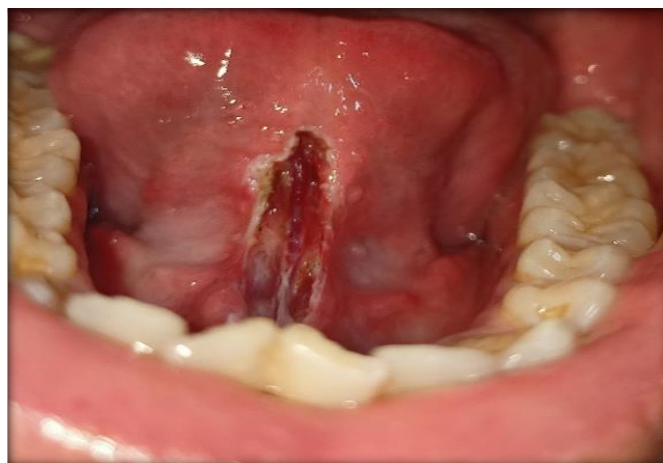

Figure 5: Completion Of Frenectomy By Laser

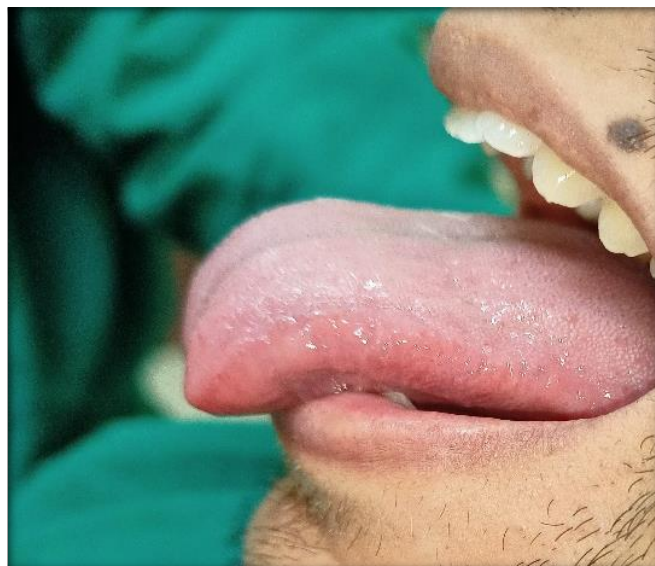

Figure 6: Protrusive Tongue Movement Being Checked During Procedure

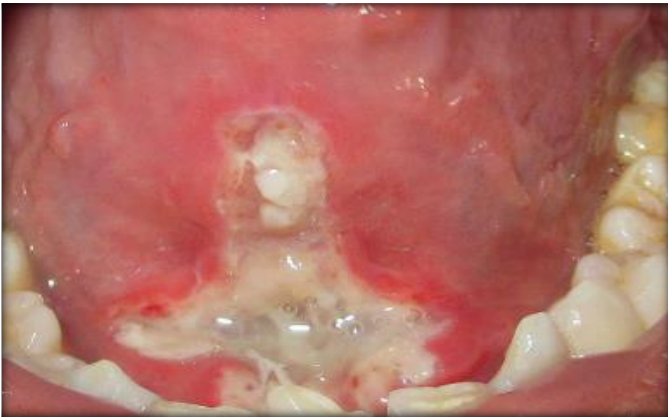


Figure 7: Post-Treatment After 10 Days Showing "White Soft Slough" Formation

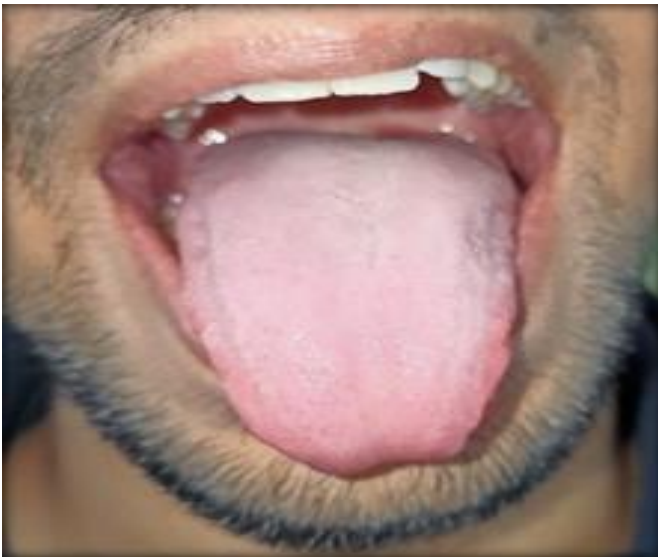

Figure 8: Postoperative view 3 months (Frontal View)

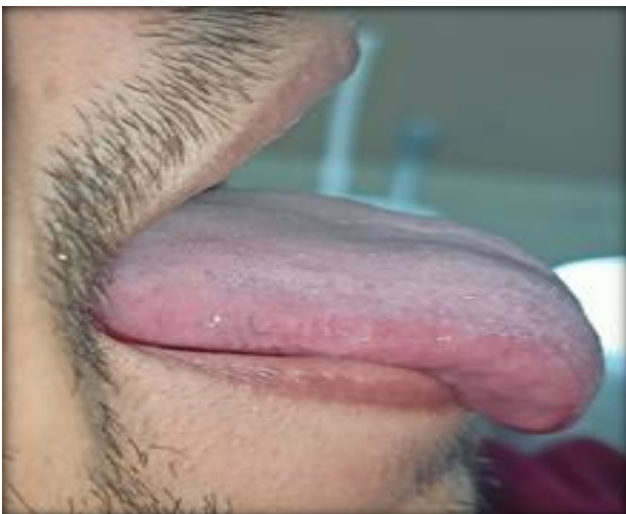

Figure 9: Post-operative 3 months (Lateral View)

Discussion

Ankyloglossia is an uncommon congenital oral anomaly that can cause difficulty with breast-feeding and speech articulation.² For many years, the subject of ankyloglossia has been controversial with practitioners of many specialties having widely different views regarding its significance and management. In many individuals, ankyloglossia is asymptomatic; the condition may resolve spontaneously or affected individuals may learn to compensate adequately for their decreased lingual mobility. Some individuals, however, benefit from surgical intervention frenotomy, frenectomy or frenuloplasty for their tongue-tie. Patients should be educated about the possible long-term effects of tongue-tie so that they may make an informed choice regarding possible therapy.^{2,3} There is some evidence that ankyloglossia can be a genetically transmissible pathology. It is unknown which genetic components regulate the phenotype in the patients affected. More basic research is needed to clarify the exact etiopathogenesis of ankyloglossia. Ankyloglossia was also found associated in cases with some rare syndromes such as X-linked cleft palate syndrome,⁶ Kindler syndrome,⁷ van der Woude syndrome,⁸ and Opitz syndrome.⁹ Nevertheless, most ankyloglossias are observed in persons without any other congenital anomalies or diseases. Speech problems can occur when there is limited mobility of the tongue due to ankyloglossia. The difficulties in articulation are evident for consonants and sounds like "s, z, t, d, l, j, zh, ch, th, dg" and it is especially difficult to roll an "r".¹⁰

After completion of growth and also during infancy, if the individuals have a history of speech, feeding, or mechanical/social difficulties surgical intervention should be carried out. Therefore, surgery should be considered at any age depending on the patient's history

of speech, feeding, or mechanical/social difficulties. Surgical techniques for the therapy of tongue-ties can be classified into three procedures. Frenotomy is a simple cutting of the frenulum. Frenectomy is defined as complete excision, i.e., removal of the whole frenulum. Frenuloplasty involves various methods to release the tongue-tie and correct the anatomic situation. There is no sufficient evidence in the literature concerning surgical treatment options for ankyloglossia to favor any one of the three main techniques.

Conclusion

Ankyloglossia is one of the most misdiagnosed and overlooked congenital abnormality and if untreated can exert a harmful effect on many facets of life. Patient acceptability towards the treatment of lingual frenectomy by laser is greater as lasers provide bloodless and painless surgical field while operating.

Acknowledgment: I gratefully acknowledge the faculty and staff at Inderprastha Dental College and Hospital, Sahibabad.

References

1. Northcutt ME. The lingual frenum. J ClinOrthod2009;43:557-65.
2. Wallace AF. Tongue tie. Lancet 1963;2:377-8.
3. GarcíaPola MJ, González García M, García Martín JM, Gallas M, SeoaneLestón J. A study of pathology associated with short lingual frenum. ASDC J Dent Child 2002;69:59-62, 12.
4. Ballard JL, Auer CE, Khoury JC. Ankyloglossia: Assessment, incidence, and effect of frenuloplasty on the breastfeeding dyad. Pediatrics 2002;110:e63.
5. Acevedo AC, da Fonseca JA, Grinham J, Doudney K, Gomes RR, de Paula LM, et al. Autosomal-dominant ankyloglossia and tooth number anomalies. J Dent Res 2010;89:128-32.

6. Kotlow LA. Ankyloglossia (tongue-tie): A diagnostic and treatment quandary. Quintessence Int1999;30:259-62
7. Lalakea ML, Messner AH. Ankyloglossia: The adolescent and adult perspective. Otolaryngol Head Neck Surg2003;128:746-52.
8. Pirnat S. Versality of an 810 nm diode laser in dentistry: An overview. J Laser Health Acad2007;4:19.
9. Zeinoun T, Nammour S, Dourov N, Aftimos G, Luomanen M. Myofibroblasts in healing laser excision wounds. Lasers Surg Med 2001;28:74-9.
10. Haytac MC, Ozcelik O. Evaluation of patient perceptions after frenectomy operations: A comparison of carbon dioxide laser and scalpel techniques. J Periodontol 2006; 77:1815-9.
11. Kotlow LA. Lasers in pediatric dentistry. Dent Clin North Am 2004;48:889-922, vii.