

### **Endodontic Management of a Severely Dilacerated Mandibular Third Molar - A Case Series**

<sup>1</sup>Dr. Damini Patil, Post Graduate Student, Department of Conservative Dentistry and Endodontics, MIDSR Dental College, Latur.

<sup>2</sup>Dr. Ramchandra Kabir, Reader, Department of Conservative Dentistry and Endodontics, MIDSR Dental College, Latur.

<sup>3</sup>Dr. Sunanda Gaddalay, Professor & HOD, Department of Conservative Dentistry and Endodontics, MIDSR Dental College, Latur.

**Corresponding Author:** Dr. Damini Patil, Post Graduate Student, Department of Conservative Dentistry and Endodontics, MIDSR Dental College, Latur.

**Citation of this Article:** Dr. Damini Patil, Dr. Ramchandra Kabir, Dr. Sunanda Gaddalay, “Endodontic Management of a Severely Dilacerated Mandibular Third Molar - A Case Series”, IJDSIR- June - 2022, Vol. – 5, Issue - 3, P. No. 74 – 80.

**Copyright:** © 2022, Dr. Damini Patil, et al. This is an open access journal and article distributed under the terms of the creative commons attribution non-commercial License. Which allows others to remix, tweak, and build upon the work non-commercially, as long as appropriate credit is given and the new creations are licensed under the identical terms.

**Type of Publication:** Case Report

**Conflicts of Interest:** Nil

#### **Abstract**

This article aims to provide insight into the clinical modifications required for the endodontic management of severely dilacerated mandibular third molar.

Two canals (mesial and distal) were identified. Clinicians need to be aware of the variations in the root canal anatomy of the third molar. The curved and dilacerated roots in the posterior teeth often present a significant challenge for the clinicians during the endodontic treatments. The efficient biomechanical preparation is also affected by improper instrumentation in the curved or constricted canals.

During clinical examination, the dental practitioner should identify the extension of decay and the possibility for restoration, mouth opening and accessibility, and future involvement as a functional component in a proposed treatment plan.

The use of conventional instruments and techniques in

the dilacerated roots may develop ledges, fractured instruments, and canal blockages which further complicate the endodontic treatments. The introduction of Fanta AF-F, one rotary instrument, has significantly impacted the biomechanical preparation of root canal systems. However, the fracture rate of these files and the inconvenience of treating the posterior teeth in reduced mouth opening conditions limit their successful usage in endodontic treatments. The Fanta AF-F one rotary instrument has noted advantages such as increased flexibility, strength, and wear resistance over the conventional rotary endodontic systems. The current case series discusses the endodontic treatment of two severely curved root canal systems of mandibular third molars successfully treated with Fanta AF-F one rotary endodontic system.

**Keywords:** Anatomical Variations, AF-F One Rotary File System, Dilaceration, Root canal curvature,

Maxillary third molar.

## **Introduction**

Endodontic treatments of third molars are considered a challenge owing to their posterior location, inconsistent internal anatomy, and bizarre occlusal anatomy.<sup>1</sup>

The complex nature of the root canal system and presence of any anatomical variations always pose a difficult challenge to deliver a successful endodontic treatment. Variations in conventional anatomy are inevitable in every tooth.<sup>2</sup>

The anatomical variations encountered in third molars range from curved roots, bayonet roots, C shaped canals, fused canals. The prevalence of curved canals has been found to be relatively higher in mandibular molars than the maxillary molars. Curved root canals always present a difficulty during cleaning and shaping and the level of difficulty rises as the curvature of canal increases. The treatment outcome is most of times dependent on the skill of the practitioner.<sup>3</sup>

To challenge the complex root canal anatomy, recent advances in the field of dentistry have led to the use of nickel-titanium (NiTi) rotary instruments in endodontic practice. The NiTi instruments have high stiffness that improves with increasing instrument sizes and aid in delivering high lateral forces in curved canals.<sup>4</sup>

The NiTi rotary files have become popular instruments to shape root canals because of their elasticity, efficiency, and cutting capacity.<sup>5</sup>

NiTi rotary instruments such as AF-F One Rotary File (Fanta Dental Materials, Japan) made up of heat treated have a modified S-shaped flat-sided cross-section constitutes the main distinguishing feature of this file instead of the U-shape common to many other rotary instruments.<sup>6</sup> The unique feature of the unique feature of the Fanta AF F-one system (Fanta Dental, Changzhou,

China) is efficient in terms of instrumentation, preserves the original shape of canals and is highly resistant to cyclic fatigue. It is made of the AF-R Wire. It has a flat design that reduces the instrument's cutting surface area. The manufacturer claims that the vertical blades can sweep the debris from flutes to the relieved area.<sup>7</sup>

Recently, AF-F One Rotary File (Fanta Dental Materials, Japan) is introduced with a definitive advantage over the earlier rotary systems such as safer preparation in the curved canals, duration of instrumentation, and resistance to fracture.

The current case series presents two cases of the endodontic treatment of a mandibular third molar with severely curved canals and highlights the various methods employed for its management.

## **Case Report 1**

A 37-year-old female patient reported to the Department of Conservative Dentistry and Endodontics with pain in the lower left back tooth for a week. Clinical examination revealed a deep carious lesion in the lower left mandibular third molar. The findings were confirmed with an intraoral periapical (IOPA) radiograph depicting a deep carious lesion approaching the pulp in the lower left mandibular third molar [Figure no.-1 A] The IOPA radiograph further revealed curved mesial and distal canals but the curvature was greater in mesial canal than distal canal. Pulp vitality tests (cold and electric pulp test) was carried out. Based on clinical, radiographic, and pulp sensibility tests, a diagnosis of symptomatic irreversible pulpitis with apical periodontitis of the left mandibular third molar was made, and a nonsurgical endodontic treatment was planned. The patient had an intention to save the mandibular third molar; hence, an endodontic treatment was planned for mandibular third molar. The tooth was anesthetized by using 1.8 ml of 2% lidocaine containing

1: 80,000 epinephrine (Lignox 2% A, Indoco Remedies Ltd). Under rubber dam isolation, a conventional endodontic access cavity was prepared. A thorough inspection of the pulp chamber floor with a DG16 endodontic explorer (Hu-Friedy, Chicago, IL, USA) revealed two distinct root canal orifices, one on the mesial side, and one on the distal side. After gaining an adequate access, initial scouting of all the root canals was done with K-file no. 10, and the patency of root canals was established. Gates Glidden (GG) drills to allow easy placement of instruments and to gain a straight-line access to the apex. The working length was confirmed using an apex locator (Root ZX; J Morita, Tokyo, Japan) as well as radiographically using a stainless-steel K-file no. 15 [Figure no.-1 B]. Biomechanical preparation was performed using AF-F one rotary files (Fanta Dental Materials, Japan) using crown down technique. All canals were prepared till file 25/0.04%. Irrigation was performed using 2.5% sodium hypo chloride (Prime Dental Products Private limited, India) and 17% EDTA gel (RC Help, Prime Dental products private limited) during the biomechanical procedure. Following the biomechanical preparation, all the canals were irrigated and flushed with 17% EDTA gel and the final rinse was carried out using 2% chlorhexidine (Chlor X, Prevest Denpro). Later the root canals were dried using absorbent paper points and calcium hydroxide intracanal medicament was placed, and the access cavity was sealed with Cavit (3M ESPE Dental Products, St Paul, MN). The next appointment was scheduled after 1 week, where the patient was found to be asymptomatic. The intracanal medicament was removed with the last file used for canal preparation along with copious irrigation of 2.5% sodium hypochlorite. Later, the canals were dried prior to obturation. Master Cone radiograph was taken with 4%

tapered gutta percha cones [Figure-1 C]. Single cone 4% tapered gutta percha cones were used to obturate all the canals by AH plus resin sealer (Dentsply, Maillefer, Konstanz, Germany). A radiograph was taken to assess the quality of the obturation [Figure no.- 1 D]. After completion of the root canal treatment, the access cavity was restored with Tetric N – Ceram Bulk Fill with self-etch bond [Ivoclar]. The patient was recalled after three months; no sign of pain was present, and radiographs were taken, showing no periapical pathology [Figure no.- 1 D]. The patient was referred for the fabrication of a full-coverage restoration. The patient gave her informed consent for the publication of this case.

### **Case Report 2**

A 37-year-old female patient reported to the Department of Conservative Dentistry and Endodontics with pain in the lower right back tooth for a week. Clinical examination revealed a deep carious lesion in the lower right mandibular third molar. The findings were confirmed with an intraoral periapical (IOPA) radiograph depicting a deep carious lesion approaching the pulp in the lower right mandibular third molar [Figure no.-2 A] The IOPA radiograph further revealed curved mesial and distal canals but the curvature was greater in distal than mesial canal. Pulp vitality tests (cold and electric pulp test) was carried out. Based on clinical, radiographic, and pulp sensibility tests, a diagnosis of symptomatic irreversible pulpitis with apical periodontitis of the right mandibular third molar was made, and a nonsurgical endodontic treatment was planned. The patient had an intention to save the mandibular third molar; hence, an endodontic treatment was planned for mandibular third molar. The tooth was anesthetized by using 1.8 ml of 2% lidocaine containing 1: 80,000 epinephrine (Lignox 2% A, Indoco Remedies Ltd). Under rubber dam isolation, a conventional

endodontic access cavity was prepared. A thorough inspection of the pulp chamber floor with a DG16 endodontic explorer (Hu-Friedy, Chicago, IL, USA) revealed two distinct root canal orifices, one on the mesial side, and one on the distal side. After gaining an adequate access, initial scouting of all the root canals was done with K-file no. 10, and the patency of root canals was established. Gates Glidden (GG) drills to allow easy placement of instruments and to gain a straight-line access to the apex. The working length was confirmed using an apex locator (Root ZX; J Morita, Tokyo, Japan) as well as radiographically using a stainless-steel K-file no. 15 [Figure no.-2 B]. Biomechanical preparation was performed using AF-F one rotary files (Fanta Dental Materials, Japan) using crown down technique. All canals were prepared till file 25/0.04%. Irrigation was performed using 2.5% sodium hypo chloride (Prime Dental Products Private limited, India) and 17% EDTA gel (RC Help, Prime Dental products private limited) during the biomechanical procedure. Following the biomechanical preparation, all the canals were irrigated and flushed with 17% EDTA gel and the final rinse was carried out using 2% chlorhexidine (Chlor X, Prevest Denpro). Later the root canals were dried using absorbent paper points and calcium hydroxide intracanal medicament was placed, and the access cavity was sealed with Cavit (3M ESPE Dental Products, St Paul, MN). The next appointment was scheduled after 1 week, where the patient was found to be asymptomatic. The intracanal medicament was removed with the last file used for canal preparation along with copious irrigation of 2.5% sodium hypochlorite. A master cone radiograph was taken with 4% tapered gutta-percha points [Figure-2 C]

Later, the canals were dried prior to obturation. Single cone 4% tapered gutta percha cones were used to obturate all the canals by AH plus resin sealer (Dentsply, Maillefer, Konstanz, Germany). A radiograph was taken to assess the quality of the obturation [Figure no.-2 D]. After completion of the root canal treatment, the access cavity was restored with Tetric N – Ceram Bulk Fill with self-etch bond [Ivoclar].

The patient was recalled after three months; no sign of pain was present, and radiographs were taken, showing no periapical pathology [Figure no.- 2 D]. The patient was referred for the fabrication of a full-coverage restoration. The patient gave his informed consent for the publication of this case.

### **Discussion**

Dilaceration is the 90° or greater angulation of the tooth or root along the long axis of tooth or root towards mesial or distal direction. It may also be defined as apical deviation of the root by 20° or greater. Dilaceration is considered to result due to trauma to the developing tooth.<sup>8</sup> Third molars commonly present with aberrations in number or shape of root and root canals. Prevalence of anatomical variations is higher in mandibular third molars (3.3- 30.92%) compared to maxillary third molars (1.33-8.46%).<sup>1</sup> In third molars, root dilacerations may occur anywhere along the root length and can include one or all roots. They are generally directed distally.<sup>1</sup>

Curved root canals pose a challenge to the clinician in terms of cleaning and shaping as well as obturation of root canal system.<sup>9</sup> Determination of degree of canal curvature before initiation of root canal treatment is essential to assess the level of difficulty. Knowledge of root canal curvature helps to plan the root canal preparation precisely as well as overcome the anatomic complexity and limitations of root canal instruments. It

permits preservation of the curvature during root canal preparation and prevents deformation of root canal instruments.<sup>10</sup> Therefore, diagnosis of root dilaceration before initiation of endodontic treatment is crucial to ensure adequate canal preparation.<sup>11</sup> Root canal curvature may be determined by various methods with the help of periapical radiographs. Schneider described a technique to calculate canal curvature using an angle formed by two straight lines – a line drawn parallel to the long axis of canal in the coronal third and a second line drawn from apical foramen to intersect the first line. The angle of curvature may be classified as straight ( $5^\circ$  or less), moderate ( $10-20^\circ$ ) and severe ( $25-70^\circ$ ).<sup>10</sup> Thus, the canal curvature in our case was of ‘severe’ type.

The various factors which affect the preparation of curved root canals include technique of instrumentation, diameter and flexibility of endodontic instruments, location of apical foramen and dentin microhardness. Conventionally, 0.02 taper stainless steel instruments are used for preparation of root canal. However, instruments above #15/ 20 size tend to straighten in the canal owing to their inflexibility. Use of such instruments for preparation of curved canals may lead to iatrogenic alteration in the original shape of canal, especially in the apical third. Commonly encountered procedural errors are formation of ledges, elbows or zips; canal blockage, perforation, transportation of the apical foramen and instrument fracture.<sup>12</sup>

While preparing the curved canals, the following principles were closely followed:

- (1) To maintain the apical foramen in its original location.
- (2) To gain a proper straight-line access to the site of curvature.
- (3) To respect the anatomical danger zone in curved canals: the inner wall of the middle third and outer

aspect of the apical third.

- (4) To use an instrument that will closely adapt to the original shape of the canal.<sup>8</sup>

The measures to avoid procedural errors in such cases include pre-curving of file, extravagant use of smaller files, use of intermediate size files, use of flexible files, anti-curvature filing, coronal flaring and balanced force technique.<sup>11</sup>

AF-F One Fanta rotary file system (Fanta Dental Materials, Japan) is made up of AF-R wire, with an extended cyclic fatigue life beyond the conventional NiTi alloy, which may allow preserving the original shape of the canal; without increasing the risk of failure because of cyclic fatigue.<sup>13</sup> Thus AF-F One rotary file is indicated for safe and efficient biomechanical preparations in curved and constricted root canal systems. Hence, AF-F One rotary instruments were used for canal preparation in this case.

Thus, successful management of severely curved root canal requires careful preoperative assessment, sequential use of appropriate hand/rotary instruments, adequate glide path preparation and frequent irrigation. The degree of canal curvature acts as a guideline for treatment planning in these cases.

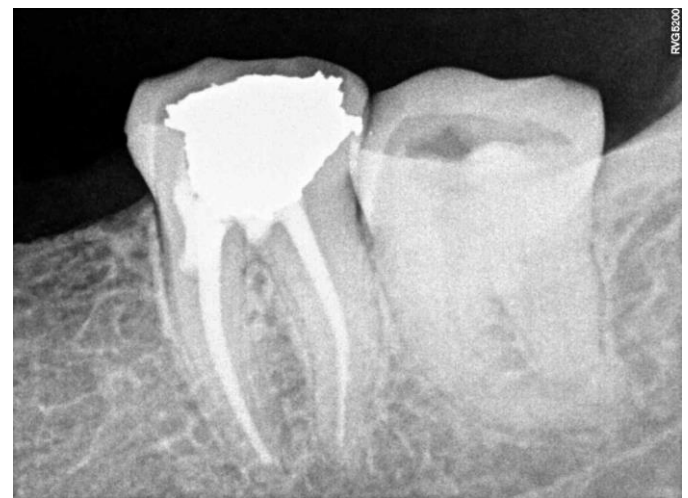

Figure 1 A: Pre-Operative Radiograph

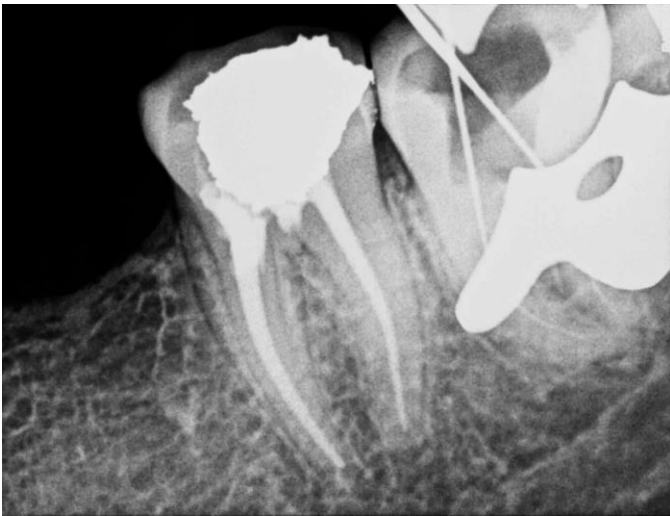

Figure 1 B: Working length Radiograph

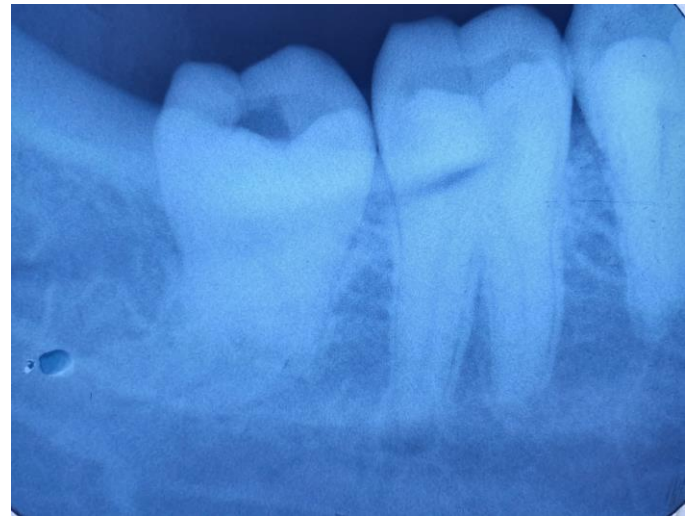

Figure 2 A: Pre-Operative Radiograph

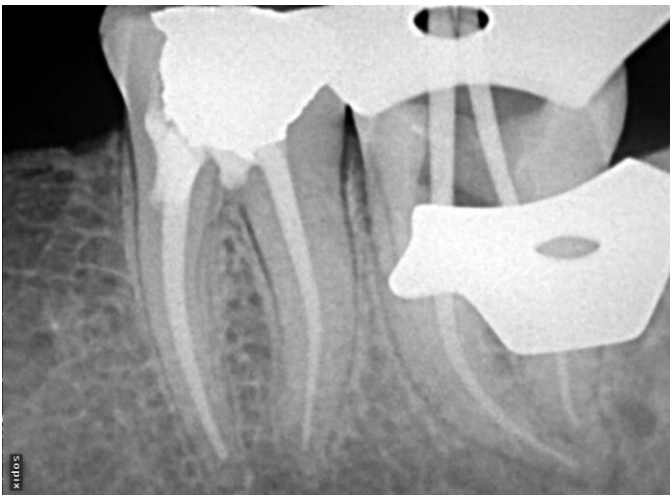

Figure 1 C: Master Cone Selection Radiograph

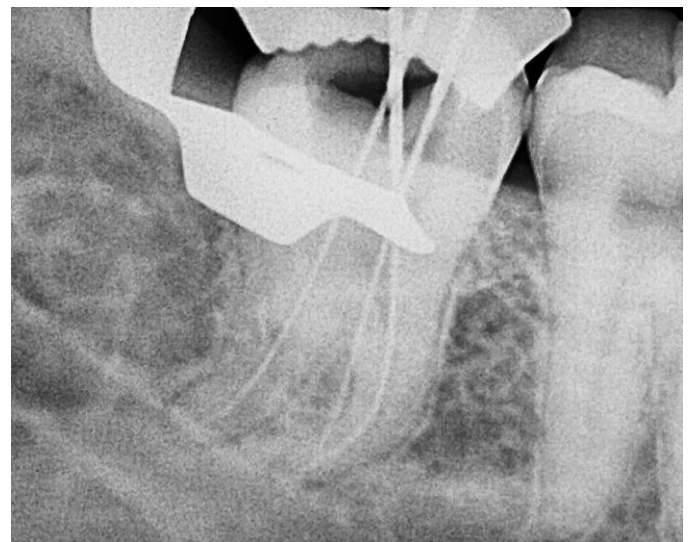


Figure 2 B: Working length Radiograph

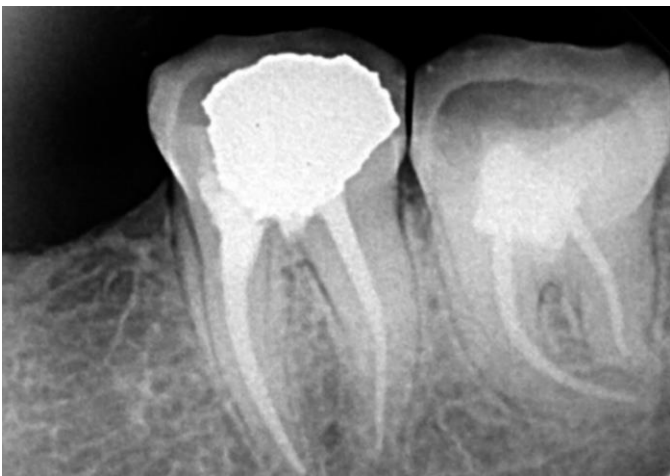

Figure 1 D: Post Obturation Radiograph

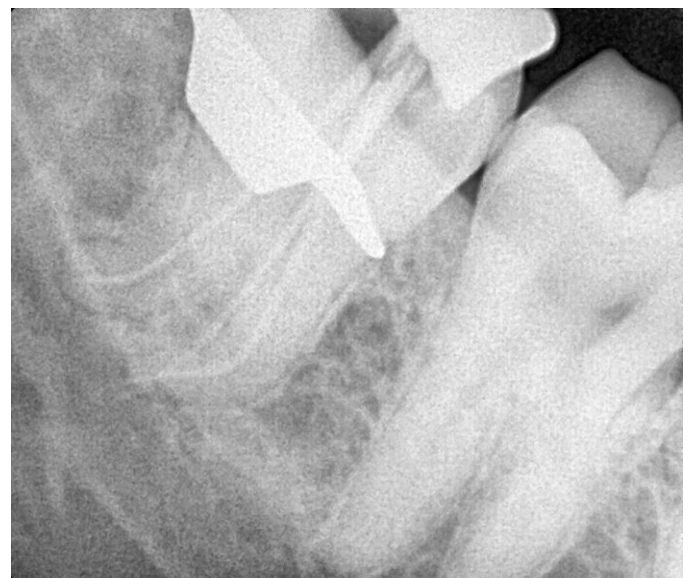

Figure 2 C: Master Cone Selection Radiograph

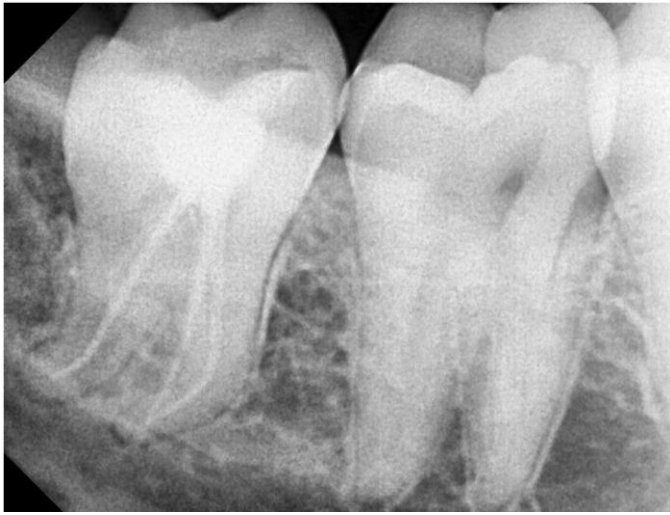

Figure 2 D: Post Obturation Radiograph

### References

1. H. M. A. Ahmed, "Management of third molar teeth from an endodontic perspective," *European Journal of General Dentistry*, vol. 1, no. 3, p. 148, 2012.
2. Peikoff MD, Christie WH, Fogel HM. The maxillary second molar: Variations in the number of roots and canals. *Int Endod J* 1996; 29:365-9.
3. Ćosić J, Galić N, Vodanović M, Njemirovskij V, Šegović S, Pavelić B, Anić I. An in vitro morphological investigation of the endodontic spaces of third molars. *Collegium antropologicum*. 2013 Jul 1;37(2):437-42.
4. Bergman's L, Van Cleynenbreugel J, Wavers M, Lambrecht's P. Mechanical root canal preparation with NiTi rotary instruments: Rationale, performance and safety. Status report for the American journal of dentistry. *Am J Dent* 2001; 14:324-33.
5. Ankrum MT, Hartwell GR, Truitt JE. K3 Endo, Protaper, and Profile systems: Breakage and distortion in severely curved roots of molars. *J Endod* 2004; 30:234-7.
6. Schafer E, Erler M, Dammaschke T (2006b) Comparative study on the shaping ability and cleaning efficiency of rotary Mtwo instruments: part 2—cleaning effectiveness and shaping ability in severely curved root canals of extracted teeth. *Int Endod J* 39:203–212.
7. Kaddoura R, Madarati AA, Al Tayyan M. Shaping ability of different single-file rotary systems in simulated S-shaped canals by a new investigation approach: An in vitro study. *Saudi Endod J* 2021; 11:173-80.
8. Jafarzadeh H, Abbott PV. Dilaceration: review of an endodontic challenge. *J Endod*. 2007; 33:1025–30.
9. Sakkir N, Thaha KA, Nair MG, Jospeh S, Christal in R. Management of dilacerated and S- shaped root canals-An endodontic challenge. *J Clin Diagn Res*. 2014;8: ZD22-24.
10. Estrela C, Bueno MR, Sousa-Neto MD, Pecora JD. Method for determination of root curvature radius using cone-beam computed tomography images. *Braz Dent J*. 2008;19(2):114-18.
11. Raut AW, Mantri V, Kala S, Lakh era H. Management of Severely Dilacerated Mandibular Third Molar. *J Clin Diagn Res*. 2017 Aug;11(8): ZJ05-ZJ06.
12. Balani P, Niazi F, Rashid H. A brief review of the methods used to determine the curvature of root canals. *J Res Dent*. 2015; 3:57-63.
13. Azim AA, Tarrosh M, Azim KA, Piasecki L. Comparison between single-file rotary systems: part 2—the effect of length of the instrument subjected to cyclic loading on cyclic fatigue resistance. *J Endod*. 2018; 44 (12):1837-42.