

Chronic Orofacial pain or bony spicule - A diagnostic dilemma: Report of two cases

¹Dr. Shahana Parveen, 3rd year P.G, Subharti Dental College and Hospital, Meerut, Uttar Pradesh

²Dr Prajesh Dubey, Professor, Subharti Dental College and Hospital, Meerut, Uttar Pradesh

³Dr. Swati Gupta, Associate Professor, Subharti Dental College and Hospital, Meerut, Uttar Pradesh

Corresponding Author: Dr. Shahana Parveen, 3rd year P.G, Subharti Dental College and Hospital, Meerut, Uttar Pradesh

Citation of this Article: Dr. Shahana Parveen, Dr Prajesh Dubey, Dr. Swati Gupta, “Chronic Orofacial pain or bony spicule - A diagnostic dilemma: Report of two cases”, IJDSIR- May - 2022, Vol. – 5, Issue - 3, P. No. 129 – 133.

Copyright: © 2022, Dr. Shahana Parveen, et al. This is an open access journal and article distributed under the terms of the creative commons attribution non-commercial License. Which allows others to remix, tweak, and build upon the work non-commercially, as long as appropriate credit is given and the new creations are licensed under the identical terms.

Type of Publication: Case Report

Conflicts of Interest: Nil

Abstract

Craniofacial pain disorders are annoying to the doctor and the patient. Several related structures can cause pain on the soft palate and pharynx. As a result, diagnosing patients who complain of pain in these locations can be complicated and difficult. The anatomy of the head and neck region is complicated, both physically and neurologically, making diagnosis challenging. Several pain conditions frequently have similar symptoms. Bursitis of the pterygoid hamulus is one such condition. It is a rare craniofacial pain syndrome used to describe palatal and pharyngeal pain due to an enlarged pterygoid hamulus. The pterygoid hamulus is a hook shaped bony process located bilaterally on each medial pterygoid plate of the sphenoid bone, posterior and medial to each maxillary tuberosity. Soft palate, ear, throat soreness, maxillary pain, difficulty in swallowing are also signs of this type of bursitis. Otitis media is sometimes mistaken as this condition. Conservative or surgical treatment options are available. If the etiologic factor of bursitis is osteophytic formation on the hamulus or hypertrophy of

the bursa, resection of the hamulus is usually the preferred surgical treatment. We reported a two similar cases of bursitis that was managed successfully by surgical treatment.

Keywords: Pterygoid Hamulus, Chronic orofacial pain, bony spicule, Pterygoid hamulus syndrome, Bursitis.

Introduction

Despite advances in our understanding of various pain syndromes and diagnostic processes, diagnosing patients who complain of palate and pharyngeal discomfort can be challenging and confusing. The basic difficulty in diagnosis arises from the fact that the symptoms of neurologic, myogenic, and psychogenic pain states in the facial region are remarkably similar. Elongated styloid processes, glossopharyngeal neuralgia, salivary gland tumours, myofascial pain dysfunction syndrome, TMJ disorders, otitis media, and impacted third molars have all been associated to pain in the palate and pharynx.¹ Another cause of pain in the soft palate and pharynx is pterygoid hamulus bursitis. Shankland² demonstrated the presence of the hamular process bursae histologically in

1996. Strange persistent sensations, burning, swelling, and erythema of the pterygoid hamulus region are among the clinical characteristics. The discomfort frequently radiates to the pharynx, ipsilateral face, and temporal area, making it difficult to distinguish between headache, temporomandibular disorders, and dental infections such as pericoronitis. The patient may appear with symptoms comparable to glossopharyngeal neuralgia.³ To make an accurate diagnosis and differentiate a condition from these symptoms, a clinician must first understand the related disease. Oral access, manually or with a blunt instrument, is used to palpate the hamular process in the posterior and medial zones of the maxillary tuberosity. Although the pain is typically restricted to the ear zone, it is important to determine whether a local or referred pattern exists during the examination. Sometimes the erythematous presentation in the zone and the elongation of the process is evident. Understanding the anatomy of the pterygoid hamulus and its relationship to adjacent structures is essential for determining the cause of inflammatory or traumatic pain in the oropharyngeal region. In the present paper we presented two cases with chronic orofacial pain.

Clinical Report 1

A 52 year old female patient presented to the Department of Oral and Maxillofacial Surgery, Subharti Dental College and Hospital, Meerut, Uttar Pradesh, India with a chief complaint of radiating pain in her upper left back tooth region since 2 years. Pain is spontaneous, sharp, shooting radiates towards her left ear also patient has muscle tenderness over the same region. During swallowing and chewing the patient expressed pain. Dental extraction of upper left 1st and 2nd molar was done 2 years back. On clinical examination overlying mucosa was normal but on

palpation the mass was rigid and hard was associated with tenderness on overlying mucosa, between the alveolar region of left maxillary 2nd and 3rd molar region. A sharp pain was elicited on palpation with blanching on left side of pterygoid hamulus region. CBCT of the maxilla was performed, pterygoid hamulus on left side protruded more medially than the right side (Figure 1) Hence the diagnosis was made as pterygoid hamulus bursitis.

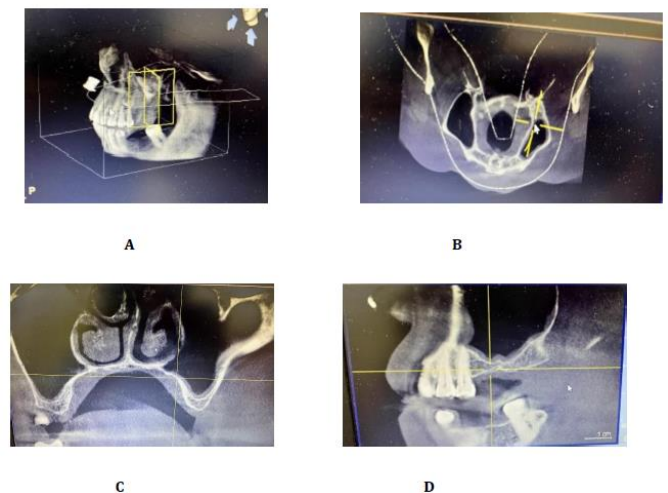


Figure 1: A- 3D reconstruction view of Right side , B- Axial Section, C- Coronal section , D – Sagittal Section. Surgical treatment was advised to the patient. 2% lignocaine with 1:80,000 adrenaline was infiltrated in the area of the lesion. Surgical exposure was done with the help of 15 number BP blade. A crestal incision was given and incision was extended medially taking care and preserving the greater palatine vessels. Full thickness mucoperiosteal flap was raised. The elongated pterygoid hamulus was fractured from its base with the help of mosquito forceps. The resected specimen was sickle shaped and measured around 11mm in dimension. The overlying bone was smoothed with the help of Miller bone file and copious irrigation with 10 % betadine and 0.9% normal saline was done. The surgical wound was closed primarily with the help of 3-0 black braided silk suture and healed uneventfully. After 1

week the patient is recalled for followup and for suture removal (Figure 2). The radiating pain was disappeared on 4th day post-operative day.

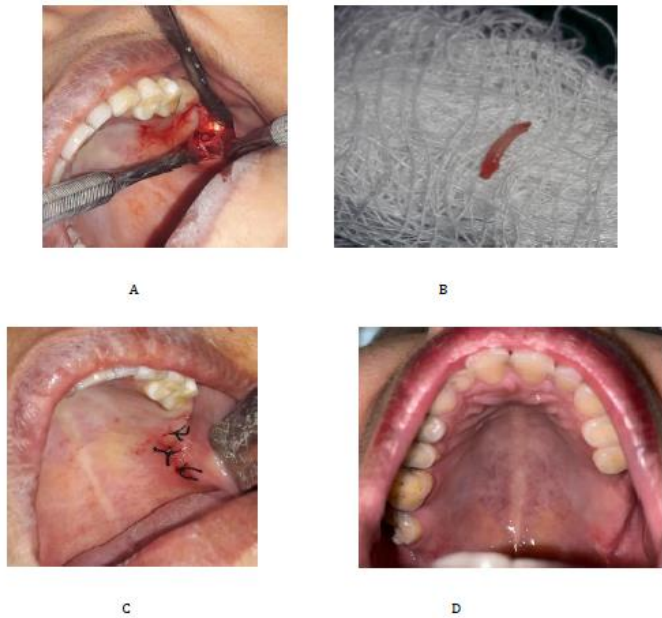


Figure 2: A: Exposed pterygoid hamulus, B: Resected sickle shape elongated pterygoid hamulus, C: Primary suturing, D: Post-operative picture after 1 week.

Case Report 2

A 35 year old female patient reported with a chief complain of pain in her right back tooth region since 1 year. Pain is dull, intermittent, non-radiating in nature aggravates on chewing food. There was no muscle tenderness was palpated. On clinical examination mild erythematous mucosa was seen over right alveolar region posteriorly. On palpation a bony spicule was palpated which is smooth and tender on palpation. No blanching was seen on palpation. A baseline orthopantomogram(OPG) was advised to the patient. No abnormality was seen in the OPG. Hence the diagnosis was made as bony spicule over that area.

Alveoloplasty of that region is advised to the patient. 2% Lignocaine with 1:80,000 adrenaline was in the right side of hard palate and in buccal mucosa was given. Surgical exposure was done with the help of 15 number

BP blade. The crestal incision on alveolus was given. Full thickness mucoperiosteal flap was raised and the lesion was exposed. The extended bone was removed with the help of bone rongeur, sharp and irregular margins were smoothed with the help of Miller bone file. Copious irrigation with 10% betadine and 0.9% normal saline was done. The surgical wound was closed primarily with the help of 3-0 black braided silk suture and healed uneventfully. The patient was recalled after 1 week for follow-up and suture removal was done. The pain was relieved on post operative 5th day.

Discussion

Because discomfort in the soft palate or pharyngeal region can be caused by a variety of factors, it can be difficult to diagnose. Although pterygoid hamulus bursitis is a rare condition, it should be included in the differential diagnosis as a source of pain. The information gleaned from the patient's history and clinical findings may assist the clinician in reaching a more complete diagnosis. This is especially important when the clinical examination of patients reveals no positive findings. Infiltration of local anaesthetic can be a useful diagnostic assistance for differentiating hamular pain from other probable causes, according to Eyrich et al.⁴ Dupont and Brown⁵ reported a case of hamulus tenderness to palpation that was resolved after anaesthetic infiltration of the area. Shankland further suggested that anaesthetic injection in the hamular area could help confirm the diagnosis of pterygoid hamular bursitis.

In terms of treatment, there is no universally approved protocol. The pterygoid hamulus syndrome can be treated conservatively or surgically. The local trauma cause must be eliminated for palliative care, and a soft diet is recommended. Another conservative therapy strategy is to inject synthetic cortisone into the hamulus

region. Ramirez et al.⁶ and Salins and Bloxham⁷ reported on the infiltration of synthetic cortisone in the treatment of hamular bursitis patients, obtaining satisfactory result without the recurrence of the original complaints.

Surgical management would be considered if conservative treatment fails or if the etiologic cause of the bursitis is hamulus elongation. For the relief of the patient's symptoms, Hertz, Kronman et al., Eryich et al., and Sasaki et al. favoured surgical exposure and resection of the hamulus. Noone et al. and Kane et al.⁸ concluded that the fracture of the pterygoid hamulus and consequent disturbance of the tensor veli palatine tendon do not significantly alter the state of middle ear disease. Despite numerous attempts to explain the mechanism of pain created by the hamular region, the precise aetiology remains unknown. The sensation of discomfort, according to Kronman et al.⁹ was generated by bursitis-induced damage, which prevented the tensor veli palatini muscle from contracting. Furthermore, because the spicule penetrated the palate soft tissues, the osteophyte's expansion into the palatal musculature caused damage. According to Ramirez et al.¹⁰ the connection between hamulus bursitis and otic symptoms can be traced back to the stomatognathic and otic systems' shared neuronal motor connections. Extra-activity in the middle ear can result in symptoms like vertigo, tinnitus, otalgia, hypoacusis, and fullness.

Conclusion

Several related structures can cause pain on the soft palate and pharynx. As a result, diagnosing patients who complain of pain in these locations can be complex and difficult. Pterygoid hamulus bursitis is an uncommon condition that manifests itself in the palate and pharyngeal regions.

References

1. Cho JY, Cheon KY, Shin DW, Chun WB, Lee H. Pterygoid hamulus bursitis as a cause of craniofacial pain: a case report. *Journal of the Korean Association of Oral and Maxillofacial Surgeons*. 2013 Jun 1;39(3):134-8.
2. Shankland WE 2nd. Bursitis of the hamular process. Part I: anatomical and histological evidence. *Cranio* 1996;14:186-9.
3. Love JG. Diagnosis and treatment of glossopharyngeal neuralgia. *Ann Surg* 1941;113:1078-9.
4. Eyrich GK, Locher MC, Warnke T, Sailer HF. The pterygoid hamulus as a pain-inducing factor. A report of a case and a radiographic study. *Int J Oral Maxillofac Surg* 1997;26:275-7.
5. Dupont JS Jr, Brown CE. Comorbidity of pterygoid hamular area pain and TMD. *Cranio* 2007;25:172-6.
6. Ramirez LM, Ballesteros LE, Sandoval GP. Hamular bursitis and its possible craniofacial referred symptomatology: two case reports. *Med Oral Patol Oral Cir Bucal* 2006;11:E329-33.
7. Salins PC, Bloxham GP. Bursitis: a factor in the differential diagnosis of orofacial neuralgias and myofascial pain dysfunction syndrome. *Oral Surg Oral Med Oral Pathol* 1989;68:154-7.
8. Kane AA, Lo LJ, Yen BD, Chen YR, Noordhoff MS. The effect of hamulus fracture on the outcome of palatoplasty: a preliminary report of a prospective, alternating study. *Cleft Palate Craniofac J* 2000;37:506-11.
9. Kronman JH, Padamsee M, Norris LH. Bursitis of the tensor veli palatini muscle with an osteophyte on the pterygoid hamulus. *Oral Surg Oral Med Oral Pathol* 1991;71:420-2.

10. Ramirez LM, Ballesteros LE, Sandoval GP. Hamular bursitis and its possible craniofacial referred symptomatology: two case reports. *Med Oral Patol Oral Cir Bucal* 2006;11:E329-33.
11. Putz R, Kroyer A. Functional morphology of the pterygoid hamulus. *Ann Anat* 1999;181:85-8.
12. Ramirez LM, Ballesteros LE, Sandoval GP. Hamular bursitis and possible craniofacial referred symptomatology: Two case reports. *Med Oral Patol Oral Cir Bucal*. 2006; 11(4):E329-33.
13. Orhan K, Sakul BU, Oz U, Bilecenoglu B. Evaluation of the pterygoid hamulus morphology using cone beam computed tomography. *Oral Surg Oral Med Oral Pathol Oral Radiol Endod*. 2011;112(2):e48-55.
14. Shankland WE 2nd. Pterygoid hamulus bursitis: one cause of craniofacial pain. *J Prosthet Dent*. 1996;75(2):205-10. Review
15. Hertz RS. Pain resulting from elongated pterygoid hamulus: report of case. *J Oral Surg*. 1968;26(3):209-10.