

**Benign Fibrous Histiocytoma: A Rare Case Report**

<sup>1</sup>Dr. Anjani Kumar Jha, MDS, Department of Oral and Maxillofacial Surgery, Professor and HOD, Mithila Minority Dental College and Hospital, Darbhanga, Bihar.

<sup>2</sup>Dr. Md Mahbulul Hoda, MDS, Department of Oral and Maxillofacial Surgery, Assistant Professor, Mithila Minority Dental College and Hospital, Darbhanga, Bihar.

<sup>3</sup>Dr. Tauseef Fazal , MDS, Department of Oral and Maxillofacial Surgery, Associate Professor, Mithila Minority Dental College and Hospital, Darbhanga, Bihar.

**Corresponding Author:** Dr. Md Mahbulul Hoda, MDS, Department of Oral and Maxillofacial Surgery, Assistant Professor, Mithila Minority Dental College and Hospital, Lalit Narayan Mithila University, Darbhanga, Bihar.

**Citation of this Article:** Dr. Anjani Kumar Jha, Dr. Md Mahbulul Hoda, Dr. Tauseef Fazal, “Benign Fibrous Histiocytoma: A Rare Case Report”, IJDSIR- October - 2021, Vol. – 4, Issue - 5, P. No. 06 – 09.

**Copyright:** © 2021, Dr. Md Mahbulul Hoda, et al. This is an open access journal and article distributed under the terms of the creative commons attribution noncommercial License. Which allows others to remix, tweak, and build upon the work non commercially, as long as appropriate credit is given and the new creations are licensed under the identical terms.

**Type of Publication:** Case Report

**Conflicts of Interest:** Nil

**Abstract**

Fibrous histiocytoma is a benign soft tissue tumour that may present as a fibrous mass anywhere in the human body. Benign fibrous histiocytoma rarely occurs in bone and may affect femur, tibia, and pelvic bone. Jaw bone involvement is very unusual with only few cases reported till date. We here report a case of benign fibrous histiocytoma localized in the oral cavity. The clinical and management of the lesion are discussed briefly.

**Keywords:** Benign Fibrous Histiocytoma, Soft Tissue Tumour, Benign Tumour.

**Introduction**

According to the WHO histological classification of tumors, benign fibrous histiocytoma of bone is defined as a benign lesion composed of spindle shaped fibroblasts, arranged in a storiform pattern, with a variable admixture of small, multinucleated osteoclast like giant cells. Foamy

cells (xanthoma), chronic inflammatory cells, stromal haemorrhages and hemosiderin pigment are also commonly present.<sup>1</sup> Nowadays, benign fibrous histiocytoma is included in the so-called “fibrohistiocytic tumours of the soft tissues” that are divided into cutaneous and non-cutaneous types, and in the “fibrohistiocytic tumours of the bone.”<sup>2</sup> The benign fibrous histiocytoma etiology is still obscure. Its occurs rarely in bone and most of the cases were reported in the femur, tibia, and pelvic bone. Jaw bone involvement is even rare.<sup>3</sup>

The majority of the benign fibro histiocytoma cases were found in the oral cavity involved soft tissues of the buccal mucosa, gingiva, lower and upper lips, soft palate, and floor of the mouth.<sup>4</sup> It is reported to present at any age with predominance in male adults (2.5:1). It has been reported in males older than 25 years and with a mean age

of 40 years. The clinical features of the oral benign fibrous histiocytoma are those of a painless solitary tumour, slowly enlarging, from 2cm to 3 cm up to more than 10 cm, over a period of several months. Symptoms include dysphagia, dyspnoea and when the mass is located in the tongue, difficulty to speak may be present. The treatment of choice to oral benign oral fibro histocytoma is en-block surgical excision. The prognosis is good and the oral BFH recurs only if incompletely excised.<sup>2</sup>

The purpose of this article is to present a case of a benign fibro histocytoma and discuss briefly about the clinical and treatment outcomes.

### Case Report

A 45 year old male patient reported to our department of Oral and Maxillofacial Surgery with chief complaint of swelling in the mandibular right parasymphysis and symphysis region from past 8 months. On extra oral examination a diffuse swelling was noted in chin region extending from an imaginary line drawn from right corner of lip to tragus till 2cm below the lower border of mandible superioinferiorly. The swelling extended anteroposteriorly from right angle of mandible till 3cm anteriorly from the midline of the chin. Intra oral examination revealed an obliteration of buccal vestibule in right side from 42 to 45 region.

On palpation the lesion, measuring approximately 4cm \* 10cm, was non-tender and seemed to be well encapsulated, mobile and of a fibro-elastic consistency. The overlying mucosa appeared grossly normal. No lymph nodes were palpable. Intra oral on palpation there were no other abnormalities in the oral cavity and the systemic condition of the patient was good. The clinical appearance of the lesion suggested the possibility of a neoplasm of soft tissues. For radiographic opinion Computed tomography (CT) scan was done and it revealed osteolytic lesion in right hemimandible with midline cross over to

the left side with involvement of the symphysis menti. The clinical and CT scan give the possible diagnosis of neoplastic lesion ? The treatment of choice was excisional biopsy of the lesion. Intraoperative vestibular incision was placed from 13 to 25. Mucoperiosteal flap was reflected and lesion was exposed. Lesion was completely excised and curratted. Primary closure was done with silk 3-0 and antibiotic coverage was done. The post operative course was uneventful. The excised specimen was send for biopsy and reports were suggestive of Benign Fibro histocytoma.(Fig: 1 to Fig:7)

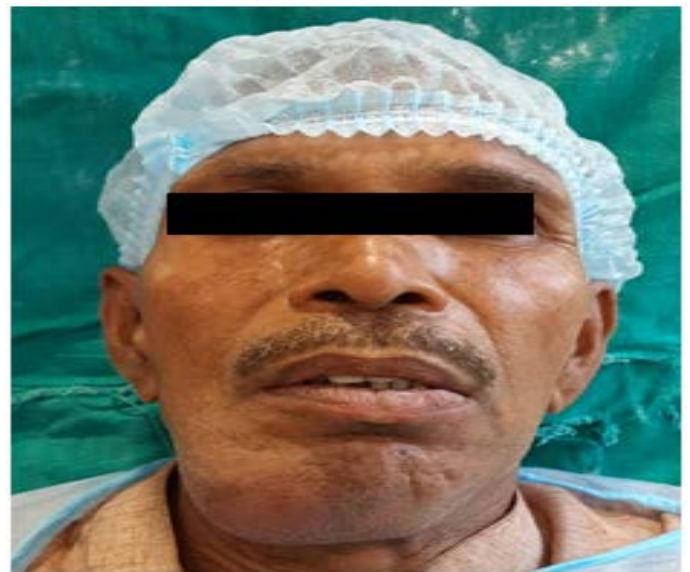

Figure 1: Preop Pic (Frontal View)

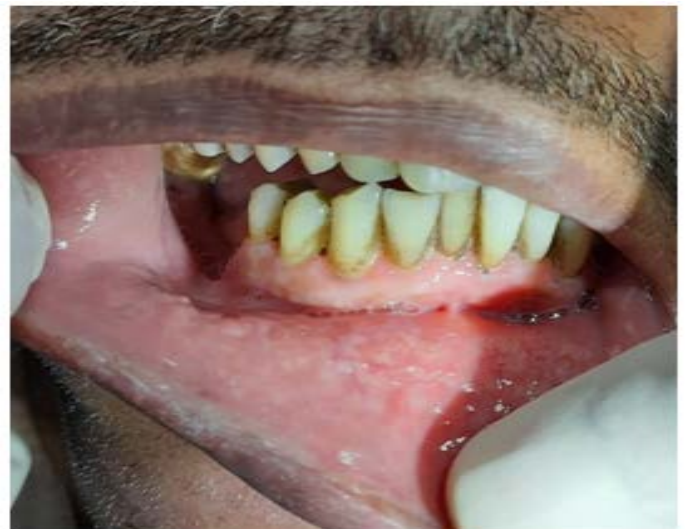

Figure 2: Preop Pic (Intra Oral View)

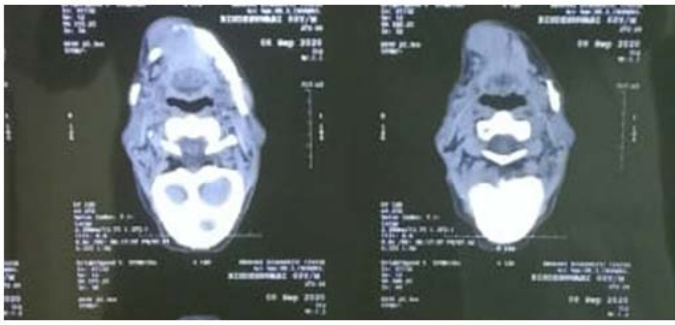


Figure 3: CT scan

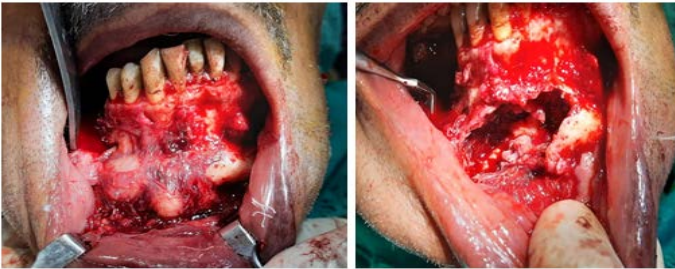

Figure 4: Intra Operative View

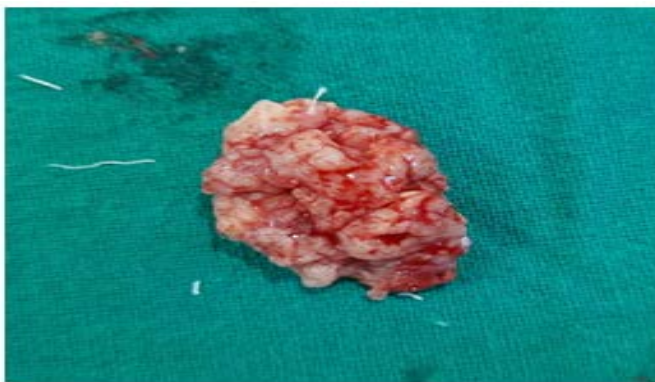

Figure 5: Excised Pathology

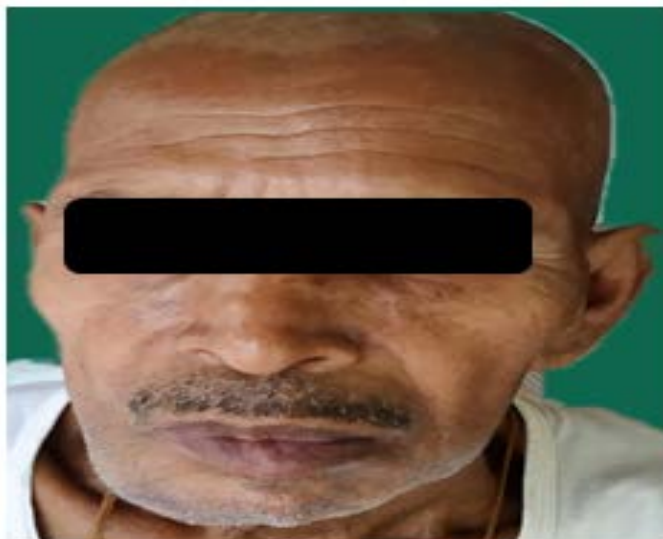

Figure 6: Post op pic

## Discussion

The term “Benign Fibrous Histiocytoma” was first described by Stout and Lates in 1967. Benign Fibrous Histiocytoma represents a diverse group of neoplasms which exhibit both fibroblastic and histiocytic differentiation.<sup>5</sup> In the 1993 second edition of the World Health Organization publication on the histologic typing of bone tumors, the term Benign fibrous histiocytoma was adopted for lesions regarded as true solitary tumors distinct from other connective tissue tumors.<sup>6</sup>

A primary benign fibrous histiocytoma in the mandible is extremely rare with only few reported cases in the literature. The etiology of benign fibro histiocytoma is not yet clear. It may be a neoplasm consisting of fibroblasts and histiocytic-like cells or a regression phenomenon of giant cells tumors mainly found in the pelvic bone, femur and tibia.<sup>1</sup> The clinical diagnosis of oral Benign fibrous histiocytoma is made by a gradually enlarging growth, that is well-circumscribed and does not show aggressive behavior or damage overlying mucosa. However, at clinical level, the differential diagnosis with other soft tissue neoplasms is not possible.<sup>2</sup> Histological characteristics of benign fibro histiocytoma in bones are similar to those of benign fibro histiocytoma occurring in soft tissues. The tumor consists of proliferating fibrohistiocytic cells showing a storiform pattern arrangement, and various numbers of foam cells and giant cells. Histological findings of benign fibro histiocytoma are indistinguishable from those of non-ossifying fibrom (NOF), and, therefore, both should be differentiate based on the clinical radiographic setting.<sup>7</sup>

Immunohistochemistry acts as a useful aid in diagnosis by confirming the origin of cells. CD68 is a transmembrane glycoprotein that is highly expressed by human monocytes and tissue macrophages. It is particularly useful as a marker for the various cells of the macrophage lineage

including monocytes, histiocytes, giant cells, Kupffer cells and osteoclasts. In the current case the positivity for CD68 demonstrate the histiocytic nature of the cells where as vimentin confirms the presence of fibroblast-like cells.<sup>5</sup>The non-ossifying fibroma typically occurs during growth. benign fibro histocytoma on the other hand is found in older patients, presenting with swelling or pain but usually no presence of complicating fractures.<sup>1</sup>

Cale et al., proposed that Benign fibrous histocytoma could be diagnosed in the jaws under 2 circumstances (1) when the tissue exactly resembled metaphyseal fibrous defects microscopically and clinically the patient was an adult and had pain or swelling with radiologic evidence of a locally destructive radiolucent lesion, most often in the mandibular angle-ramus area or (2) when the jaw lesion exactly revealed the features of the soft tissue Benign fibrous histocytoma on microscopic examination.<sup>8</sup> The Common modalities of treatment for bony Benign fibrous histocytoma are curettage, complete resection of the tumor and bone grafting.<sup>5</sup> The prognosis for Benign fibrous histocytoma seems to be excellent with almost no recurrence after complete surgical resection.<sup>1</sup>

### Conclusion

Benign fibrous histocytoma of the jaw bone is rare entity with only few cases reported in literature. Clinically and radiographically, it mimics the commonly occurring benign tumors of the jaw bone and should be considered in differential diagnosis. The prognosis for BFH is good and recurrence is seen only if there is incomplete removal of the lesion. The treatment plan will vary from curettage to wide excision, depending on various factors like the area involved and age of the patient.

### References

1. Maximilian EH Wagner, Majeed Rana, Wolfgang Traenkenschuh, Horst Kokemueller, André M Eckardt and Nils-Claudius Gellrich. "Piezoelectric-assisted

removal of a benign fibrous histiocytoma of the mandible: An innovative technique for prevention of dentoalveolar nerve injury" *Head & Face Medicine* 2011, 7:20

2. D. Prasanna Kumar, Umesh, Tushar Rathi, Vaibhav Jain "Benign Fibrous Histiocytoma: A Rare Case Report and Literature Review" *J. Maxillofac. Oral Surg.* (Jan–Mar 2016) 15(1):116–120.
3. Hitesh Shoor, Keerthilatha M. Pai, Ankur Kaur Shergill1, Abhay Taranath Kamath "Benign fibrous histiocytoma: A rare case involving jaw bone" *Contemp Clin Dent* 2015;6:S266-8
4. Harish Saluja, Vikrant O Kasat, Bhimmapa M Rudagi, Vipin Dehane, Jitendra V Kalburge, Atul Nikam "Benign fibrous histiocytoma of the maxilla: A case report and review of literature" *Indian Journal of Dental Research*, 25(1), 2014
5. Manjusha Pattamparambath, Sudha Sathyabhama, Rohitashwa Khatri, Sujatha Varma, Navajeevraj Machipalliyil Narayanan "Benign Fibrous Histiocytoma of Mandibe: Report of A Case & Updated Review" *Journal of Clinical and Diagnostic Research*. 2016 Jun, Vol-10(6): 24-26
6. De-ming Ou, Gui-qing Liao, Hai-chao Liu "Clinical and Pathologic Characteristics and Surgical Management of Benign Fibrous Histiocytoma of the Mandible: A Case Report" *J Oral Maxillofac Surg* 70:2719-2723, 2012
7. Mitsunobu Kishino, Shumei Murakami, Satoru Toyosawa, Atsutoshi Nakatani, Yuzo Ogawa, Takeshi Ishida, Naokuni Ijuhin "Benign fibrous histiocytoma of the mandible" *J Oral Pathol Med* (2005) 34: 190–2.
8. Cale AE, Freedman PD, Kerpel SM, Lumerman H. Benign fibrous histiocytoma of the maxilla. *Oral Surg Oral Med Oral Pathol*. 1989;68:444-50.