

Our Experience in Orthognathic Surgery – Study of 10 Years

¹Dr.Madhumati Singh, BDS, MDS,MFDS RCPS,FIMSA, Professor & hOD, Department of Oral & Maxillofacial Surgery , Rajarajeswari Dental College and Hospital Bangalore , Karnataka , India , 560074.^{1,1,1}

²Dr.Anjan Shah, BDS MDS,MFDS, FDS RCPS,FIMSA, IBCSOMS, Professor, Department of Oral & Maxillofacial Surgery , Rajarajeswari Dental College and Hospital Bangalore , Karnataka , India , 560074.^{1,1,1}

³Dr Rohit N R, B.D.S,M.D.S(OMFS),F.F.A.S, Department of Oral & Maxillofacial Surgery , Rajarajeswari Dental College and Hospital Bangalore , Karnataka , India , 560074.

Corresponding Author: Dr Rohit N R, B.D.S,M.D.S(OMFS),F.F.A.S, Department of Oral & Maxillofacial Surgery , Rajarajeswari Dental College and Hospital Bangalore , Karnataka , India , 560074.

Citation of this Article: Dr. Madhumati Singh, Dr. Anjan Shah, Dr Rohit N R,“Our Experience in Orthognathic Surgery – Study of 10 Years ”, IJDSIR- January - 2021, Vol. – 4, Issue - 1, P. No. 138 – 151.

Copyright: © 2021, Dr Rohit N R, et al. This is an open access journal and article distributed under the terms of the creative commons attribution noncommercial License. Which allows others to remix, tweak, and build upon the work non commercially, as long as appropriate credit is given and the new creations are licensed under the identical terms.

Type of Publication: Case Report

Conflicts of Interest: Nil

Abstract

Orthognathic surgery is widely used to correct dentofacial discrepancies, however, this procedure presents numerous possible complications.

Aim : of our study is to review the success and complications that were experienced in our patients. We studied 30 cases, who reported to our department for correction of jaw deformity from 2008 till 2019.

Results-Complications we came across in few cases were intraoperative bleeding, bad split, the collapse of nasal septum and relapse.

Conclusion : Most of the complications can be managed by the surgeon, Intraoperatively, or postoperatively. Patients' satisfaction with the change of aesthetic, and acceptance of a new look is the important aspect.

Keywords: Orthognathic surgery ,complications and management .

Introduction

In our study of 10 years, we have included 30 cases requiring dentofacial corrections.

The complications that surgeons experience during and after surgery usually are :

Intraoperative Complications

1. Hemorrhage – This usually occurs due to damage of inferior alveolar, maxillary, retromandibular, facial and sublingual vessels. Can be managed by pressure packs, gauze impregnated with thrombin, local hemostatic agents, ligation of the artery, electrocautery, selective embolization. Anesthesia using sevoflurane can reduce intraoperative bleeding.(hypotensive anesthesia).¹Extensive surgery and reduced body mass index are associated with increased intraoperative relative blood loss².

2. Bad split/Segment fracture- of the buccal plate, the fracture is high in BSSO. Lingual fragment and the distal segment may also get fractured. Different methods of treating these fragments can be studied. And third molar can be extracted 6-9 months before surgery.³⁻⁵
3. Trigemino-cardiac reflex – Cardiac complications such as asystole, bradycardia, cardiac dysrhythmias can occur during maxillofacial surgeries and can be lethal. This has been reported 1.6%. Stimulation of the maxillary branch of the trigeminal nerve, greater palatine nerve, posterior superior alveolar nerve leads to vagus nerve stimulation which activates the parasympathetic nervous system leading to dysrhythmia, reflex bradycardia, hypotension, asystole. Anticholinergic drugs such as atropine 0.2-1.0mg, glycopyrrolate 0.1-0.4mg are injected.⁶⁻⁹
4. Fracture of base of the skull – Improper dissection and uncontrolled force while using pterygomaxillary disjunction can lead to fracture of base of the skull. Intraoperatively there can be CSF leak.
4. Vomero-Sphenoidal Disarticulation – It can result from improper use of septal osteotome in the wrong direction during maxillary osteotomy.
5. Change of nasal morphology – Following the repositioning of the maxilla, nasal deviation or widening can be observed, superior repositioning of maxilla and advancement, this complication can be minimized by performing alar cinch, the deviation can be avoided by reducing the septum by 3mm.^{15,16}
6. Tooth injury- Improper osteotomy cuts on the placement of screws for plating can cause the devitalization of teeth.^{17,18}
7. Necrosis of bony segments- Bone complications can be treated through intravenous injection of third-generation cephalosporins and metronidazole.¹⁹
8. Relapse – It can be due to
 1. The gap between proximal and distal segments can be due to improper fixation, any foreign body into the fragment (ortho bracket). Bony interference between bony segments may be causally related to relapse, changes in the position of condyles or articular discs, and condylar resorption. Bending the distal segment posterior to the last molar, performing a bone graft in the area of the segment gap, and bending plate fixation have been introduced as a means to treat these conditions.²⁰⁻²⁶
 2. Condylar Malposition- Before fixing the plate, the condylar position can be confirmed by manual positioning of the condylar head into glenoid fossa or by using a device.²⁷
 3. Pterygomasseteric extension- Muscles always try to rotate the proximal segment by counterclockwise rotation and bring it back to the original position. Epker's modification by performing detachment of pterygomasseteric sling and overcorrection can minimize relapse.²⁸⁻²⁹

Postoperative Complications

1. Neurologic Injury – It may affect the Inferior Alveolar, Mental, Incisive, Infraorbital and Facial nerves. Sensation over the skin usually recovers completely or doesn't recover at all and can be neuropathic pain which may persist up to one year.¹⁰
2. Infection – Cellulitis, abscess, maxillary sinusitis, osteomyelitis. The chances of all this are low provided aseptic measures are taken and the good antibiotic cover is provided.¹¹
3. Respiratory Insufficiency – Airway obstruction, pneumomediastinum, pneumothorax, the influx of air through the facial planes. nasal cavity, long-duration procedures, aspiration of blood, IMF are some of the causes.¹²⁻¹⁴

9. Temporomandibular Disorder- Orthognathic surgery can improve or worsen the existing TMJ symptoms or conditions , should be treated before the surgery (Splints, Pharmacotherapy, Injection therapy, etc) Rigid Fixation is recommended in term IMF can be avoided.³⁰⁻³¹
10. Psychological changes and patient satisfaction- Patients with dentofacial deformities have an inferiority complex due to their appearance. Some patients will be happy with the post-operative look whereas some do not accept their post-operative look. Patient counseling before and after treatment is important.³²

Discussion

In our study

- 73% patients were satisfied with postoperative look, 8% patients were not satisfied with their postoperative look
- In intraoperative complications – 7% were had bad split, 7% had fibrous union, 3% intraoperative bleeding
- Post-operative 3% change in nasal morphology, 3% fibrous union.

Conclusion

In our experience the complications associated with orthognathic surgery is very minimal, it is a safe procedure to treat dentofacial deformity, Most of the intraoperative complications also can be avoided, by taking, Intraoperative precautions, psychological aspect can be handled by counselling of the patient.







References

1. Lanigan DT, Hey JH, West RA. Major vascular complications of orthognathic surgery: hemorrhage associated with Le Fort I osteotomies. *J Oral Maxillofac Surg* 1990;48:561-73.










2. Thastum M, Andersen K, Rude K, Nørholt SE, Blomlöf J. Factors influencing intraoperative blood loss in orthognathic surgery. *Int J Oral Maxillofac Surg* 2016;45:1070-3.
3. Steenen SA, Becking AG. Bad splits in bilateral sagittal split os- teotomy: systematic review of fracture patterns. *Int J Oral Maxil- lofac Surg* 2016;45:887-97.
4. O'ryan F, Poor DB. Completing sagittal split osteotomy of the mandible after fracture of the buccal plate. *J Oral Maxillofac Surg* 2004;62:1175-6.
5. Patterson AL, Bagby SK. Posterior vertical body osteotomy (PVBO): a predictable rescue procedure for proximal segment fracture during sagittal split ramus osteotomy of the mandible. *J Oral Maxillofac Surg* 1999;57:475-7.
6. Stott DG. Reflex bradycardia in facial surgery. *Br J Plast Surg* 1989;42:595-7.
7. Precious DS, Skulsky FG. Cardiac dysrhythmias complicating maxillofacial surgery. *Int J Oral Maxillofac Surg* 1990;19:279-82.
8. Green JG, Wood JM, Davis LF. Asystole after inadvertent intuba- tion of the orbit. *J Oral Maxillofac Surg* 1997;55:856-9.
9. Matarasso A. The oculocardiac reflex in blepharoplasty surgery. *Plast Reconstr Surg* 1989;83:243-50.
10. Agbaje JO, Van de Castele E, Hiel M, Verbaanderd C, Lambrich- ts I, Politis C. Neuropathy of trigeminal nerve branches after oral and maxillofacial treatment. *J Maxillofac Oral Surg* 2016;15:321- 7.
11. Posnick JC, Choi E, Chavda A. Surgical site infections following bimaxillary orthognathic, osseous genioplasty, and intranasal sur- gery: a retrospective cohort study. *J Oral Maxillofac Surg* 2016. doi: 10.1016/j.joms.2016.09.018. [Epub ahead










- of print]
12. Turvey TA, Hall DJ, Warren DW. Alterations in nasal airway resistance following superior repositioning of the maxilla. *Am J Orthod* 1984;85:109-14.
 13. Virkkula P, Hurmerinta K, Löytönen M, Salmi T, Malmberg H, Maasilta P. Postural cephalometric analysis and nasal resistance in sleep-disordered breathing. *Laryngoscope* 2003;113:1166-74.
 14. Kim T, Kim JY, Woo YC, Park SG, Baek CW, Kang H. Pneumo- mediastinum and pneumothorax after orthognathic surgery: a case report. *Korean J Anesthesiol* 2010;59(Suppl):S242-5.
 15. Chow LK, Singh B, Chiu WK, Samman N. Prevalence of postop- erative complications after orthognathic surgery: a 15-year review. *J Oral Maxillofac Surg* 2007;65:984-92.
 16. Kramer FJ, Baethge C, Swennen G, Teltzrow T, Schulze A, Berten J, et al. Intra- and perioperative complications of the LeFort I oste- otomy: a prospective evaluation of 1000 patients. *J Craniofac Surg* 2004;15:971-7.
 17. Camargo IB, Van Sickels JE, Laureano Filho JR, Cunningham LL. Root contact with maxillomandibular fixation screws in orthog- nathic surgery: incidence and consequences. *Int J Oral Maxillofac Surg* 2016;45:980-4.
 18. Lee UL, Lee EJ, Seo HY, Han SH, Choi WC, Choi YJ. Prevalence and risk factors of tooth discolouration after orthognathic surgery: a retrospective study of 1455 patients. *Int J Oral Maxillofac Surg* 2016;45:1464-70.
 19. Kim S, Kim SY, Kim GJ, Jung HD, Jung YS. Partial necrosis of the mandibular proximal segment following transoral vertical ra- mus osteotomy. *Maxillofac Plast Reconstr Surg* 2014;36:131-4.
 20. Ellis E 3rd, Hinton RJ. Histologic examination of the temporo- mandibular joint after mandibular advancement with and without rigid fixation: an experimental investigation in adult *Macaca mu- latta*. *J Oral Maxillofac Surg* 1991;49:1316-27.
 21. Ueki K, Degerliyurt K, Hashiba Y, Marukawa K, Nakagawa K, Yamamoto E. Horizontal changes in the condylar head after sagit- tal split ramus osteotomy with bent plate fixation. *Oral Surg Oral Med Oral Pathol Oral Radiol Endod* 2008;106:656-61.
 22. Baek SH, Kim TK, Kim MJ. Is there any difference in the condy- lar position and angulation after asymmetric mandibular setback? *Oral Surg Oral Med Oral Pathol Oral Radiol Endod* 2006;101:155- 63.
 23. Yoshida K, Rivera RS, Kaneko M, Kurita K. Minimizing dis- placement of the proximal segment after bilateral sagittal split ramus osteotomy in asymmetric cases. *J Oral Maxillofac Surg* 2001;59:15- 8.
 24. Kang MG, Yun KI, Kim CH, Park JU. Postoperative condylar position by sagittal split ramus osteotomy with and without bone graft. *J Oral Maxillofac Surg* 2010;68:2058-64.
 25. Ellis E 3rd. A method to passively align the sagittal ramus oste- otomy segments. *J Oral Maxillofac Surg* 2007;65:2125-30.
 26. Yang HJ, Hwang SJ. Evaluation of postoperative stability after BSSRO to correct facial asymmetry depending on the amount of bone contact between the proximal and distal segment. *J Cranio- maxillofac Surg* 2014;42:e165-70
 27. Uckan S, Buchbinder D, Orhan M, Mutlu N. Management of early relapse after a sagittal split ramus osteotomy by gradual callus dis- traction: a case report. *J Oral Maxillofac Surg* 2000;58:220-3.










28. Chang HP, Tseng YC, Chang HF. Treatment of mandibular prognathism. J Formos Med Assoc 2006;105:781-90.
29. Kim JW, Jeon HR, Hong JR. The study on vertical stability of anterior open bite patients after bssro. J Korean Assoc Oral Maxillofac Surg 2005;31:422-6.
30. Gunson MJ, Arnett GW, Milam SB. Pathophysiology and pharmacologic control of osseous mandibular condylar resorption. J Oral Maxillofac Surg 2012;70:1918-34.
31. Handelman CS, Greene CS. Progressive/idiopathic condylar resorption: an orthodontic perspective. Semin Orthod 2013;19:55- 70.
32. Lee KH, Lee SH. A clinical study of orthognathic surgery patients' satisfaction and psychologic change. J Korean Assoc Oral Maxillofac Surg 1999;25:151-64.













Sr	Pateint S Photo Preoperative	Surgical Procedure Photo Surgical Treatment		Complications		
		Intraoperative	Postoperative	Intra Operative	Post-Operative	Patient Satisfaction
1		 LEFORT 1 + BSSO		NIL	NIL	PATIENT SATISFIED
2		 BSSO		BAD SPLIT	NIL	PATIENT SATISFIED

3		 <div data-bbox="511 493 795 562" style="border: 1px solid black; padding: 5px; text-align: center;">BSSO</div>		HEMOR RAGE	NIL	PATIE NT SATIS FIED
---	---	---	--	-----------------------	------------	--


4		 <p style="text-align: center;">LEFORT 1</p>		BAD SPLIT	NIL	PATIEN T NOT SATISFI ED
5		 <p style="text-align: center;">LEFORT 1+BSSO</p>		NIL	NIL	PATIEN T SATISFI ED
6		 <p style="text-align: center;">LEFORT 1+BSSO</p>		NEURO LOGIC INJUR Y— MANDI BULAR BRANC H — TRIGE MINAL	NIL	PATIEN T SATISFI ED

7		 <p style="text-align: center;">LEFORT 1 + BSSO</p>		MALUNION OF OSTEOTOMY	NIL	PATIENT SATISFIED
8		 <p style="text-align: center;">LEFORT ONE</p>		CHANGE OF NASAL MORPHOLOGY	NIL	PATIENT NOT SATISFIED
9		 <p style="text-align: center;">BSSO +GEINOPLASTY</p>		NIL	NIL	PATIENT SATISFIED




10		 <p data-bbox="488 537 821 621">AMO + GENIOPLASTY</p>		NEURO LOGIC INJURY	NIL	PATIEN T SATISFI ED
11		 <p data-bbox="488 1010 821 1108">LEFORT 1+AMO +GENIOPLASTY</p>		NIL	NIL	PATIEN T SATISFI ED
12		 <p data-bbox="488 1696 821 1780">AMO + LEFORT 1</p>		NIL	NIL	PATIEN T SATISFI ED








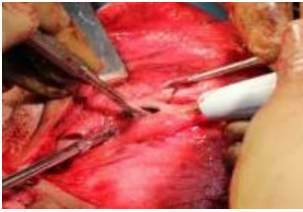

13		 <p data-bbox="488 457 824 552">LEFORT 1+ BSSO</p>		NIL	NIL	PATIENT SATISFIED
14		 <p data-bbox="472 898 846 972">AMO+ GENIOPLASTY</p>		NIL	NIL	PATIENT SATISFIED
15		 <p data-bbox="488 1308 824 1360">BSSO</p>		NIL	NIL	PATIENT NOT SATISFIED
16		 <p data-bbox="509 1686 797 1833">LEFORT ONE +RAPID MAXILLARY EXPANSION</p>		NIL	NIL	PATIENT SATISFIED




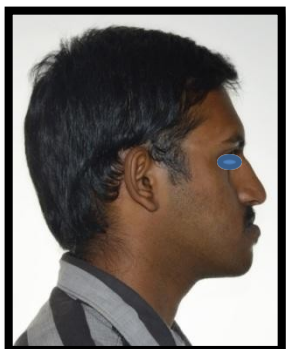


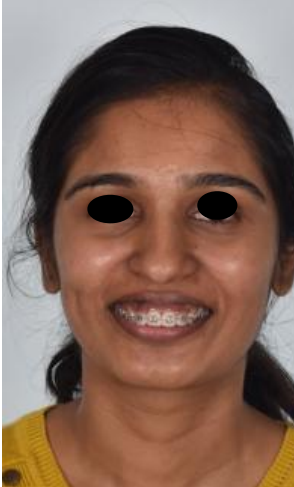


17	 <p>07 12 2013</p>	 <p>LEFORT 1+ BSSO</p>	 <p>OMFS 08 23 2013</p>	NIL	NIL	<p>PATEIN T SATISFI ED</p>
18		 <p>LEFORT ONE</p>		NIL	NIL	<p>PATEIN T NOT SATISFI ED</p>
19		 <p>LEFORT + GENIOPLASTY</p>		NIL	NIL	<p>PATEIN T SATISFI ED</p>

22		 <p style="text-align: center;">BSSO</p>		NIL	NIL	PATIENT SATISFIED
----	---	---	--	-----	-----	-------------------

23		 <p style="text-align: center;">BSSO</p>		NIL	NIL	PATIENT SATISFIED
----	---	--	---	-----	-----	-------------------

24		 <p style="text-align: center;">LEFORT ONE</p>		NIL	NIL	PATIENT SATISFIED
----	--	---	--	-----	-----	-------------------

25		 LEFORT ONE		NIL	NIL	PATIENT SATISFIED
26		 LEFORT ONE		NIL	NIL	PATIENT SATISFIED
27		 LEFORT 2		NIL	NIL	PATIENT SATISFIED

28		 <div data-bbox="422 504 738 577" style="border: 1px solid black; padding: 5px; text-align: center;">BSSO</div>		<p>BAD SPLIT + FRACT URE SEGM ENT</p>	<p>NIL</p>	<p>PATIENT NOT SATISFIED</p>
29		 <div data-bbox="397 997 706 1071" style="border: 1px solid black; padding: 5px; text-align: center;">BSSO</div>		<p>NIL</p>	<p>NIL</p>	<p>PATIENT SATISFIED</p>
30		 <div data-bbox="438 1543 755 1648" style="border: 1px solid black; padding: 5px; text-align: center;">LEFORT ONE</div>		<p>NIL</p>	<p>NIL</p>	<p>PATIENT SATISFIED</p>

BSSO – BILATERAL SAGITAL SPLIT OSTEOTOMY

AMO – ANTERIOR MAXILLARY OSTEOTOMY