

A Cone-Beam Computed Tomographic Assessment of Different Obturation Techniques in Primary Molars- An In Vivo Study

¹Dr. Monali Sengupta, Department of Pediatric & Preventive Dentistry, Kalinga Institute of Dental Sciences, KIIT University, Patia, Bhubaneswar, Odisha, India

²Dr. Brahmananda Dutta, HOD & Professor, Department of Pediatric & Preventive Dentistry, Kalinga Institute of Dental Sciences, KIIT University, Patia, Bhubaneswar, Odisha, India

³Dr. Atul Anand Bajoria, Reader, Department of Oral medicine and radiology, Kalinga Institute of Dental Sciences, KIIT University, Patia, Bhubaneswar, Odisha, India

⁴Dr. Anandamoy Bagchi, Professor, Department of Pediatric & Preventive Dentistry, Kalinga Institute of Dental Sciences, KIIT University, Patia, Bhubaneswar, Odisha, India

Corresponding Author: Dr. Monali Sengupta, Department of Pediatric & Preventive Dentistry, Kalinga Institute of Dental Sciences, KIIT University, Patia, Bhubaneswar, Odisha, India

Citation of this Article: Dr. Monali Sengupta, Dr. Brahmananda Dutta, Dr. Atul Anand Bajoria, Dr. Anandamoy Bagchi, “A Cone-Beam Computed Tomographic Assessment of Different Obturation Techniques in Primary Molars- An In Vivo Study”, IJDSIR- September - 2020, Vol. – 3, Issue - 5, P. No. 378 – 389

Copyright: © 2020, Dr. Monali Sengupta, et al. This is an open access journal and article distributed under the terms of the creative commons attribution noncommercial License. Which allows others to remix, tweak, and build upon the work non commercially, as long as appropriate credit is given and the new creations are licensed under the identical terms.

Type of Publication: Original Research Article

Conflicts of Interest: Nil

Abstract

Purpose: The present study was conducted to evaluate the efficacy of three different obturation techniques: Reamer, Motor driven Lentulospiral and Endodontic Pressure Syringe, using Cone Beam Computed Tomography (CBCT) assessment.

Methods: Pulpectomy was performed on 60 primary mandibular molars of forty children in the age group of 4-8 years by a single investigator. Obturation was done with ZOE paste using one of the randomly allotted method out of the three. Assessment of the obturation was done by a blinded Radiologist, using Cone Beam Computed

Tomography (CBCT) scans taken immediately after the procedure and analyzed for extent of fill and voids.

Result: The data was analyzed using Chi square, Student ‘t’ test and other relevant statistical methods. It was observed that Reamer technique showed highest optimally filled canals 56% (p=0.05) as compared to the other techniques. Although, Endodontic pressure syringe demonstrated highest overfilling (29.2%) it showed better results with respect to homogeneity with maximum void-free canals (73.4%). Lentulospiral performed the worst in terms of extent of fill and voids.

Conclusion: Reamer technique showed optimal results with regards to extent of fill whereas endodontic pressure syringe was superior in terms of controlling voids.

Keywords: CBCT, Cone Beam CT, Endodontic Pressure Syringe, Lentulospiral, Obturation, Pulpectomy, Primary Molars, Reamer, Root Canals

Introduction

Pediatric dentistry has evolved with time from an extraction-oriented practice to conservative treatment protocols, enabling us to save and preserve the primary dentition. Pulpectomy, which involves debridement of the infected pulp tissue and debris from the canals and filling them with a suitable resorbable paste, is one of the many treatment options that can be employed to maintain the functionality of a carious pulpally involved primary tooth until normal exfoliation.^[1,2] The obturation technique plays a crucial role in the successful outcome of a pulpectomy procedure, as do a number of factors upon which the quality of root canal obturation is dependant, like tortuosity of the root canals of primary teeth, variation in anatomical form subsequent to physiological root resorption, deposition of secondary dentin, their unpredictable morphology, etc.^[3]

Various obturation techniques like reamer, endodontic plugger, premixed syringe, lentulospiral paste carrier, endodontic pressure syringe, Navi Tip (Ultradent products Inc.[®], Jordan, UT), Jiffy tubes, etc.^[4-6] have been in use. Radiographically, an ideal obturation should be optimally filled homogeneous canal with no extruded material and little or no voids to eliminate any portals of entry of microorganisms between the canal system and periodontium^[5]. Several authors^[1,3,5-9] have compared the efficacy of various obturation techniques, both in-vivo and in-vitro, using a number of diagnostic modalities like radiographs^[5,8,9], spiral CT^[3], CBCT^[1], dye penetration^[7] and radioisotopes, etc. Cone Beam Computed

Tomography (CBCT) is a diagnostic imaging modality which renders high-quality and accurate three-dimensional (3D) representations of orofacial, dental and osseous structures. CBCT systems now available provide small field of view (FOV) images at low radiation dose with sufficient spatial resolution to be used for the purpose of endodontic diagnosis, treatment guidance, and post-treatment evaluation.^[10,11]

In the pursuit of an ideal obturation technique for pulpectomy, this study was designed with the aim to evaluate and compare the efficacy of 3 commonly employed obturation techniques in primary molars three-dimensionally, using Cone Beam Computed Tomography, under in-vivo conditions.

Materials and Methods

Study Design. The present Double Blinded Clinical Trial was conducted on forty healthy children (29 males and 11 females) in the age range of 4-8 years (with a mean age = 6.22 years), who received single-visit pulpectomy in their primary mandibular molars (total 60 teeth), in the Department of Pedodontics and Preventive Dentistry, Kalinga Institute of Dental Sciences, Bhubaneswar, Odisha.

Ethical Considerations. This research proposal was approved by the Institutional Ethics Committee of Kalinga Institute Of Medical Sciences, KIIT Deemed To Be University, Bhubaneswar (Approval No.-KIMS/KIIT/IEC/80/2016). All procedures were performed in accordance with Institutional Ethics and Research committee. Before initiating the treatment, the procedure, its benefits, risks, radiation hazards and the necessary radiation safety measures to be taken were explained in details to the parents and their written informed consent was taken. The patients and parents were blinded by not being provided any information about the treatment group allocated.

2.3 Selection of Sample. Children reporting to the outpatient department with complaints of pain and/or decay in their primary mandibular molars, indicated for endodontic intervention were included in this study. Diagnostic Intraoral periapical radiographs were taken to assess the caries extent, pulpal exposure and the intra-bony status of the tooth. According to the empirical data available from literature based on previously performed in-vitro study^[1], the sample size was determined to be 60. A total of 60 primary teeth were selected (28 first primary mandibular molars and 32 second primary mandibular molars, in 40 children) based on the following inclusion criteria :

Inclusion Criteria

- 1.History of spontaneous or intermittent pain
- 2.Deep dentinal caries/ pulpal exposure with restorable crown structure
- 3.No gingival/ vestibular swelling or sinus opening or abnormal mobility
4. Absence of any radiographic pathologies in periapical or interradiolar areas or internal/ external root resorption.

Exclusion Criteria

- 1.Children who are medically compromised
- 2.Children with known allergy to zinc oxide eugenol
- 3.Teeth with greater than half root resorption

Randomization. A simple randomization technique was followed to allocate the teeth into three different groups with 20 teeth in each group by a single trained disinterested investigator by drawing lots per tooth and not per patient. If a child had more than one tooth indicated for pulpectomy, lots were drawn for each tooth separately while performing the procedure. Allocation concealment was followed by using opaque envelope. The test groups were as follows :**(Fig 1)**

Group I: Obturation using Reamer

Group II: Obturation using lentulospiral mounted on slow-speed handpiece

Group III: Obturation using Endodontic Pressure Syringe

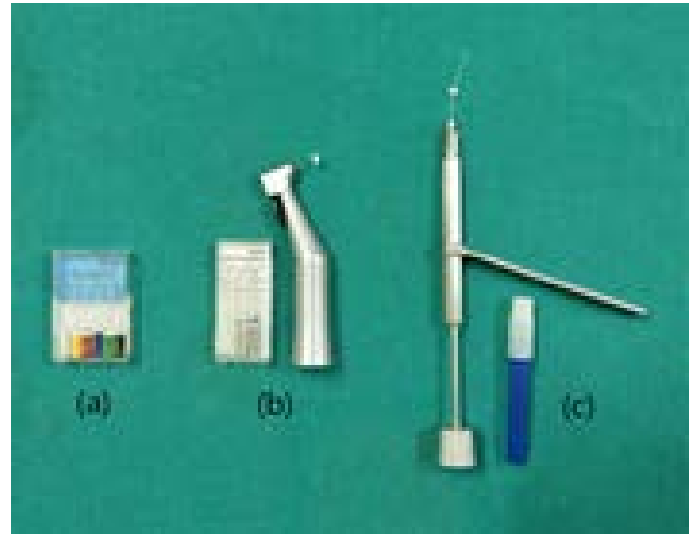

Fig 1: Three Obturation Systems : (a)Reamer, (b)Lentulospiral And (c)Endodontic Pressure Syringe

Clinical Procedure. Pulpectomy procedures were performed by a single experienced clinician and completed in single appointment. Standard protocol was followed to complete the procedure under rubber dam isolation and local anaesthesia. Working length was maintained 1mm short of the radiographic apex^[5]. Root canals were prepared using selective filing technique^[12], upto size 30 K-file. Canals were obturated using Zinc oxide eugenol (ZOE) paste with different consistencies for different groups^[6]. According to Aylard and Johnson^[6], the differences in the consistencies of Zinc Oxide-Eugenol mixtures are attributable to the physical limitations of the various techniques, hence the same ratio for the mixture could not be used in every obturation technique. The powder-liquid ratio was standardized as follows for each technique, as specified by Aylard and Johnson^[6], to minimize any discrepancy occurring due to variation in the consistency of the mix:

- For Group I : Reamer- 0.400ml eugenol liquid for 1gm of ZOE powder

- For Group II : Lentulospiral- 0.400ml eugenol liquid for 1gm of ZOE powder

- For Group III : Endodontic Pressure Syringe- 0.275ml eugenol liquid for 1gm of ZOE powder

Zinc Oxide powder was measured using a single pan electrical weighing machine and the corresponding amount of eugenol liquid was dispensed using a tuberculin syringe, following which the mixture was spatulated on a dry glass slab at room temperature for 45 seconds. A homogeneous mixture of ZOE was freshly mixed for each technique and the paste was transported into the pulpectomized root canals using instruments as per the allocated group:

Group I: Reamer: A 21mm reamer of size 20 was used to deliver the freshly mixed ZOE paste into the canal by rotating it in a clockwise direction while inserting and anti-clockwise while withdrawing after pumping it up and down, allowing the material to remain inside the canal. This was repeated till the canal orifice was visibly filled with ZOE.

Group II : Lentulospiral: A size 25 lentulospiral of 21mm length, mounted on a micro-motor handpiece, with a rubber stop adjusted 1mm short of the apex, was used to deliver ZOE mixture by rotating in a clockwise direction at 1000 RPM and then withdrawing while still rotating till no more paste could be introduced.

Group III : Endodontic Pressure Syringe: The endodontic pressure syringe (Pulpdent corporation®, Massachusetts, USA) operates mechanically by a screw mechanism expressing the paste through the fine needle. A 30 gauge needle was used to deliver ZOE paste into the canal in such a way that it would wedge snugly in the apical portion, 2mm short of the working length as per manufacturer's recommendations. The screw piston of the syringe is rotated clockwise while withdrawing the needle slowly. The needle was withdrawn completely when

backfill of the mix was observed from canal orifice. Access cavity was filled with IRM (Dentsply Sirona, Charlotte NC, USA) The tooth was restored with composite and stainless steel crown was cemented at a later appointment.

Assessment of the obturation by CBCT: Cone Beam Computerized Tomography (CBCT) scan was performed immediately after the pulpectomy procedure in the Department of Oral Medicine and Radiology, taking proper radiation safety measures for the child. Radiologist, who was blinded to the allocation group evaluated the scan images. These CBCT scans were performed using Hyperion X9 digital imaging system (MyRay, Imola, Italy) using the recommended scanning protocol. Each canal, i.e. Mesio Buccal(MB), Mesio lingual(ML), Distobuccal(DB) and Distolingual(DL), was analyzed and scored in accordance to the evaluation criteria as follows.(Fig 2)

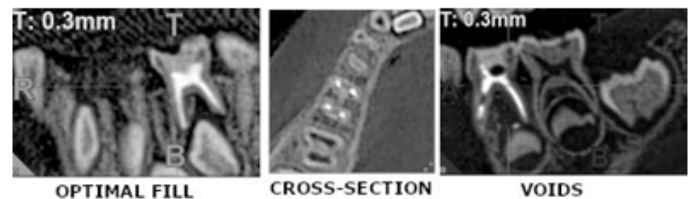


Fig 2 : CBCT Scans Used For Assessment And Scoring : (a.) Optimal Fill (b.) Cross-Section (c.) Voids

Evaluation Criteria

Qualitative assessment

Extent of fill (Based on Assessment criteria of Guelmann et al^[5]):-Score 1 : Half-filled- material extending till half of the canal length from orifice

Score 2 : Underfilled- material extending 2-3mm short of radiographic apex

Score 3 : Optimally Filled- material extending till radiographic apex or upto 1mm short of the apex.

Score 4 : Overfilled- material extending beyond the apex.

Quantitative Assessment

Voids- Presence/ absence of voids, identified as distinct radiolucent areas present within the radiopaque ZOE in the canals were assessed which determined the homogeneity of the fill quantitatively.

The samples were re-examined by a second blinded and calibrated observer to ascertain the inter-examiner reliability. The inter-examiner consistency was found to be 85% ($\kappa = -0.852$).

Statistical Analysis. Statistical analysis was done using SPSS Version 22.0 (Chicago Inc., USA) software. Specific statistical tests viz: Chi-square test, Student’s t-test, One way ANOVA and Post-hoc Tukey analysis were applied to ascertain statistical significance of the

Table 1: Distribution of number of canals evaluated in three different groups

	Mesiobuccal	Mesio-lingual	Disto-buccal	Disto- lingual	TOTAL
Group I Reamer	19	16	20	20	75
Group II Lentulospiral	20	17	19	19	75
Group III Pressure Syringe	19	20	20	20	79
Total	58	53	59	59	229

Table 1 displays the distribution of number of obturated canals included (MB, ML, DB, DL) for evaluation in all three groups. Canals which were determined to be unfilled

Extent of obturation

Table 2: Evaluation of extent of fill (all four canals combined) in different groups

Groups	All Four Canals			
	Half-filled	Underfilled	Optimally-filled	Overfilled
Group I Reamer (N=75)	7(9.33%)	19(25.33%)	42(56%)	7 (9.33%)
Group II Lentulospiral (N=75)	5 (6.66%)	23(30.66%)	36 (48%)	11 (14.66%)
Group III Pressure Syringe (N=79)	6 (7.6%)	18(22.7%)	32 (40.5%)	23 (29.2%)
Total	18 (7.8%)	60(26.3%)	110 (48%)	41 (17.9%)
Chi Square Value	12.3			
p-Value	0.05 (S)			

comparisons. The confidence level of the study was kept at 95%, hence a “p” value less than 0.05 indicated a statistically significant association.

Results & Discussion

Out of 60 teeth evaluated(28 first primary mandibular molars and 32 second primary mandibular molars), 31 had separate DB and DL canals and 29 had single united canals in their distal roots. However, for the sake of simplification of statistical analysis, the united canals were considered as separate DB and DL canals as evaluated from three dimensions.

or less than half-filled during CBCT assessment, were excluded from evaluation.

Quality of obturation observed under CBCT with three different obturation techniques is displayed in **Table-2**. Highest percentage of optimally filled canals were seen in Group I (56%) followed by Group II (48%) and Group III (40.5%). In contrast, underfilled and half filled(combined) canals were more prevalent in Group II (37.32%) and overfilled in Group III(29.2%) and these values were statistically significant($p=0.05$) when compared amongst the groups.

Further analyzing the data with respect to separate canals (**Table 3**), a similar trend of optimal level of obturation, was observed in DB, DL and ML canals, except MB canals when compared between the groups. MB canals however displayed least number of optimally filled canals in all the groups evaluated.

Table 3 : Canal-wise distribution of extent of fill in different groups :

Mesiobuccal Canals				
Groups	Half- filled	Under- filled	Optimally- filled	Over- filled
Group I Reamer (N=19)	4(21.05%)	8 (42.11%)	6 (31.58%)	1(5.26%)
Group II Lentulospiral (N=20)	2 10%)	11(55%)	7(35%)	0 (0%)
Group III Endodontic Pressure Syringe (N=19)	4(21.05%)	8 (42.11%)	7(36.84%)	0(0%)
Total (N=58)	10(17.24%)	27 (46.55%)	20 (34.48%)	1(1.73%)
Chi Square Value	3.528			
p-Value	0.740 (NS)			

Groups	Mesiolingual Canals			
	Half- filled	Under- filled	Optimally- filled	Over- filled
Group I Reamer (N=16)	1 (6.25%)	5 (31.25%)	8 (50%)	2 (12.5%)
Group II Lentulospiral (N=17)	3 (17.6%)	5 (29.43%)	7 (41.2%)	2 (11.77%)
Group III Endodontic pressure syringe (N=20)	1 (5%)	7 (35%)	8 (40%)	4 (20%)
Total (N=53)	5 (9.44%)	17 (32.08%)	23 (43.39%)	8(15.09%)
Chi Square Value	2.647			
p-Value	0.852(NS)			

Groups	Distobuccal Canals			
	Half-filled	Under- filled	Optimally-filled	Over- filled
Group I Reamer (N=20)	1 (5%)	4(20%)	14(70%)	1(5%)
Group II Lentulospiral (N=19)	0	3(15.8%)	11(57.9%)	5(26.3%)
Group III Endodontic pressure syringe (N=20)	0	3(15%)	9(45%)	8(40%)
Total (N=59)	1 (1.7%)	10 (16.9%)	34(57.6%)	14(23.8%)
Chi Square Value	8.446			
p-Value	0.207(NS)			

Table 4 : Evaluation of presence of voids in different groups:

Number of voids in respective canals										Mean number of voids	
Groups	Mesiobuccal		Mesiolingual		Distobuccal		Distolingual		All four canals together		
	Absent	Present	Absent	Present	Absent	Present	Absent	Present	Mean	SD	
Group I Reamer (N=75)	13(68.4 2%)	6(31.5 8%)	11(68.7 5%)	5(31.2)	12(60)	8(40%)	12(60)	8(40%)	1.850	1.8432	
Group II Lentulo- spiral (N=75)	7 (35%)	13 (65%)	12 (70.59 %)	5(29.4 1%)	13 (68.42 %)	6 (31.58 %)	14 (73.68 %)	5 (26.32 %)	2.150	1.7554	
Group III Endodontic Pressure Syringe (N=79)	14 (73.68 %)	5 (26.32 %)	12 (60%)	8 (40%)	15 (75%)	5 (25%)	17 (85%)	3 (15%)	1.150	1.0894	
Total	34	24	35	18	40	19	43	16	1.717	1.6270	
Chi Square Value	7.13		0.535		1.04		3.17		2.061		
p-Value	0.028(S)		0.765(NS)		0.596(NS)		0.205(NS)		0.137(NS)		

3.2 Presence of voids. Presence of voids was least in Group-III with a mean value of 1.15+-1.09 per tooth and the most in Group-II(Mean: 2.15+-1.75) (**Table-4**) No significant difference was noted among the groups ($p=0.137$). When the canals were segregated, MB canals in Group-II revealed significantly more number of voids(65%) as compared to the same canals with other two groups($p=0.028$). ML,DB and DL canals displayed a varied pattern and were not consistent with the above finding.

Pulpectomy procedure involves complete removal of irreversibly inflamed or necrotic coronal and radicular pulp tissue followed by filling with a resorbable material in either single or double appointment.^[13-15] Despite the negative attitude towards retaining a primary teeth and difficulty in navigating the unpredictable root canal anatomy, pulpectomy has been reported to have success rates ranging from 75% to 96% by various authors^[16-18]. In this study, children in the age group of 4-8 years were included, carefully excluding teeth with any preoperative root resorption or any extensive periapical and interradicular radiolucencies, as these would seemingly lead to inadvertent overfilling during obturation^[20]. The canals were instrumented using selective filing technique, wherein greater pressure was maintained towards the outer wall, diminishing the risk of perforation on the inner aspect of roots.^[21] The obturating material plays a key role in determining the success of pulp therapy. Zinc Oxide Eugenol has long been in use as an obturating material^[13]. Despite, its limitations like: restricted antibacterial action, slower resorption rate, extruded material causing irritation^[15,22], authors like Coll and Sadrian^[20] have reported no correlation of ZOE pulpectomy with enamel defects and succedaneous tooth deflection. Hashish et al^[23] reported the beneficial actions of eugenol in the ZOE mix

on periapical tissues namely anti-inflammatory and analgesic effect. Calcium hydroxide-based pastes have been reported to resorb faster intracanal leading to a hollow tube effect, risking re-infection^[24] owing to which, ZOE still remains the most widely used obturating materials, provided it is used judiciously by the operator. Hence, ZOE was selected as an obturating material in this study.

Cone Beam computed tomography(C.B.C.T.) is a new revolution in pediatric endodontics which was used here for the assessment of quality of obturation from all 3 planes. With its advantages of producing thinner sections than conventional CT, lower radiation dose and faster scanning system, C.B.C.T. provides an accurate three-dimensional information which is quantifiable^[19]. The effective dose of radiation from one diagnostic C.B.C.T. scan is in the range of 40 to 68 microSeivert,^[25] which is well-within the safety limits of the annual radiation exposure levels recommended by the National Council on Radiation Protection and International Commission on Radiation Protection.

An ideal obturation method must ensure complete filling of the canal without any extrusion along with minimal or no voids and the quality of filling depends on the ability of a technique to create optimum apical seal^[5]. On comparing the extent of fill, the present study reveals the highest percentage of optimally filled canals with reamer technique (56%) which is statistically significant($p<0.005$) and is concurrent with the findings of Nagar et al,^[26] who reported 80% optimal fillings using the same technique. Maximum number of underfilled/ half-filled canals were observed with lentulospiral (37%), which is in accordance with the result of Gandhi et al ^[27] who used Calcium Hydroxide as an obturating material. Contrary to our finding, several authors^[28-33] have reported highest percentage of optimally filled canals with lentulospiral

technique. Underfilling with lentulospiral observed in our study could be attributed to reduced tactile sensation of the operator when mounted on a micromotor^[26], along with apprehension of binding it to the canal walls and therefore keeping it short of the apex. Reamer, being a hand instrument, can be pre-curved as per the canal configuration and has positive tactile sensation, hence is convenient to insert till the apex and less likely to cause either underfilling or overfilling. Endodontic pressure syringe created maximum overfilled canals (29.2%) which was found to be statistically significant ($p=0.05$), concurrent with findings of Vashista et al^[34], Grover et al^[35] and Subba et al^[36]. The authors attributed this phenomenon to the fact that since a thicker consistency of the paste is used for pressure syringe, a greater pressure is required to release the paste, leading to the extrusion of the material. Moreover, if the needle was inadvertently kept too close to the apex, (less than 2mm) an overfilling was inevitably observed. Other factors like imprecise working length determination or over-instrumentation also could contribute to overfilling.

Further segregating the data based on individual canal type, DB and DL canals displayed higher percentage of optimal fillings (45-70% & 40-70%) in all the three groups, than their mesial counterparts, MB showing the least number of optimal fillings (35-37%) amongst all. However, no single technique was found to be significantly superior than the other two techniques.

Voids in obturated canals are undesirable as they might lead to re-infection caused by leakage in the obturation and may require re-treatment.^[5,37,38] In the present study, maximum mean number of voids per tooth (2.15 ± 1.7554) were found with Lentulospiral technique and least with Pressure syringe (1.150 ± 1.0894) which was found to be statistically not significant. This finding is in accordance with that of other studies who followed either radiographic

method^[27,28,34,35] or CBCT^[39] for their assessment. The presence of voids with lentulospiral technique can be ascribed to the structure of the instrument combined with repeated removal and re-insertion during filling up of the canals leading to incorporation of voids as small irregularities. The Endodontic Pressure Syringe proved to be the best in controlling voids with maximum void-free canals similar to the findings of Subba Reddy et al^[36], Dandashi et al^[37] and Hiremath et al^[40]. This can be correlated with the design of pressure syringe; its thin, flexible metal tip provides a better reach into the curved, narrow canals close to the apex, injecting the paste uniformly and continuously, leading to a more dense and compact filling with lesser voids.^[39]

The disparity found between the results of this study and that of the previous studies could have been due to variations in the type of teeth selected, the sample size evaluated, quality of canal preparation, tip diameter of the instrument used and operator's skill. Also the technique used to evaluate the obturation has a significant impact on the assessment. In addition, the fact that this study was conducted under in-vivo conditions, might be a governing factor for the discrepancy observed, as the outcomes become highly unpredictable when performing a procedure on a child with variable cooperation ability, as compared to the results obtained from in-vitro studies performed in controlled environment.

Conclusion

Reamer technique, exhibited the highest percentage of optimally filled canals amongst the 3 groups, however did not perform well with respect to controlling voids. Though easily available and convenient to use, this technique might require operator's skills and experience to obtain optimum results, especially in narrow, curved canals. With Lentulospiral technique, underfilling was observed more frequently along with higher mean number of voids

specially in MB canals. Endodontic pressure syringe performed the best in producing homogeneously filled canals by controlling voids, nevertheless it exhibited maximum overfilling, which is undesirable. The relative complexity and the need to disassemble it repeatedly during the procedure is time-consuming. No technique out of the three, could be designated superior than the other two, each having its own pros and cons. Hence it is the operator's dexterity which ultimately governs the outcome of the treatment. C.B.C.T. proved to be an efficient tool for endodontic imaging in the present study and hence, it can be recommended for use in evaluation of quality of obturation in primary teeth.

References

1. Singh R, Chaudhary S, Manuja N, Chaitra TR, Sinha AA. Evaluation of Different Root Canal Obturation Methods in Primary Teeth Using Cone Beam Computerized Tomography. *J Clin Pediatr Dent.* 2015 Fall;39(5):462-9.
2. Pinkham JR, Casamassimo PS, Fields HW, McTigue DJ, Nowak A, eds. *Pediatric Dentistry: Infancy Through Adolescence.* 4th ed. Philadelphia, Pa: WB Saunders Co; 2005.
3. Nagaveni NB, Yadav S, Poornima P, Reddy VS, Roshan NM. Volumetric evaluation of different obturation techniques in primary teeth using spiral computed tomography. *J Clin Pediatr Dent.* ;41(1):27-31.2017
4. Salama FS, Anderson RW, Hanes MC , Barenie JT, Myers DR. Anatomy of primary incisor and molar root canals. *Pediatr Dent,* 14: 117-118, 1992.
5. Guelmann M, Mc Eachern M, Turner C. Pulpectomies in primary incisors using three delivery systems: An in vitro study. *J Clin Pediatr Dent,* 28: 323-326, 2004.
6. Aylard SR, Johnson R. Assessment of filling techniques for primary teeth. *Pediatr Dent* 1987;9:195-8.
7. Oliver CM, Abbott PV. Correlation between clinical success and apical dye penetration. *Int Endod J,* 34: 637-44, 2001.
8. Kositbowornchai S, Hanwachirapong D, Somsopon R, Pirmsinthavee S, Sooksuntisakoonchai N. Ex vivo comparison of digital images with conventional radiographs for detection of simulated voids in root canal filling material. *Int Endod J* 2006;39:287-92.
9. Sogur E, Baksi BG, Grondahi HG. Imaging of root canal fillings: A comparison of subjective image quality between limited cone-beam CT, storage phosphor, and film radiography. *Int Endod J* 2007;40:179-85.
10. Goldman M, Pearson AH, Darzenta N. Reliability of radiographic interpretations. *Oral Surg Oral Med Oral Pathol.* 1974 Aug;38(2):287-93
11. Goldman M, Pearson AH, Darzenta N. Endodontic success-Who's reading the radiograph? *Oral Surg Oral Med Oral Pathol.* 1972 Mar;33(3):432-7
12. Garcia-Godoy F. Evaluation of an iodoform paste in root canal therapy for infected primary teeth. *ASDC J Dent Child* 1987;54:30-4.
13. Dummett CO Jr, Kopel HM. Pediatric endodontics. In: Ingle JI, Bakland LK, editors. *Endodontics.* 5 th ed. Hamilton: BC Decker Inc.; 2002. p. 861-902
14. Allen KR. Endodontic treatment of primary teeth. *Aust Dent J* 1979;24:347-51.
15. Flaitz CM, et al. Radiographic evaluation of pulpal therapy for primary anterior teeth. *J Dent Child* 1989;56:182.
16. Barr ES, Flaitz CM, Hicks MJ. A retrospective radiographic evaluation of primary molar pulpectomies. *Pediatric dentistry.* 1991;13(1):4-9.

17. Ozalp N, Saroğlu I, Sönmez H. Evaluation of various root canal filling materials in primary molar pulpectomies: an in vivo study. *Am J Dent.* 2005 Dec;18(6):347-50.
18. Gould JM: Root canal therapy for infected primary molar teeth -- preliminary report. *J Dent Child* 39:269-73, 1972.
19. Scarfe WC, Levin MD, Gane D, Farman AG. Use of Cone Beam Computed Tomography in Endodontics. *Int J Dent* 2009.
20. Coll JA, Sadrian R. Predicting pulpectomy success and its relationship to exfoliation and succedaneous dentition. *Pediatr Dent.* 1996 Jan-Feb;18(1):57-63
21. Chawla H S, Setia S, Gupta N, Gauba K, Goyal A. Evaluation of a mixture of zinc oxide, calcium hydroxide, and sodium fluoride as a new root canal filling material for primary teeth. *J Indian Soc Pedod Prev Dent* 2008;26:53-8
22. Holan G, Fuks A.A comparison of pulpectomies using ZOE and KRI paste in primary molars: a retrospective study. *Pediatr Dent* 15: 403-407, 1993.
23. Hashieh IA, Ponnemel L, Camps J (1999) Concentration of Eugenol apically released from ZnO E based sealers. *J Endod* 22: 713-715.
24. Nurko C, Garcia-Godoy F. Evaluation of a calcium hydroxide/iodoform paste (Vitapex) in root canal therapy for primary teeth. *J Clin Pediatr Dent.* 1999 Summer;23(4):289-94
25. Stuart CW, Micheal JP. *Oral Radiology Principles and Interpretation.* 5th ed. Philadelphia: Mosby, Inc; 2004
26. Nagar P, Araali V, Ninawe N. An alternative obturating technique using insulin syringe delivery system to traditional reamer: An in-vivo study. *J Dent Oral Biosci.* 2011;2(2):7-9.
27. Gandhi M, Tandon S, Vijay A, Kalia G, Rathore K. Clinical Assessment of Various Obturating Techniques for Primary Teeth: A Comparative Study. *J Clin Diagn Res.* 2017;11(7):ZC48-ZC51.
28. Memarpour M, Shahidi S, Meshki R. Comparison of different obturation techniques for primary molars by digital radiography. *Pediatr Dent.* 2013 May-Jun;35(3):236-40.
29. Pandranki J, Chitturi RR, Vanga NR, Chandrabhatla SK.(2017) A comparative assessment of different techniques for obturation with endoflas in primary molars: An In vivo Study. *Indian J Dent Res* 28(1):44-48
30. Torres CP, Apicella MJ, Yancich PP, Parker MH. Intracanal placement of calcium hydroxide: a comparison of techniques, revisited. *J Endod.* 2004 Apr;30(4):225-7.
31. Peters CI, Koka RS, Highsmith S, Peters OA. Calcium hydroxide dressings using different preparation and application modes: density and dissolution by simulated tissue pressure. *International Endodontic Journal* 2005;38:889-895
32. Khubchandani M, Baliga MS, Rawlani SS, Rawlani SM, Khubchandani KM, Thosar N (2017) Comparative evaluation of different obturation techniques in primary molars: an in-vivo study. *Eur J Gen Dent* 6(1):42-47
33. Walia T, Ghanbari AH, Mathew S, Ziadlou AH. An in vitro comparison of three delivery techniques for obturation of root canals in primary molars. *Eur Arch Paediatr Dent.* 2017 Feb;18(1):17-23.
34. Vashista K, Sandhu M, Sachdev V. Comparative Evaluation of Obturating Techniques in Primary Teeth: An in vivo Study. *Int J Clin Pediatr Dent.* 2015;8(3):176-80.

35. Grover R, Mehra M, Pandit IK, Srivastava N, Gugnani N, Gupta M. Clinical efficacy of various root canal obturating methods in primary teeth: a comparative study. *Eur J Paediatr Dent.* 2013 Jun;14(2):104-8
36. Subba Reddy VV, Shakunthala B. Comparative assessment of three obturating techniques in primary molars: An in-vivo study. *Endodontology* 1997;9:13-6.
37. Dandashi MB, Nazif MM, Zullo T, Elliott MA, Schneider LG, Czonstkowsky M. An in vitro comparison of three endodontic techniques for primary incisors. *Pediatr Dent.* 1993 Jul-Aug;15(4):254-6.
38. Kahn FH, Rosenberg L, Schertzer G, Korhals. An in vitro evaluation of sealer placement methods. *Int Endod J* 1997; 30:181-6.
39. Singh A, Gupta N, Agarwal N, Kumar D, Anand A. A Comparative Volumetric Evaluation of Four Obturating Techniques in Primary Teeth Using Cone Beam Computed Tomography. *Pediatr Dent.* 2017 Mar 15;39(2):11-16.
40. Hiremath MC, Srivastava P. Comparative evaluation of endodontic pressure syringe, insulin syringe, jiffy tube, and local anesthetic syringe in obturation of primary teeth: An in vitro study. *J Nat Sc Biol Med* 2016;7:130-5.