

Implant failures- a case report

¹Dr.Swapnita Vaity, Post-graduate student, Department of Prosthodontic, D. Y. Patil, University, School of Dentistry

²Dr. Omkar Shetty, Dean, Professor, Department of Prosthodontic, D. Y. Patil University, School of Dentistry

³Dr. Gaurang, Mistry, Head of Department, Department of Prosthodontic, D. Y. Patil University, School of Dentistry.

⁴Dr. Ashwini Kini, Associate Professor, Department of Prosthodontic, D. Y. Patil University, School of Dentistry

Corresponding Author: Dr. Swapnita Vaity, Post-graduate student, Department of Prosthodontic, D. Y. Patil University, School of Dentistry

Citation of this Article: Dr.Swapnita Vaity, Dr. Omkar Shetty, Dr. Gaurang, Mistry, Dr. Ashwini Kini,“Implant failures-a case report”, IJDSIR- August - 2020, Vol. – 3, Issue -4, P. No. 517 – 524.

Copyright: © 2020, Dr. Swapnita Vaity, et al. This is an open access journal and article distributed under the terms of the creative commons attribution noncommercial License. Which allows others to remix, tweak, and build upon the work non commercially, as long as appropriate credit is given and the new creations are licensed under the identical terms.

Type of Publication: Case Report

Conflicts of Interest: Nil

Abstract

Background: Somatic gag reflex is a condition that commonly occurs in dental treatment especially in prosthodontics procedures and while taking intraoral periapical radiographs at either maxillary or mandibular posterior teeth. Patients who are sensitive to foreign matter inserted to the oral cavity, can generate feeling of gag/nausea or even vomiting, in sudden. This situation is difficult to be controlled by either the patient or the dentist. The somatic gag reflex depends on the integrity of the glossopharyngeal and the vagus nerves. Clinical manifestation of somatic gag reflex varies in each individual so that the management is different from one another, because of it has never been a ‘one-size-fits-all management’.

Conclusion: Somatic gag reflex is a gag reflex triggered by a stimulus in the "trigger zone" area, namely the posterior 1/3rd of tongue, palatine tonsils and pharynx. The gag reflex has a sensory limb from the

glossopharyngeal nerve and a motor limb from the vagus nerve. The management of somatic gag reflex in some of dental treatment procedures varies in each individual. In the top of that, the dentist need to minimize the sensory stimulus carried by the glossopharyngeal nerve.

Keywords: Somatic Gag Reflex, Dental Treatment Procedures, Glossopharyngeal Nerve.

Introduction

Gag reflex is a normal mechanism under the parasympathetic division of the autonomic nervous system. ^[1] As a normal defense, the gag reflex aims to prevent the foreign matter enter into the trachea.^[2] Once gag reflex has occurred/generated, the contraction of the posterior pharynx leads to narrowing pharynx wall, in which also referred to pharyngeal reflex.^[3&4]

The etiology of the gag reflex can be categorized as somatic, psychological or a combination of both. Somatic responses occur in response to intraoral physical stimulation.^[5] In somatic gag reflex, there are five areas

called "trigger zones" namely: (1) the palatoglossal arch, (2) the palatopharyngeal arch (3) the posterior 1/3rd of tongue, (4) the palate, (5) the uvula, and (6) the posterior pharynx wall. Physical stimulation in these zones will trigger to gag reflex as somatic response.^[6&7] The somatic gag reflex depends on the integrity of the glossopharyngeal nerve (CN IX) and the vagus nerve (CN X). In psychological gag reflex can occur without direct physical contact even it can be induced through visual, smell or sound of instruments and materials used by dentists. The worst psychological condition is when a patient has assumed that dental treatment may generate gag.^[6&8]

Somatic gag reflex is a condition which is commonly found during dental treatment. Individuals with normal to mild gag reactions can occasionally gagging in difficult treatments, but generally the gag reflex is still under patient control. Whereas some individuals with severe gag reflex tend to endanger dental treatment and create difficulty for patients and dentists. Thereby, special measures are required. In this review, we will discuss about the role of the glossopharyngeal and vagus nerves in the somatic gag reflex and the anatomic principles for preventing the somatic gag reflex in some of dental treatment procedures.

Literature review

Communication of glossopharyngeal and vagus nerves in somatic gag reflex

The name glossopharyngeal refers to Latin, glosso (tongue) and pharynx (the beginning of the digestive tract), this name is given in accordance with the target function. Vagus, is a Latin adjective which means wandering or roving. The naming of the vagus nerve is in accordance with its very wide range of afferent and efferent innervation.^[9] The involvement of these two nerves in the gag reflex needs to be discussed together as

they come out of the medulla oblongata side by side. The vagus nerve fibers are located in between the glossopharyngeal nerve fibers and the accessory nerve (CN XI), and leaving the cranial cavity through the nerve parts of the jugular foramen.^[10] The glossopharyngeal nerve is a smaller nerve bundle compared to the vagus nerve, but has a similar functional and anatomical distribution, and often overlaps peripherally. These nerves are connected to many of the same brain stem nuclei (nucleus ambiguus, solitary nucleus, spinal nucleus of the trigeminal) and are often damaged together.^[11&12] Nucleus ambiguus is a long cell column in the medulla oblongata, and is a source of branchiomotor fibers (special somatic efferent) in the glossopharyngeal and vagus nerves that serve the speech and swallowing muscles.^[13&14]

The glossopharyngeal nerve supplies bilaterally and has sensory, parasympathetic, and motoric components. The sensory fibers, originating from the solitary nucleus, receive impulses from the posterior 1/3rd of tongue, palatine tonsils, pharynx, middle ear, carotid body, carotid sinus and their afferent taste/gustatory fibers receive impulses from the posterior 1/3rd of tongue. The parasympathetic fibers are derived from the inferior salivatory nucleus, supplies secretomotor innervation to the parotid gland. The branchiomotor fibers of glossopharyngeal nerve innervates the stylopharyngeus muscle.^[15&16]

The vagus nerve has the same components as the glossopharyngeal nerve. In the gag reflex, the vagus nerve has 3 bilateral motor innervation from the ambiguus nucleus, namely: (1) pharyngeal branch, which innervates the soft palate muscles (muscles of the palatopharyngeal, palatoglossal, uvula) and pharyngeal constrictor muscles, (2) the superior laryngeal nerve, which innervates the inferior pharyngeal constrictor muscle and the cricothyroid muscle of the larynx, and (3) the recurrent

laryngeal nerve branch innervates the other intrinsic larynx muscles.^[15&16]

The pharyngeal branch (sensory) of the glossopharyngeal nerve communicate and join with the pharyngeal branch (motor) of the vagus nerve, and they form the pharyngeal plexus together with the sympathetic fibers (vasomotor) of the superior cervical ganglion. Through the pharyngeal plexus, the glossopharyngeal nerve receive sensory information from the nasopharynx and oropharynx mucosa and the vagus nerve provides motor innervation to the soft palate muscles and pharynx muscles.^[17] Because of the mixing of the two cranial nerve fibers mentioned above in the pharyngeal plexus, it is difficult to determine a pure lesion of the glossopharyngeal nerve.

Damage to the glossopharyngeal nerve often occur together with damage to the vagus nerve and radix of the accessory nerves in the jugular foramen.^[18] Single damage of the glossopharyngeal nerve is very rare.^[19] Lesions of the glossopharyngeal nerve will induce: (1) sensitivity reduction of taste over the posterior 1/3rd of tongue, (2) loss of gag and palatal reflexes, (3) impaired sensation over the posterior 1/3rd of tongue, upper pharynx, tonsils (4) mild difficulty in swallowing, (5) parotid gland dysfunction and (6) glossopharyngeal neuralgia.^[20]

Unilateral damage to the vagus nerve causes paralysis of the pharynx muscles on the affected side, so that the palate on the affected side descends which is then followed by the rise of the palate and uvula to the healthy side during phonation. In addition, homolateral paralysis can occur in the muscles of the larynx and vocal cords (nasal sounds appear), minor dysphagia, tachycardia and arrhythmia. Unilateral vagus nerve disorders usually does not result in swallowing disorders. However, bilateral lesions may cause dysphagia and regurgitation fluid from the nose.^[20&21]

^[20&21]

Gag reflex mechanism

The characteristics of reflex is an involuntary rapid response, while the reflex arc is the shortest path of reflex motion. The gag reflex is protective and is equipped with three of the motor response, namely: elevation of the soft palate to close the nasopharynx, glottic closure to protect the airway, and constriction of the pharynx to prevent the foreign matter enter the pharynx.^[22] The glossopharyngeal nerve and vagus nerve control the gag reflex which have function as sensory limb (afferent) and motor limb (efferent) within the reflex arch, respectively (Figure 1). Sensory stimulus from the posterior pharynx wall, palatine tonsils, or posterior third of the tongue carried by the sensory limb (glossopharyngeal nerve) to the ipsilateral of the solitary nucleus after synchronizing in the superior ganglion inside of the jugular foramen. After that, this nucleus sends fibers to the nucleus ambiguus inside of the superior (rostral) medulla. Then from the nucleus ambiguus, the motor limb (vagus nerve) transmits the motor stimulus to the pharyngeal constrictor muscles. As a motor response, it stimulates the oropharynx to narrow and elevate leading to the elevation of the midline of the palatine raphe and uvula, followed by the constriction of the pharyngeal constrictor muscles.^[23&24]

Some literatures distinguish the pharyngeal reflex (gag reflex) from the palatal reflex. The pharyngeal reflex can be observed by touching the posterior wall of the pharynx using a tongue blade, applicator or other similar blunt object. Whereas, the palatal reflex can be stimulated by touching one side of the soft palate or uvula. The pharyngeal reflex is more active than the palatal reflex.^[25&26] Soft palate stimulation can trigger a similar gag reflex. But in this case, the sensory limb originates from the trigeminal nerve (CN V) which transmits the sensory stimulus from the soft palate through the spinal nucleus of the trigeminal nerve^[24]

The gag reflex is a superficial and simple reflex which may happen in normal individual. Based on this, the gag reflex can be used for assessing the damage to the glossopharyngeal nerve and vagus nerve. Both nerves are normally examined at the same time due to difficulty when testing separately.^[27] The operator need to clearly explain the examination procedure to the patient, because it will cause an uncomfortable reaction. Touching the posterior pharynx wall on one side, gently, using the tongue blade while opening the mouth induces the sensory limb on the pharynx to send a sensory stimulus which then generate a gag reflex. Normally, patient generates a gag reflex. Nevertheless, the severity level is various among normal individual which may exhibit hyperactive effect or even severe vomiting.^[28&29]

Gag reflex during dental treatment is very disruptive to the patient and hinder the work of the dentist. Patients who are sensitive to foreign matter inserted to the oral cavity, can generate feeling of gag/nausea or even vomiting, in sudden. This situation is difficult to be controlled by either the patient or the dentist. The assessment of the gag reflex severity can be measured using the Gagging Severity Index (GPI)^[30,31] (presented in Table 1).

Saravanan et al., have treated a 38-year-old female patient with a chief complaint of gag sensation after wearing a full maxillary denture.^[32] Murthy et al., have treated a 30-years-old patient who could not be treated by a dentist before, because of suffering from severe gagging.^[33] Another case report has been presented by Hotta about a 60-year-old male patient who comes with a chief complaint of inability in inserting his dentures due to a hyperactive gag reflex. Because of patient has been tending to has a feeling of gag while brushing his teeth since childhood, he rarely went to see a dentist. As a result, he has suffered from a lot of tooth decay and required an tooth extraction treatment, when he was 20

years old.^[34] Moreover, Singh and Gupta, reported that a 55-year-old man had experienced severe gag reflex, resulting in difficulty in inserting his denture inside his mouth.^[35]

Malkoc et al., reported the difficulty of taking impression procedure on patients: 50-year-old female patients weighing 65 kg, 15-year-old pediatric patients weighing 56 kg and 11-year-old pediatric patients weighing 45 kg. These patients had experienced hyperactive gag reflex while taking impression.^[36] Choudhary et al., reported that gag reflex most often occur during intraoral periapical radiograph performed on the maxillary and mandibular third molar teeth.^[37] Silva et al., reported a similar difficulties while taking intraoral radiographs in 28-year-old male patients who had experienced a gag reflex on previous intraoral periapical radiographs-taking; and 28-year-old female patients with gag reflex accompanied by trismus.^[38]

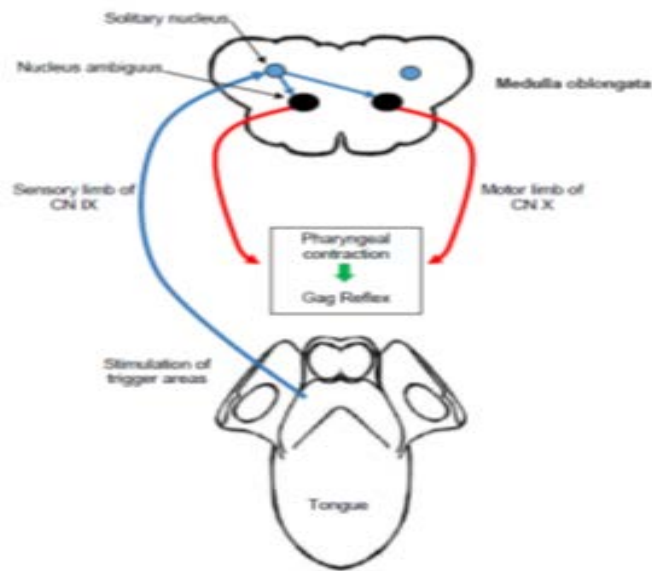


Figure 1: Gag reflex pathway

Table 1:Gagging Severity Index (GSI)³⁰

Grade I	Normal Gagging Reflex which occurs very occasionally, and are under the patient's control
Grade II	Mild Gagging Reflex which occurs occasionally, and still can be controlled again by the patient, may require assistance and vigilance dentists and dental nurses
Grade III	Moderate Gagging Reflex which occurs routinely and consistently, especially if physical touch is applied to the high-risk trigger area. It is difficult for patients to control it without stopping dental treatment procedures.
Grade IV	Severe Gagging Reflex which occurs with all types of dental treatment procedures including regular visual inspection, dental treatment procedures is not possible without special care to control the problem of gagging.
Grade V	Very Severe Gagging Reflex which occurs easily even without any physical intervention, dental treatment procedures is not possible without special care to control the problem of gagging.

Discussion

Gag reflex can be used as a simple assessment method to evaluate glossopharyngeal nerve and vagus nerve function. If there is a sensory disturbance in the glossopharyngeal nerve, touch on the damaged side will not give a motor response. A damaged vagus nerve resulted in the elevation of soft palate toward the normal side, regardless of the side of the pharynx that is touched. Whilst, if unilateral damage occurs to both nerves at once, the vomiting reflex examination shows a unilateral response accompanied by soft palate deviation, being

pulled toward the normal side when touched. In contrast, the touch on the damaged side does not produce any response at all.^[11,18]

Somatic gag reflex can occur in the presence of a trigger on trigger zone for initiating the gag reflex. Somatic gag reflex, can be distinguished one from the other. Therefore, gag reflex management among patient is different, because there has never been a ‘one-size-fits-all management’.^[39] Gag reflex most commonly occurs in prosthodontics procedures.^{40&41} and intraoral periapical radiographs-taking in the maxillary and mandibular posterior teeth.^[37]

Saravanan et al., have modified the maxillary impression technique using the mandibular edentulous trays. During the impression procedure, the patient is given acupressure at the Yintang point which is located in the middle of the medial end of the eyebrow. Initially, the gag reflex level showed at grade III (moderate) based on the Gagging Severity Index (GSI) but after combining with acupuncture, it facilitated a reduction of gag reflex from grade III to grade II (based on GSI) meaning that acupuncture provides effective therapeutic effect in controlling gag reflex and may act as an additional therapy for achieving satisfactory during dental treatment.^[32]

In another study, Murthy et al., gave an anesthetic block injection of the glossopharyngeal nerve in the palatopharyngeal arch with a 2% lignocaine solution containing 1: 200000 epinephrine. It facilitates a successful in the tooth preparation procedure for fixed partial denture and jaw impression and gives a comfortable feeling in dental patient.^[33] Hotta, reduced the plate area of removable denture to be smaller than usual in order to lowering the intensity of the severe gag reflex. The palatal area of denture is made only till the premolar area, in order to reduce physiological contact which subsequently reduce contact between the acrylic

denture plate and the palate. He also instructed the patient to stimulate his oral mucosa so that a gradual adaptation between denture and oral mucosa was obtained.^[34]

Singh and Gupta, create a modification of the dentures in the form of a palateless bar supported overdenture. This modification was successfully accepted by patients with severe gag reflex triggered while using old prostheses made of acrylic resin.^[35] Malkoc, et al., found difficulty when taking impression on his patient, so that he gave 2.5 mg of intranasal midazolam which was applied gradually in both nostrils. Within five minutes, the patient did not showed any gag reflex symptom anymore, and has no side effects afterwards. The advantages of anesthetic application through nasal is to facilitate a quick absorption and rapid effect to the systemic circulation system.^[36]

The other study, Choudhary et al., devised an alternative technique for taking up periapical radiographs of the maxillary and mandibular third molars. The intraoral periapical film is placed parallel to the occlusal plane, as the same as making an occlusal radiograph with the protruded dot side facing towards the desired tooth. This method resulting in good quality of radiographic image of the whole third molar without stimulating the gag reflex which is subsequently provide satisfactory for either dentist and patient.^[37] Silva et al., achieved a deal with patients who are intolerant of intraoral periapical films. He modified an extraoral radiographic techniques as an alternative approach during root canal therapy in patients with severe gag reflex.^[38] Moreover, Reshetnikov et al., reported a successful outcome in eliminating excessive gag reflex, through performing intravenous regional anesthesia with dexmedetomidine sedation in dental patient who exhibits psychological factor such as anxiety and fear (grade IV, GSI).^[42]

All reported cases of gag reflexes in patients during dental treatment that have been discussed above, mostly included

in somatic gag reflexes which are in Grade I, II and III of GSI. In cases of hypersensitive (Grade III, GSI) gag reflex can be triggered by very strong motor response to touch stimulation, or by very high sensitivity to sensory stimuli in trigger zone leading to the gag reflex. Somatic gag reflex control requires management strategies that vary among dental patient. Based on this, the anatomical principle for preventing gag reflex is required to minimize sensory stimulus to the glossopharyngeal nerve, by designing various modification in dental treatment.

Conclusion

Somatic gag reflex is a gag reflex caused by a stimulus in the "trigger zone" area, namely the posterior 1/3rd of tongue, palatine tonsils and pharynx. The gag reflex has supplied by sensory limb from the glossopharyngeal nerve and motor limb from the vagus nerve. The management of somatic gag reflex in dental treatment procedures varies from one another. In the top of that, the dentist need to minimize the sensory stimulus carried by the glossopharyngeal nerve.

References

1. Goyal G. Gag Reflex: Causes and Management. Int J Dent Med Res. 2014;1(3):163-166.
2. Shin S, Kim S. Dental treatment in patients with severe gag reflex using propofol-remifentanyl intravenous sedation. J Dent Anesth Pain Med. 2017;17(1):65-69.
3. Scarborough D, Bailey-Van Kuren M, Hughes M. Altering the gag reflex via a palm pressure point. J Am Dent Assoc. 2008;139:1365-1372.
4. Miller AJ. Oral and pharyngeal reflexes in the mammalian nervous system: Their diverse range in complexity and the pivotal role of the tongue. Crit Rev Oral Biol Med. 2002;13(5):409-425.
5. Raj A. N, Kumar S, Vora N, Raju MV. Gag Reflex: A dentist's Perspective. Int J Adv Sci Res.

- 2015;1(04):176-178.
6. Gupta R, Bharat A, Dhiman U. Gagging : Revisited. *J Oral Care Dent.* 2018;1(1):1-6.
 7. Cox L, Brindley J. Exploring alternative methods of gag reflex control Part 1: Acupressure. *BDJ Team.* 2017;(17059):7-11.
 8. Debs NN, Aboujaoude S. Effectiveness of intellectual distraction on gagging and anxiety management in children: A prospective clinical study. *J Int Soc Prev Community Dent.* 2017;7(6):315-320.
 9. Hermanowicz N. Cranial Nerves IX (Glossopharyngeal) and X (Vagus). In: Goetz C, ed. *Textbook of Clinical Neurology.* 3rd ed. Elsevier-Health Sciences Division; 2007:217-229.
 10. Linn J, Peters F, Moriggl B, Naidich TP, Brückmann H, Yousry I. The jugular foramen: Imaging strategy and detailed anatomy at 3T. *Am J Neuroradiol.* 2009;30:34-41.
 11. Reeves AG, Swenson RS. Lower cranial nerve function. In: Swenson R, ed. *Disorders of the Nervous System, A Primer.* Dartmouth Medical School online version; 2004:99-110.
 12. Schuenke M, Schulte E, Schumacher U. Persarafan Kepala dan Leher. In: Anggraini W, ed. *Anatomi Kedokteran Gigi-Kepala & Leher.* Bahasa Ind. Penerbit Buku Kedokteran EGC; 2015:66-91.
 13. Walker HK. Cranial Nerves IX and X: The Glossopharyngeal and Vagus Nerves. In: Walker HK, Hall WD, Hurst JW, eds. *Clinical Methods: The History, Physical, and Laboratory Examinations.* 3rd ed. Butterworth-Heinemann; 1990:327-328.
 14. Petko B, Tadi P. Neuroanatomy, Nucleus Ambiguus. StatPearls [Internet]. Published 2019. Accessed May 28, 2020. <https://www.ncbi.nlm.nih.gov/books/NBK547744/>
 15. Gillig PM, Sanders RD. Cranial nerves IX, X, XI, and XII. *Psychiatry (Edgemont).* 2010;7(5):37-41.
 16. Erman AB, Kejner AE, Hogikyan ND, Feldman EL. Disorders of cranial nerves IX and X. *Semin Neurol.* 2009;29(1):85-92.
 17. Thomas K, Minutello K, Das JM. Neuroanatomy, Cranial Nerve 9 (Glossopharyngeal). StatPearls [Internet]. Published 2020. Accessed May 24, 2020. <https://www.ncbi.nlm.nih.gov/books/NBK539877/>
 18. Haines DE, Mihailoff GA. A Synopsis of Cranial Nerves of the Brainstem. In: *Fundamental Neuroscience for Basic and Clinical Applications.* 5th ed. Elsevier Health Sciences; 2018:195-211.
 19. Savarimuthu MK, Nair AK. A Case of Isolated Unilateral Glossopharyngeal Nerve Palsy. *Clin Med Res.* 2020;18(1):37-41.
 20. Sarrazin J-L, Toulgoa F, Benoudiba F. The Lower Cranial Nerves: IX, X, XI, XII. *Diagn Interv Imaging.* 2013;94(10):1051-1062.
 21. Howlett W. Cranial Nerve Disorders. In: *Neurology In Africa Clinical Skills and Neurological Disorders.* University of Bergen; 2012:305-306. www.uib.no/cih/en/resources/neurology-in-africa
 22. Kaira LS, Dabral E, Kukreja HS. Gagging A Review. *J Heal Allied Sci NU.* 2014;4(1):149-155. d
 23. Finsterer J, Grisold W. Disorders of the lower cranial nerves. *J Neurosci Rural Pract.* 2015;6(3):377-391.
 24. Sivakumar S, Prabhu A. Physiology, Gag Reflex. StatPearls [Internet]. Published 2020. Accessed May 25, 2020. <https://www.ncbi.nlm.nih.gov/books/NBK554502/>

25. Campbell WW. DeJong's The Neurologic Examination. 7th ed. Lippincot Williams & Wilkins; 2013.
26. Valbuza JS, Oliveira MM de, Conti CF, Prado LBF, Carvalho LBC, Prado GF do. Oropharyngeal examination as a predictor of obstructive sleep apnea: pilot study of gag reflex and palatal reflex. Arq Neuropsiquiatr. 2011;69(5):805-808.
27. Izumi-Richard N. Neurological Assessment. InnoVaiT. 2013;6(7):405-415.
28. Damodaran O, Rizk E, Rodriguez J, Lee G. Cranial nerve assessment: A concise guide to clinical examination. Clin Anat. 2014;27:25-30.
29. Hussain S, Battol S, Yasdanie N. Gag Reflex: Not A Dilemma Any More. Biomedica. 2016;32(4):277-280.
30. Rosted P, Bundgaard M, Fiske J, Pedersen AML. The use of acupuncture in controlling the gag reflex in patients requiring an upper alginate impression: An audit. Br Dent J. 2006;201(11):721-725.
31. Jain AR. Gagging: A problem to prosthetic dentistry - Review. Drug Invent Today. 2018;10(1):48-54.
32. Saravanan TT, Ramu C, Padmanabhan TV. An Innovative Approach To Overcome Gagging For Rehabilitating A Completely Edentulous Patient Through Acupressure –A Case Report. Int J Dent Res Dev. 2015;5(2):7-12.
33. Murthy V, Yuvraj V, Nair PP, Thomas S, Krishna A, Cyriac S. Management of exaggerated gagging in prosthodontic patients using glossopharyngeal nerve block. BMJ Case Rep. 2011;2011:1-3.
34. Hotta H. Case report of difficult dental prosthesis insertion due to severe gag reflex. Bull Tokyo Dent Coll. 2012;53(3):133-139.
35. Singh K, Gupta N. Palateless custom bar supported overdenture: A treatment modality to treat patient with severe gag reflex. Indian J Dent Res. 2012;23(2):145-148.
36. Malkoc MA, Demir N, Ileri Z, Erdur A, Apiliogullari S. Intranasal Midazolam May Prevent Gagging Reflex: a Case Report. J Oral Maxillofac Res. 2013;4(3):e5.
37. Choudhary SH, Kale LM, Mishra SS, Supe NB, Zaidi NS, Pandey ND. Modified occlusal technique using intraoral periapical film: An alternative approach. J Indian Acad Oral Med Radiol [serial online]. 2018;30(2):193-195.
38. E Silva MHC, Coelho MS, Santos MFL, De Lima CO, Campos CN. The use of an alternative extraoral periapical technique for patients with severe gag reflex. Case Rep Dent. 2016;2016:1-5.
39. Forbes-Halley C, Blewitt I, Puryer J. Dental Management of the “Gagging” Patient - An Update. Int J Dent Heal Sci. 2016;3(2):423-431.
40. Reddy CS, Gopal V. Management Of Gagging In Complete Denture Wearer-A Case Report. Ann Essences Dent. 2013;V(3):46-48.
41. Naeem A, Taseer B, Arti S, Shilpi C, Vijay K, Monu Y. Gag Reflex: A Situational Challenge. Int J Sci Res Publ. 2014;4(10):1-2.
42. Reshetnikov AP, Kasatkin AA, Urakov AL, Baimurzin DY. Management of exaggerated gag reflex in dental patients using intravenous sedation with dexmedetomidine. Dent Res J. 2017;14(5):356–358.