

A Systematic approach in rehabilitation of hemimandibulectomy: A case report

¹Dr.Nikita Gharat, MDS, Lecturer, Department of prosthodontics and crown and bridge, Terna dental college ,Navi Mumbai

³Dr.Naisargi Shah, HOD, Department of prosthodontics and crown and bridge, Terna dental college ,Navi Mumbai

³Dr.Shruti Gill, Reader, Department of prosthodontics and crown and bridge, Terna dental college, Navi Mumbai

⁴Dr.Prashant Patil, Lecturer, Department of prosthodontics and crown and bridge, Terna dental college ,Navi Mumbai

Corresponding Author: Dr.Nikita Gharat, MDS, Lecturer, Department of prosthodontics and crown and bridge, Terna dental college ,Navi Mumbai

Citation of this Article: Dr.Nikita Gharat, Dr.Naisargi Shah, Dr.Shruti Gill, Dr.Prashant Patil, “A Systematic approach in rehabilitation of hemimandibulectomy: A case report”, IJDSIR- September - 2020, Vol. – 3, Issue - 5, P. No. 332 – 339.

Copyright: © 2020, Dr.Nikita Gharat, et al. This is an open access journal and article distributed under the terms of the creative commons attribution noncommercial License. Which allows others to remix, tweak, and build upon the work non commercially, as long as appropriate credit is given and the new creations are licensed under the identical terms.

Type of Publication: Case Report

Conflicts of Interest: Nil

Abstract

Neoplasms which are associated with the mandible usually require surgical removal of the lesion and extensive resection of the bone. Following mandibular resection, restoration of normal function and form is little difficult and depends upon area and type of resection. Facial disfigurement is inevitable due to loss of hard and soft tissue and resultant deviation which often lead to difficulty in mastication, reduced self esteem, Psychosocial embarrassment and isolation. Basic rehabilitation objective is to train mandibular muscles to establish acceptable occlusal relationship and decrease amount of facial disfigurement through correction of deviation. This article describe functional rehabilitation of hemimandibulectomy patient in two phases. Primary phase concerned with correction of deviation with use of mandibular guide flange appliance and definitive phase

associated with occlusal rehabilitation with help of fixed dental prosthesis and cast partial denture.

Keywords: Hemimandibulectomy, Guide flange prosthesis, Twin occlusion, Mandibular deviation.

Introduction

Squamous cell carcinoma is a fairly common and highly aggressive odontogenic tumor of epithelial origin commonly found in posterior mandible and treated with the surgical excision of hard and soft tissues.^[1,2] Surgical resection of the mandible due to presence of any benign or malignant tumor often leads to mandibular deviation. Depending upon the location and extent of the tumor in the mandible, various surgical treatment modalities like marginal, segmental, hemi, subtotal or total mandibulectomy can be performed.^[3] Loss of mandibular continuity causes deviation of remaining mandibular segment towards the defect and rotation of the mandibular occlusal plane inferiorly. Apart from the deviation of

mandible to resected side, other dysfunctions observed are difficulty in mastication, swallowing, speech, mandibular movements, and even respiration.^[4-6]

Cantor and Curtis have classified the mandibular defects into 6 categories.^[1-3]

Class I: Mandibular resection involving alveolar defect with preservation of mandibular continuity (Fig. 1a)

Class II: Resection defects involve loss of mandibular continuity distal to the canine area (Fig. 1b)

Class III: Resection defect involves loss up to the mandibular midline region (Fig. 1c)

Class IV: Resection defect involves the lateral aspect of the mandible, but are augmented to maintain pseudoarticulation of bone and soft tissues in the region of the ascending ramus (Fig. 1d)

Class V: Resection defect involves the symphysis and parasymphysis region only, augmented to preserve bilateral temporomandibular articulations (Fig. 1e)

Class VI: Similar to class V, except that the mandibular continuity is not restored (Fig. 1f)

The basic rehabilitation objective is to re-educate mandibular muscles to re-establish an acceptable occlusal relationship (physio-therapeutic function) for residual mandible, so that patient could control adequately and repeatedly opening and closing mandibular movements.[7-10]

This case report describes prosthodontic management of a patient who has undergone a hemimandibulectomy and was rehabilitated using a provisional guide flange prosthesis followed by a definitive maxillary and mandibular cast partial denture designed with twin occlusion to fulfill the patient's needs and to stabilize occlusal relationship.

Case report

A 57 years old male patient reported to Department of Prosthodontics and Crown and Bridge, Terna dental

college, Navi Mumbai, with chief complaint of inability to eat and unaesthetic appearance. Patient gave history of resection of mandible 2 years back due to squamous cell carcinoma. Extraoral examination revealed asymmetry and disfigurement, due to loss of tissues and deviation of mandible to affected site, which was observed to be around 10 mm. (fig 2)

Intraoral examination show complete absence of mandibular left segment from right central incisor up to left condyle. (fig 3) The defect crossed midline hence classified as cantor and Curtis class 3. Remaining dentition shows generalized attrition and abrasion. Occlusion was disturbed due to deviation and wasting disease of teeth. Associated problem include difficulty with speech, swallowing, mastication, Disfigurement of face and drooling of saliva. A treatment plan was divided into temporary interim guide flange prosthesis to correct deviation followed by definitive cast partial denture prosthesis to restore a masticatory function.

For the interim guide flange prosthesis primary impression was made in irreversible hydrocolloid material, followed by border moulding and final impression with medium body impression material.(fig 4) Jaw relation was recorded and cast are mounted. A 19 gauge hard, round, stainless steel orthodontic wire (KC Smith and Co, Monmouth, UK) was manipulated to fabricate a substructure for the modified Guide Flange Prosthesis. The vestibular (buccal and lingual) flanges and the mandibular guide-flange were waxed-up with modeling wax (Modeling wax; Deepti Dental Products, Ratnagiri, India) around the wire substructure by keeping a maxillary cast in occlusion and try in was done.(fig 5) Subsequently it was acrylized into heat-polymerized acrylic resin (DPI Heat cure; Dental products of India, Mumbai, India) and delivered to patient. (fig 6) After wearing of prosthesis for around 6 months ,correction of deviation was observed.

Definitive restorative phase consisted of two parts ,Rehabilitation of remaining dentition with fixed dental prosthesis and restoration of missing oral structure with cast partial denture.Diagnostic impression were made to get a diagnostic cast. Maxillary arch showed kennedy's class II situation whereas mandibular arch showed cantor Curtis class 3 situation and remaining dentition showed severe attrition and abrasion of posterior teeth. After studying a diagnostic cast ,wax mock up ,surveying and designing of cast partial denture were carried out. Tooth preparation of maxillary and mandibular posterior teeth were carried out to receive PFM crowns.(fig 7a,b) Impressions were made in addition silicon two step putty light body technique.(fig 8 a,b) Casts were poured (type 3 gypsum material) and mounted on articulator with help of inter occlusal record.(fig 9) On these, definitive PFM crowns were fabricated with rest seats at appropriate positions for cast partial denture.(fig 10) rest seats for embrasure clasp in mandibular cast partial denture were made longer till central fossa and broader to stabilize and balance a unequal forces generated due to loss of mandible and associated muscles. surveying which was done at wax up stage was again verified at the bisque trial stage and necessary correction of contours of crowns were made for cast partial denture design.Cementation of glazed crowns were done to restore occlusion of remaining dentition.(fig 11) After cementation of fixed component medium body impression were made of both arches for fabrication of framework of cast partial denture(fig 12). Fitting of Framework checked intraorally. (fig 13) Secondary impression were made in edentulous portion of mandibular arch with border moulding and light body wash impression on mandibular cast partial denture framework.(fig 14 a,b) Altered cast technique was used for precise recording of distal extension portion of arch.(fig 15) On this corrected cast record base and wax

rimms were constructed to record jaw relation. Neutral zone was recorded to get a potential space, where forces from remaining cheek muscles and tongue are neutralized for arrangement of teeth, which will increase stability of denture.(fig 16) Teeth arrangement was done with zero degree teeth set (fig 17)and to maintain proper vertical relation double row of teeth were used in maxillary cast partial denture.(fig 18) Subsequently it was acrylized into heat-polymerized acrylic resin (DPI Heat cure; Dental products of India, Mumbai, India) and delivered to patient.(fig 19) patient was asked to come for regular checkup at interval of 3 months ,6 months,1 year,2 year.

Discussion

Mandible is a significant structure in lower third of face constituting to esthetics and functions like speech, swallowing and mastication. Surgical resection of mandible owing to benign, malignant neoplasm is common treatment modality. The resection can be total or segmental depending on the type of lesion.^[1,2,6] When a segment of the mandible is removed, immediate reconstruction is usually recommended to improve both facial symmetry and masticatory function but reconstructive surgery is not possible in many patients because of their medical condition, Amount, type and location of defect and cost factor. Loss of continuity of the mandible destroys the balance and symmetry of mandibular function, leading to altered mandibular movements and deviation of the residual fragment towards the surgical site and rotation inferiorly due to muscle pull and scar contracture affecting mastication and esthetics.^[1-3]

Guide flange prosthesis is recommended to decrease deviation of the mandible, improve masticatory function and esthetics. This therapy is most successful in patients for whom the resection involves only bony structures, with minimal sacrifice of tongue, floor of the mouth, and

adjacent soft tissues.^[1-5] The exercise as given by Beumer et al.^[2] was suggested to the patient. In this procedure, following maximum opening, the patient manipulates the mandible by grasping the chin and moving the mandible away from the surgical side. These movements tend to loosen scar contracture, reduce trismus, and improve maxilla-mandibular relationships

In this clinical case patient had underwent mandibular resection due to squamous cell carcinoma resulting in Cantor Curtis class 3 defect with mandibular deviation. The guide flange prosthesis was used for a period of 6 months until the patient experienced considerable decrease in deviation. The success in rehabilitating a patient with hemimandibulectomy depends upon the nature and extent of defect, treatment plan, type of prosthesis, and patient co-operation. The earlier the mandibular guidance therapy is initiated in the course of treatment, the more successful is the patient's definitive occlusal relationship^[1,2,5]

Robinson et al. (1964) stated that fabrication of a provisional guide plane facilitates the fabrication of a definitive restoration.^[4]

Definitive phase in this case was started with rehabilitation of remaining teeth which showed presence of generalized attrition and abrasion due to history of tobacco chewing habit and restoration of missing oral structures.

An implant supported fixed prosthesis or a removable cast partial denture are two main treatment options available to restore partially edentulous arches in patients. An implant supported prosthesis was not considered in this patient since no bone graft was used after resection of mandible and patient was not ready for additional bone grafting surgery because of financial reason.

After studying a diagnostic cast, designing of a cast partial denture for replacement of missing teeth and soft tissue structure in both arches was carried out, as primary

concern of patient was mastication. Patient had a history of tobacco chewing before mandibulectomy surgery which resulted into attrition and abrasion of teeth in oral cavity. For proper occlusal rehabilitation, all remaining teeth were prepared to receive metal ceramic crowns with incorporation of necessary modifications in terms of height of contour and rest seat areas. Mandibular cast partial denture is fabricated using altered cast technique to get intimate tissue contact with prosthesis in resected edentulous area.^[8] Neutral zone technique was used to find and utilize a potential space for arrangement of teeth where forces from remaining cheek musculature are neutralized by tongue muscle. This will help to improve stability of prosthesis.^[9]

a maxillary cast partial denture designed with two rows of teeth. This twin occlusion arrangement helped in better vertical relation and improves mastication.^[10] The palatal row of teeth provided favorable occlusal relationship and the buccal row of teeth supported the cheeks. A functional occlusal record was obtained in wax placed lingual to the maxillary posterior teeth and used as an index to arrange the palatal row of teeth.^[10]

Mastication was confined to the nonresected side only and the teeth on the resected side provided bilateral occlusion and thus stabilization of the prosthesis. Recalls were carried out over a period of 2 years, and the patient reported an increase in masticatory efficiency and seemed happy with the treatment.

Conclusion

Rehabilitation is an essential phase of cancer care and should be considered from the time of diagnosis in a complete and comprehensive treatment plan. The primary objective is restoration of function and appearance. Guide flange prosthesis is the most common treatment modality for correction of deviation. Use of cast partial dentures

with Altered cast technique, Neutral zone , Twin occlusion rehabilitates the patient functionally.

References

1. Taylor TD, 'Diagnostic considerations for prosthodontic rehabilitation of the mandibulectomy patient. Clinical maxillofacial prosthetics'. Chicago; Quintessence Publishing, 2000, pp.155-170.
2. RJ Fonsica ,WH Davis, 'Reconstruction Preprosthetic oral and maxillofacial surgery, 2nd Ed. WB Saunders Company, pp1063-1067.
3. PG. Patil, SP Patil, 'Guide flange prosthesis for early management of reconstructed hemimandibulectomy: a case report'. J Adv Prosthodont , vol 3 ,2011, pp172-176
4. P.Shetty, M.Baliga, S.Rodrigues ,S.Dixit, 'Prosthetic management following mandibular resection: A clinical report.' J Nepal Dent Assoc., vol 10, no.1,2009, pp 57-60.
5. AS Marathe, PS Kshirsagar, 'A systematic approach in rehabilitation of hemimandibulectomy: A case report.' J Indian Prosthodont Soc, vol 16, 2016, pp 208-212.
6. D Lingeshwar, R Appadurai, U swedheni, C Padmaja, 'Prosthodontic management of hemimandibulectomy patients to restore form and function - A case series, World J Clin Cases, vol 5, no.10, pp384-38
7. A Gopi , NK Singla , DK Saini , VS Legha , ' Guide the Mandible Back Home: Guide Flange Prosthesis.' J Orofac Res, vol 3, no.4, 2013, pp 290-293
8. P Hazari ,A Gaikwad , 'A definitive mandibular guide flange prosthesis following hemimandibulectomy: a clinical report.' IJO CR, vol 2, no.1, Jan - Mar 2014, pp 38-44
9. G.Manchikalapudi, V Hegde, 'Neutral zone for fabrication of complete denture in

hemimandibulectomy patient: A case report.' J pierre fauchard academy ,vol 25, no.1, 2011, pp 73-78

10. S.Agarwal, G Praveen, S Sharma, 'Twin Occlusion: A Solution to Rehabilitate Hemimandibulectomy Patient—A Case Report.' J Indian Prosthodont Soc, vol 11, no.4, (Oct-Dec 2011) ,pp 254-257

Legend Figures

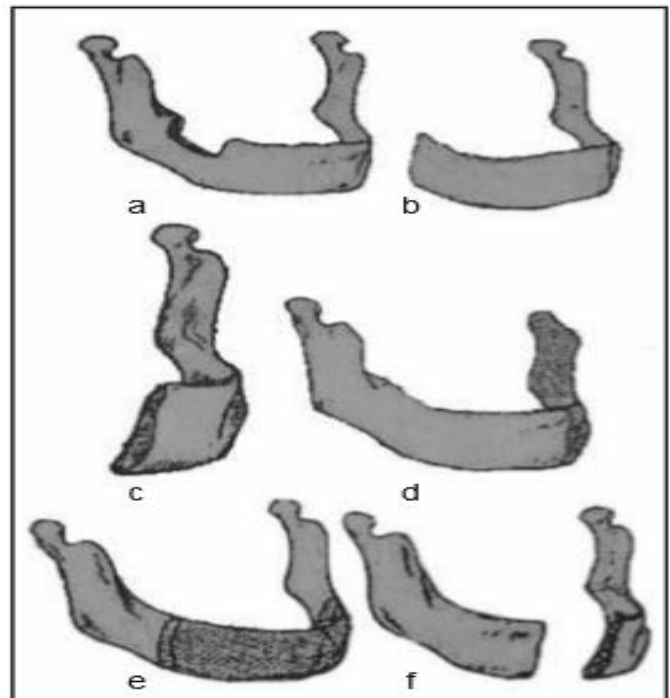


Fig 1: Cantor and Curtis classification



Fig 2: Extraoral photograph showing deviation

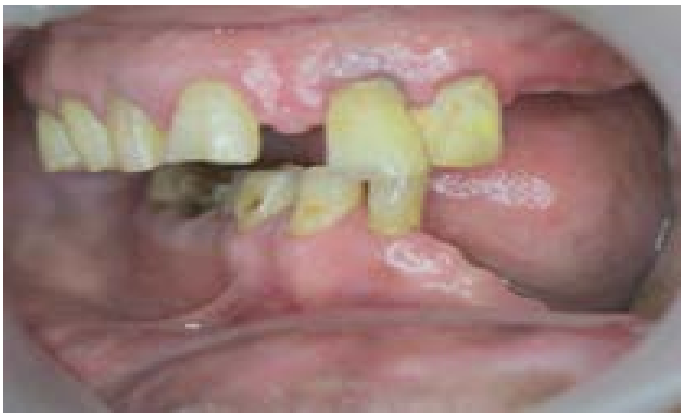

Fig 3: Intraoral photograph showing loss of mandibular left segment

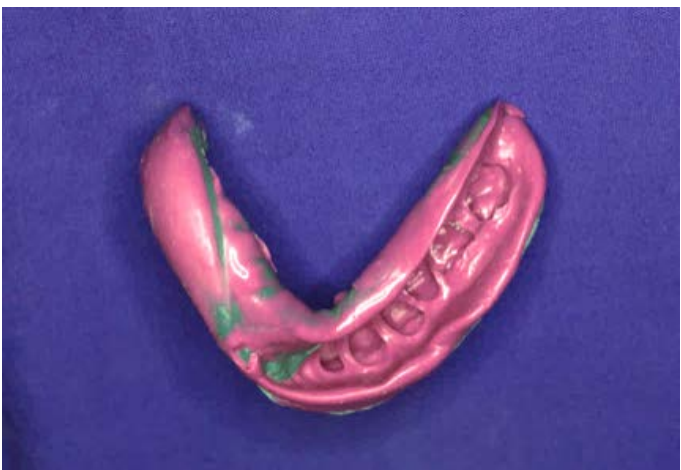

Fig 4: Final impression

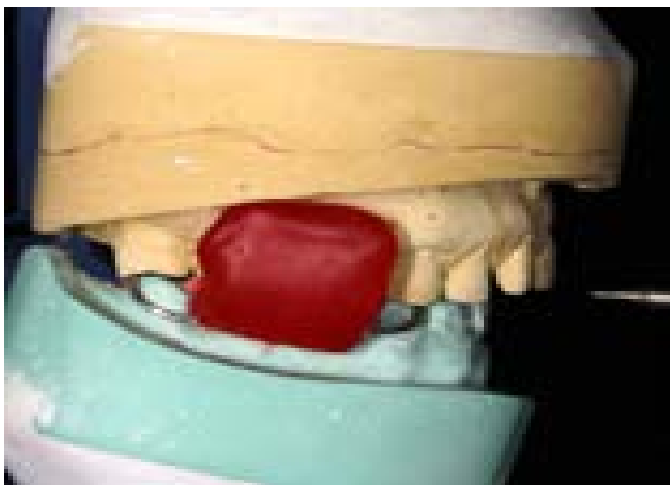


Fig 5: Try in of guide flange prosthesis

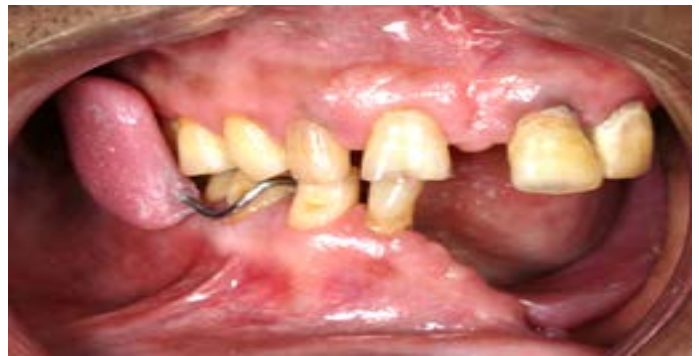

Fig 6: Guide flange prosthesis

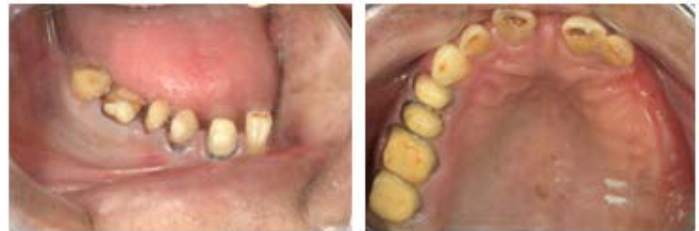

Fig 7 a, b: tooth preparation

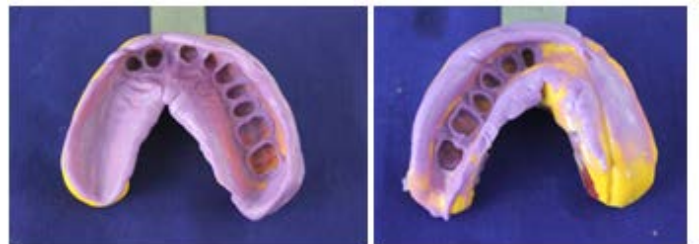


Fig 8 a,b: Final impression for fixed dental prosthesis

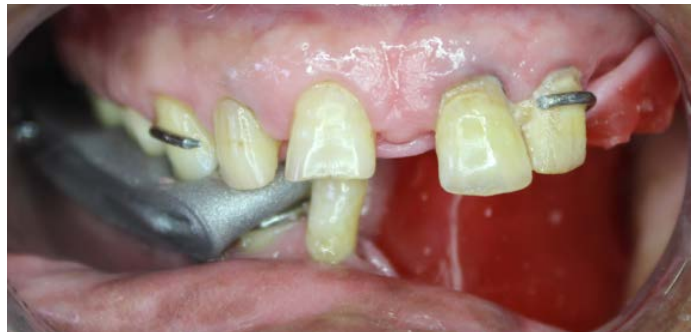

Fig 9: Interocclusal record

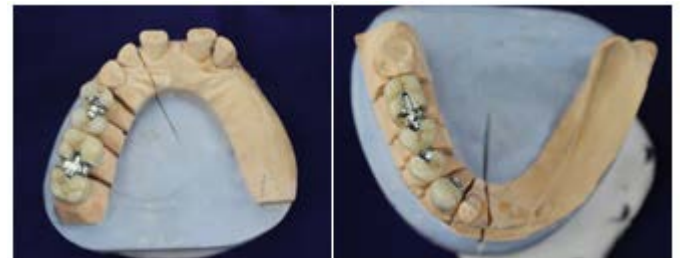

Figure 10: Final PFM crowns showing required rest seats for cast partial denture

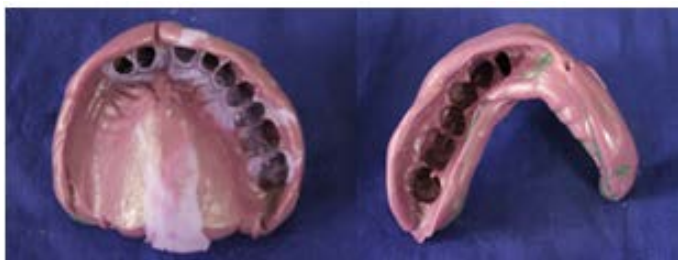

Fig 11: Final cementation of crowns

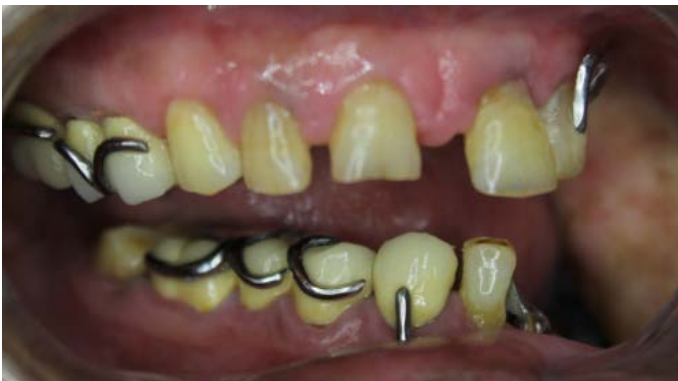

Fig 12: Final impression for maxillary and mandibular cast partial denture

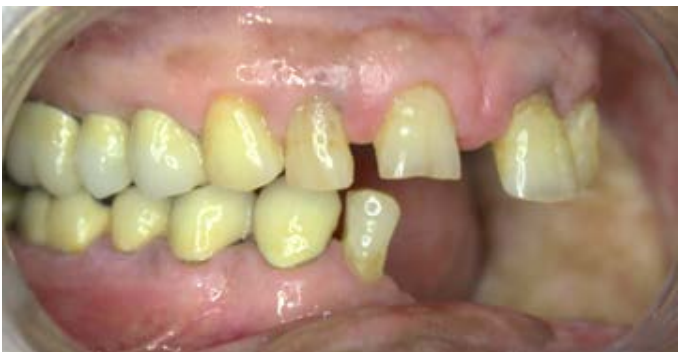

Fig 13 : Checking fit of cast partial denture framework

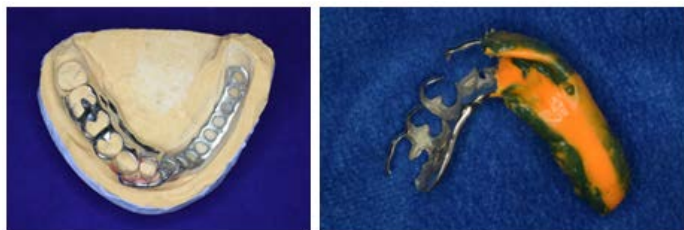

Fig 14 a,b: Secondary impression on mandibular cast partial denture framework to record edentulous distal extension area

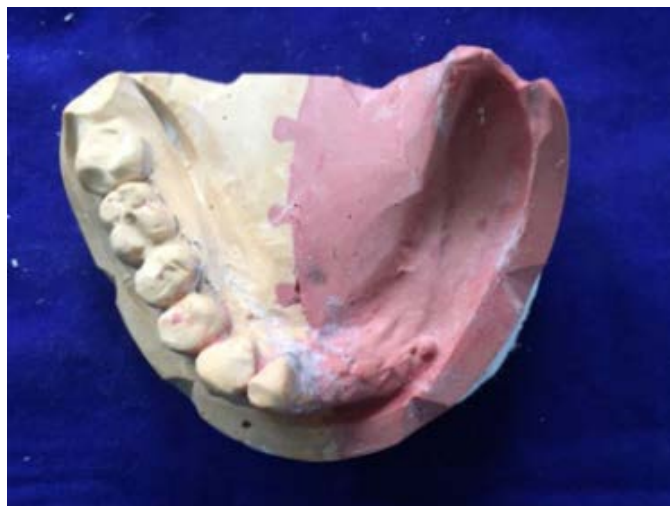

Fig 15 : Altered cast

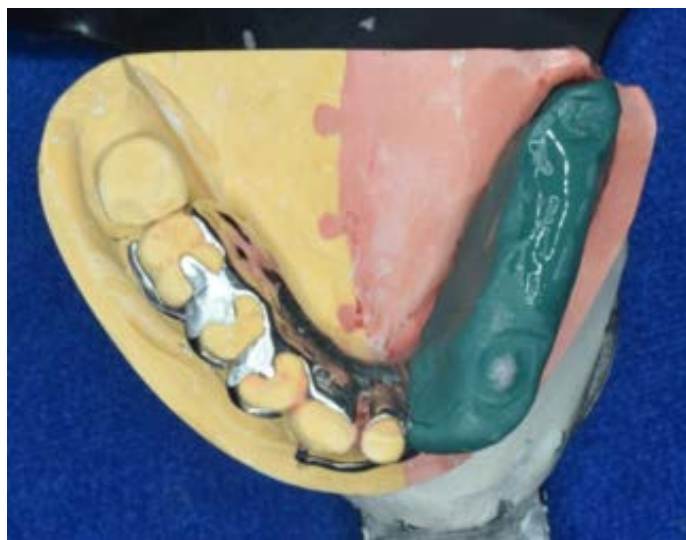


Fig 16: Neutral zone recorded

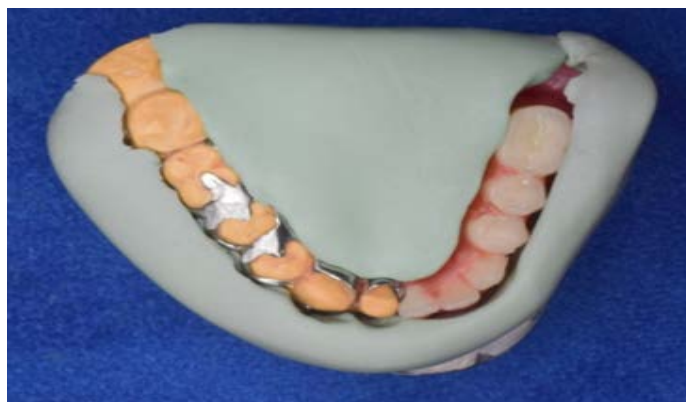

Fig 17: Teeth arrangement in neutral zone

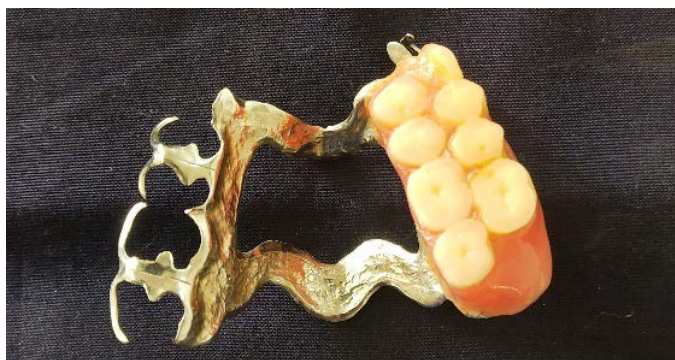

Fig 18: Twin occlusion in maxillary cast partial denture

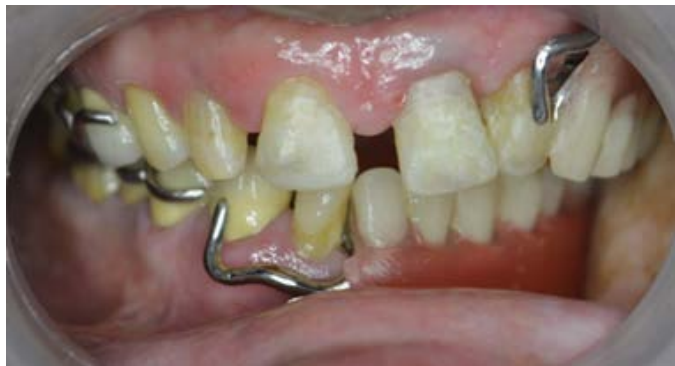

Fig 19: Post operative intraoral photograph