

Occlusal Rehabilitation of A Female Patient with Pseudo Class III Malocclusion by Non- Extraction Protocol Using Conventional Mechanics for Esthetic and Profile Refinement - A Case Report

¹Dr. Bhushan Jawale, Professor, Dept of Orthodontics and Dentofacial Orthopedics, Sinhgad Dental College and Hospital, Sinhgad, Pune, Maharashtra, India

²Dr. Lishoy Rodrigues, PG Student, Dept of Orthodontics and Dentofacial Orthopedics, Sinhgad Dental College and Hospital, Sinhgad, Pune, Maharashtra, India

³Dr.Tushar Patil, Professor and HOD , Dept of Orthodontics and Dentofacial Orthopedics, Shri Yashwanthrao Chavan Dental College and Hospital, Ahmednagar, Maharashtra, India

⁴Dr.Swapnil Mhatre, Professor and HOD, Dept of Pedodontics, RR Dental College and Hospital, Udaipur, Rajasthan, India

⁵Dr. Ajay Panicker, Private Practice, Thane, Mumbai, Maharashtra, India

⁶Dr.Veerendra Kerudi, Professor and HOD, Dept of Orthodontics and Dentofacial Orthopedics, ACPM Dental College and Hospital, Dhule

Corresponding Author: Dr. Lishoy Rodrigues, PG Student, Dept of Orthodontics and Dentofacial Orthopedics, Sinhgad Dental College and Hospital, Pune

Citation of this Article: Jawale Bhushan, Rodrigues Lishoy, Patil Tushar, Mhatre Swapnil, Panicker Ajay, Kerudi Veerendra, “Occlusal Rehabilitation of A Female Patient with Pseudo Class III Malocclusion by Non- Extraction Protocol Using Conventional Mechanics for Esthetic and Profile Refinement - A Case Report”, IJDSIR- June - 2020, Vol. – 3, Issue -3, P. No. 123 -130.

Copyright: © 2020, Dr Lishoy Rodrigues, et al. This is an open access journal and article distributed under the terms of the creative commons attribution noncommercial License. Which allows others to remix, tweak, and build upon the work non commercially, as long as appropriate credit is given and the new creations are licensed under the identical terms.

Type of Publication: Case Report

Conflicts of Interest: Nil

Abstract

The number of adults seeking orthodontic treatment has increased significantly.^{1, 2} Treatment alternatives of correction of a skeletal class III in adults are either Orthodontic camouflage or a Combined orthodontic-orthognathic surgical therapy. It eventually depends mainly upon the severity of the malocclusion ^{3, 4} and the amount of needed tooth movements.^{3, 5} If the skeletal discrepancy ⁶ cannot be corrected by camouflage, any

dental compensation may produce a reasonably good occlusion⁷but at the expense of compromised esthetics.For adult patients having severe orthodontic problems, surgery to realign the jaws or reposition dentoalveolar segments is the only possible treatment option left. One indication for surgery is a malocclusion so severe that it cannot be corrected by orthodontics alone.⁸This case report evaluates the management of a Pseudo Class III division malocclusion in a female patient without extraction .

Clinical and cephalometric evaluation revealed skeletal Class I with a pseudo dental Class III malocclusion with a slightly concave profile, average mandibular plane angle, competent lips, reverse overjet and overbite. Following fixed orthodontic treatment marked improvement in patient's smile, facial profile and occlusion were achieved and there was a remarkable increase in the patient's confidence and quality of life. The profile changes and treatment results were demonstrated with proper case selection and good patient cooperation with Fixed appliance therapy.

Keywords: Pseudo Class III malocclusion, Occlusal Rehabilitation, Fixed Appliance Therapy, Non extraction protocol, Esthetic and Profile Refinement

Introduction

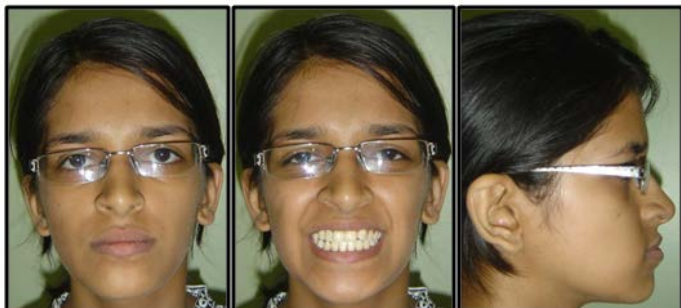Fixed Appliance treatment can significantly alter and improve facial appearance in addition to correcting irregularity of the teeth. Class II div 1 malocclusion is more prevalent than any type of malocclusion after Class I malocclusion. Over the last few decades, there are increased number of adults who have become aware of orthodontic treatment and are demanding high quality treatment, in the shortest possible time with increased efficiency and reduced costs. Class III malocclusion patients frequently show a combinations of skeletal and dentoalveolar components. Many cephalometric peculiarities have been reported in class III patients, such as an acute cranial base angle, a retrusive maxilla, proclined maxillary and retroclined mandibular incisors, an increased lower anterior face height and obtuse gonial angle^{9,10}. Prevalence of class 3 malocclusion in caucasians ranges from 0.8% to 4.0% and increases up to 12-13% in Chinese and Japanese population, while in American population class 3 malocclusion ranges from 3-4% of the population^{9, 10,11}. The surgical correction of prognathism is a procedure that dates back more than 100

years. In¹² 1849 Hüllihen described a technique for the correction of such a deformity. Since that time refinements of technique and various methods have¹³ been described. At the turn of the century Blair published several articles on this particular subject. Interest in the subject and in the various techniques used in its correction became widespread. After^{14 15} Blair, came reports from Kazanjian, Dingman,^{16 17} Reiter, Caldwell and Letterman, Moose, and many others. This case presents the correction of a Pseudo Class III malocclusion in an adult female patient with reverse overjet and overbite and moderate crowding merely simply by executing a non extraction protocol. The Non Extraction protocol shown in this case is indicative of how a Class III case can be converted into a non extraction case by routine Fixed Orthodontic treatment

Case Report

Extra-Oral Examination: A 20 year old female patient presented with the chief complaint of forwardly placed lower front teeth and irregular and uncomfortable bite. On Extraoral examination, the patient had a slightly concave facial profile, grossly symmetrical face on both sides with a slightly protruded chin, competent lips, moderately deep mentolabial sulcus and an average Nasolabial Angle, a Leptoprosopic facial form, Dolicocephalic head form, Average width of nose and mouth, minimal buccal corridor space, a consonant smile arc and slightly anterior divergence of face. The patient had no relevant prenatal, natal, postnatal history, history of habits or a family history. On Smiling, there was average show of maxillary anterior teeth. The patient had a toothy smile. On smiling the patient showed the presence of a reverse overjet and overbite and an unaesthetic facial profile.

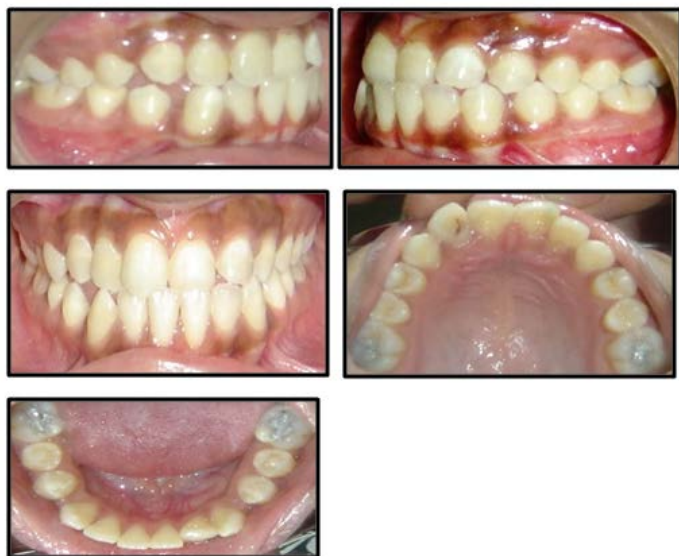Pre Treatment Extraoral Photographs



Intra-Oral Examination

Intraoral examination on frontal view shows presence of a reverse overjet and overbite with the lower dental midline shifted slightly to the left of the patient. On lateral view the patient shows the presence of Class III incisor relationship, a Class III Canine relationship on right side and a Class I canine relationship on the left side. Patient had a Class I molar relationship Bilaterally. Patient had a reverse overjet of 1 mm and a reverse overbite of 2 mm. There was spacing in the lower arch between canines and premolars bilaterally. A complete anterior crossbite was seen. The upper and lower arch showed the presence of a U shaped arch form.

Pre Treatment Intraoral Photographs



Pre Treatment Cephalometric Readings

Parameters	Pre- Treatment
SNA	82°
SNB	83°
ANB	-1°
WITS	0mm
MAX. LENGTH	75mm
MAN. LENGTH	98mm
IMPA	98°
NASOLABIAL ANGLE	95°
U1 TO NA DEGREES	27°
U1 TO NA mm	3mm
L1 TO NB DEGREES	28°
L1 TO NB mm	5mm
U1/L1 ANGLE	129°
FMA	25°
Y AXIS	65°

- 1) Steiners analysis shows an average maxilla and a prognathic mandible, Class I Skeletal pattern, an Average growth pattern, slightly proclined maxillary and mandibular anteriors, forwardly placed maxillary and mandibular anteriors and protrusive upper and lower lips
- 2) Tweeds analysis shows a Horizontal growth pattern and proclined mandibular incisors
- 3) Wits appraisal shows BO ahead of AO by 1 mm indicating Skeletal Class I pattern
- 4) Ricketts analysis shows an average mandible, average positioned condyles and proclined mandibular anteriors
- 5) McNamara analysis shows an average maxilla, prognathic mandible, a horizontal growth pattern, average lower anterior facial height and proclined mandibular incisors
- 6) Rakosi Jaraback analysis shows an average growth pattern and slightly proclined maxillary and mandibular incisors

7) Holdaway soft tissue analysis shows increased maxillary and mandibular sulcus depth and increased strain of lips along with a protruded chin position

8) Downs analysis shows a Class I Skeletal pattern, a horizontal to average growth pattern and average maxillary and proclined mandibular anterior teeth

Diagnosis

This 20 year old female patient was diagnosed with a Pseudo Class III Occlusion with an average maxilla and a prognathic mandible and an average growth pattern, reverse overjet and overbite, proclined lower incisors, prominent chin, moderately deep mentolabial sulcus and Competant lips

List of Problems

1. Prognathic mandible
2. Pseudo Class III occlusion
3. Reverse Overjet and overbite
4. Concave profile
5. Prominent chin
6. Class III Canine relationship on right side
7. Class III Incisor relationship
8. Proclined lower incisors
9. Non coincident midlines
10. Spacing in lower arch

Treatment Objectives

1. To correct mandibular prognathism
2. To correct the reverse overjet and overbite
3. To correct the anterior divergence of face
4. To achieve a Class I Incisor and Canine relationship
5. To correct spacing in the mandibular arch
6. To correct proclined lower anterior teeth
7. To correct the deep mentolabial sulcus
8. To achieve a pleasing smile and a pleasing profile

Treatment Plan

- Fixed appliance Therapy with MBT 0.022 inch bracket slot

- Initial leveling and alignment with 0.012", 0.014", 0.016", 0.018", 0.020" Niti archwires following sequence A of MBT
- Retraction and closure of spaces by use of 0.019" x 0.025" rectangular NiTi followed by 0.019" x 0.025" rectangular stainless steel wires
- Final finishing and detailing with 0.014" round stainless steel wires
- Retention by means of Beggs Wrap-around retainers along with lingual bonded retainers in the upper and lower arch.

Treatment Progress

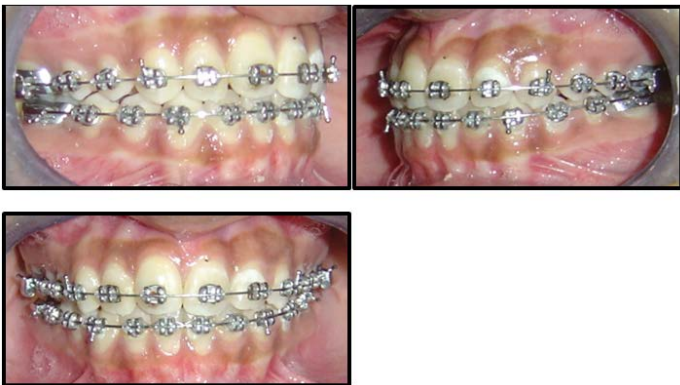
Complete bonding & banding in both maxillary and mandibular arch done, using MBT-0.022X0.028" slot. Initially a 0.012" NiTi wire was used which was followed by 0.014, 0.016", 0.018", 0.020" Niti archwires following sequence A of MBT. After 6 months of alignment and leveling NiTi round wires were discontinued. Retraction and closure of spaces was then started by use of 0.019" x 0.025" rectangular NiTi followed by 0.019" x 0.025" rectangular stainless steel wires. Anchorage was conserved by light retraction forces constantly monitoring the already well settled molar relation. This is the most important step in a Non extraction case wherein anchorage conservation is of utmost importance. Class III Elastics were given to correct the reverse overjet. During this period, Bite Turbos were given on mandibular 1st molars bilaterally for opening of bite until the anterior crossbite was corrected. Finally light settling elastics were given with rectangular steel wires in lower arch and 0.012" light NiTi wire in upper arch for settling, finishing, detailing and proper intercuspation. The reverse Overjet and overbite was corrected with an ideal occlusion at the end of the fixed appliance therapy. Also the profile of the patient improved significantly from being slightly concave

to now more Orthognathic with a pleasant and consonant smile arc on smiling.

Mid Treatment Extraoral Of Fixed Appliance Therapy



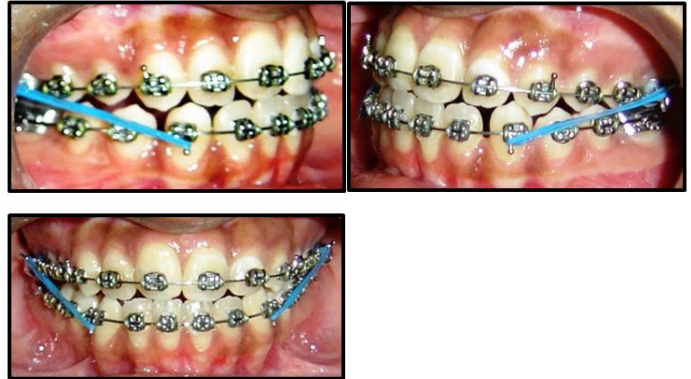Mid Treatment Intraoral Of Fixed Appliance Therapy



Post Treatment Cephalometric Readings

Parameters	Post-Treatment
SNA	82°
SNB	80°
ANB	2°
WITS	0mm
MAX. LENGTH	76mm
MAN. LENGTH	97mm
IMPA	92°
NASOLABIAL ANGLE	96°
U1 TO NA DEGREES	26°
U1 TO NA mm	2mm
L1 TO NB DEGREES	22°
L1 TO NB mm	2mm
U1/L1 ANGLE	134°
FMA	25°
Y AXIS	66°

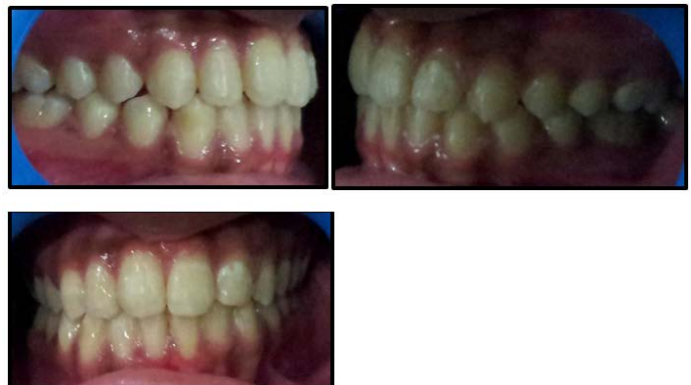Class III Elastics



Post Treatment Extraoral Photographs



Post Treatment Intraoral Photographs



Discussion

Treatment of a Pseudo Class III without extractions of premolars is challenging. A well chosen individualized treatment plan, undertaken with sound biomechanical principles and appropriate control of orthodontic mechanics to execute the plan is the surest way to achieve predictable results with minimal side effects. Class III malocclusion might have any number of a combination of the skeletal and dental component. Hence, identifying and understanding the etiology and expression of Class III malocclusion and identifying differential diagnosis is

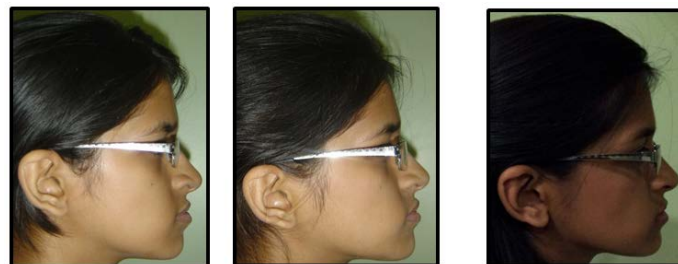helpful for its correction. The patient's chief complaint was forwardly placed lower front teeth and irregular and uncomfortable bite. The selection of orthodontic fixed appliances is dependent upon several factors which can be categorized into patient factors, such as age and compliance, and clinical factors, such as preference/familiarity and laboratory facilities. The execution of only Fixed appliance therapy appropriately resulted in an improvement in the patient's profile in this case. The most important point to be highlighted here is the use of Class III Elastics. Class III Elastics played a very pivotal role in this case for drastically bringing improvement not only in the correction of the reverse overjet, but also very efficiently improving the patients profile changing it from being nearly concave to more orthognathic at the end of the treatment. There was improvement in occlusion, smile arc, profile, lower incisor inclination and position of chin. Successful results were obtained after the fixed MBT appliance therapy within a stipulated period of time. The overall treatment time was 13 months. After this active treatment phase, the profile of this 20 year old female patient improved significantly as seen in the post treatment Extra oral photographs. Removable Beggs retainers were then delivered to the patient along with fixed lingual bonded retainers in upper and lower arch.

Comparison of Pre and Post Treatment Cephalometric Readings

Parameters	Pre- Treatment	Post-Treatment
SNA	82°	82°
SNB	83°	80°
ANB	-1°	2°
WITS	0mm	0mm
MAX. LENGTH	75mm	76mm

MAN. LENGTH	98mm	97mm
IMPA	98°	92°
NASOLABIAL ANGLE	95°	96°
U1 TO NA DEGREES	27°	26°
U1 TO NA mm	3mm	2mm
L1 TO NB DEGREES	28°	22°
L1 TO NB mm	5mm	2mm
U1/L1 ANGLE	129°	134°
FMA	25°	25°
Y AXIS	65°	66°

Comparison Of Pre, Mid And Post Treatment Profiles



Conclusion

This case report shows how Pseudo Class III case can be managed with a Non Extraction Protocol by means of appropriate use of simplified fixed orthodontic treatment and efficient use of Class III Elastics. The planned goals set in the pretreatment plan were successfully attained. Good intercuspation of the teeth was maintained with class I molar relationship. Treatment of the Prognathic appearing lower jaw included the retraction and retroclination of mandibular incisors with a resultant decrease in soft tissue procumbency and facial concavity. The reverse overjet and overbite were eliminated and the profile changed from concave to orthognathic. The overjet become near ideal and normal overbite was achieved. The maxillary and mandibular teeth were found to be

esthetically satisfactory in the line of occlusion. Patient had improved smile and Profile without the need for extractions. The correction of the malocclusion was achieved, with a significant improvement in the patient aesthetics and self-esteem. The patient was very satisfied with the result of the treatment.

References

1. Boyd RL, Leggott PJ, Quinn RS, Eakle WS, Chambers D. periodontal implications of orthodontic treatment in adults with reduced or normal periodontal tissues versus those of adolescents. *Am J Orthod Dentofacial Orthop* 1989;96:191-198.
2. Gottlieb EL, Nelson AH, Vogels DS. 1990 JCO study of orthodontic diagnosis and treatment procedures. Part 1: Results and trends. *J Clin Orthod* 1991;25:145-156
3. Bailey LJ, White R Jr. Assessment of patient for orthognathic surgery. *Semin Orthod* 1999;5:209-222.
4. Tulloch Jf, Lenz BE, Phillips C. Surgical Versus orthodontic correction for class II patients: age and severity in treatment planning and treatment outcome. *Semin Orthod* 1977;72:1-22.
5. Graber TM, Vanarsdall RL, Vig KWL. *Orthodontics. Current principles and techniques ed 3.* St Louis: Mosby, 2000.
6. Proffit WR, White RP Jr. Who needs surgical-orthodontic treatment ? *Int J Adult Orthodon Orthognath Surg* 1990;5:81-89
7. Turvey Ta Orthognathic surgery: A significant contribution to facial and dental esthetics. *J Am Dent Assoc* 1998;117:49e-55e.
8. Trivedi B, Mahadevia S, Shah R, Thakker D. Combined Orthodontic and Surgical Approach in an Adult Patient with Skeletal Class III Malocclusion. *Journal of Advanced Oral Research.* 2014 Sep;5(3):24-7.
9. Kharbanda OP, Sidhu SS, Sundaram KR, Shukla DK. Prevalance of malocclusion and its traits in Delhi children. *J Indian Orthod Soc* 1995;26:98-103.
10. Ishii N, Deguchi T, Hunt NP. Craniofacial differences between Japanese and British Caucasian females with a skeletal Class III malocclusion. *Eur J Orthod* 2002;24:493-9.
11. Lew KK, Foong WC. Horizontal skeletal typing in an ethnic chinese population with true class 3 malocclusion. *Br Orthod* 1993;20 :19-23
12. Hullihen, S. P.: Case of Elongation of the Under Jaw and Distortion of the Face and Neck, Caused by a Burn, Successfully Treated, *Am. J. D. SC.* 9: 157, 1849.
13. Blair, V. P.: Operations on the Jaw-bone and Face, *Surg. Gynec. & Obst.* 4: 67, 1907.
14. Kazanjian, V. H.: Treatment of Mandibular Prognathism With Special Reference to Edentulous Patients, *Oral Surg., Oral Med. & Oral Path.* 4: 680, 1951.
15. Dingman, R. O.: Surgical Correction of Mandibular Prognathism, an Improved Method, *AM. J. ORTHODONTICS & ORAL SURG.* 30: 683, 1944.
16. Reiter, Edward : Surgical Correction of Mandibular Prognathism, *Alpha Omegan* 45:104, 1951.
17. Caldwell, Jack B., and Letterman, G. S.: Vertical Osteotomy in the Mandibular Rami for Correction of Prognathism, *J. Oral Surg.* 12: 185, 1954.
18. J. D. Smith, P. M. Thomas, and W. R. Proffit, "A comparison of current prediction imaging programs," *American Journal of Orthodontics and Dentofacial Orthopedics*, vol. 125, no. 5, pp. 527–536, 2004
19. Rivera SM, Hatch JP, Dolce C, Bays RA, Van Sickels JE, Rugh JD. Patients' own reasons and patient-perceived recommendations for orthognathic surgery. *Am J Orthod Dentofacial Orthop.* 2000;118:134–141.

20. Proffit WR, Philips C, Dann C, Turvey TA. Stability after surgical orthodontic correction of skeletal Class III malocclusion. I. Mandibular setback. *Int J Adult Orthodon Orthognath Surg.* 1991;6:7–18.
21. Proffit WR, Philips C, Turvey TA. Stability after surgical orthodontic correction of skeletal Class III malocclusion. III. Combined maxillary and mandibular procedures. *Int J Adult Orthodon Orthognath Surg.* 1991;4:211–225.
22. Bailey LJ, Cevdanes LH, Proffit WR. Stability and predictability of orthognathic surgery. *Am J Orthod Dentofacial Orthop.* 2004;126(3):273–277
23. Kiran J, Isaac A, Shanthraj R, Madannagowda S. Surgical-orthodontic treatment of Class I malocclusion with maxillary vertical excess--a case report. *International Journal of Orthodontics (Milwaukee, Wis.).* 2012 Jan 1;23(2):57-62
24. Bjork A, Skieller V. Normal and abnormal growth of the mandible. A synthesis of longitudinal cephalometric implant studies over a period of 25 years. *Eur J Orthod.* 1983;5:41–43
25. Eggenesperger N, Raditsch T, Taghizadeh F, Iizuka T. Mandibular setback by sagittal ramus osteotomy: a 12-year follow-up. *Acta Odontol Scan.* 2005;63:183–188.
26. Cho HJ. Long-term stability of surgical mandibular setback. *The Angle Orthodontist.* 2007 Sep;77(5):851-6.
27. Viswapurna PS, Al Hashmi A. ORTHODONTIC SURGICAL TREATMENT OF A SKELETAL CLASS III MALOCCLUSION.
28. F. Luther, D. O. Morris, and K. Karnezi, “Orthodontic treatment following orthognathic surgery: how long does it take and why? A retrospective study,” *Journal of Oral and Maxillofacial Surgery*, vol. 65, no. 10, pp. 1969–1976, 2007.