

Post placement and core build up in root canal treated teeth¹Dr Preeti Patni, ²Dr Babita Yeshwante, ³Dr Nazish Baig, ⁴Dr Vivek Jadhav, ⁵Dr Ruchi Kasat

CSMSS Dental College & Hospital, Kanchanwadi, Paithan Road, Aurangabad, Maharashtra-431011

Corresponding Author: Dr Preeti Patni, CSMSS Dental College & Hospital, Kanchanwadi, Paithan Road, Aurangabad, Maharashtra-431011**Citation of this Article:** Dr Preeti Patni, Dr Babita Yeshwante, Dr Nazish Baig, Dr Vivek Jadhav, Dr Ruchi Kasat, "Post placement and core build up in root canal treated teeth", IJDSIR- June - 2020, Vol. – 3, Issue -3, P. No. 98 - 109.**Copyright:** © 2020, Dr Preeti Patni, et al. This is an open access journal and article distributed under the terms of the creative commons attribution noncommercial License. Which allows others to remix, tweak, and build upon the work non commercially, as long as appropriate credit is given and the new creations are licensed under the identical terms.**Type of Publication:** Original Research Article**Conflicts of Interest:** Nil**Abstract**

The objective of this article is to (i) collate information on Post and Core available on the electronic platform, (ii) share overview from different aspect on sub-topics (iii) in concise, simple and understandable manner and thus (iv) save time of clinicians and researchers.

Overview of the article: The article covers sub topics like classification & its description, indications, important principle & procedure, luting cements, core build-up materials from various published articles and literature.

Conclusion: This article provides an overview of post and core to the readers. Clinical Significance- The teeth whose root canal treatment has been done successfully, but has less coronal structure left can be restored successfully with post and core treatment. Otherwise the other option left is extraction of teeth.

Keywords: post and core, indication, classification, principles, types, clinical procedure, luting cements, core material.

Introduction

The fracture resistance of the root canal treated teeth, does not depend on its vitality, rather it depends on the amount of the tooth structure left. Anterior teeth in which minimum access cavity preparation is needed, can be restored with composite resin and posterior teeth with amalgam or with composite resin. Whereas where large access cavity preparation is needed, which involves more cusps, full coverage restorations (crowns) are required. But, posterior and anterior teeth with large access cavity preparation, in which crown structure left is not sufficient for full coverage restoration(crown), but sufficient for core build up and restoration with crown, post is not required here, only core build-up is done and finish margins prepared and crown given. Whereas, posterior teeth with large access cavities following extensive carious lesions and very less coronal structure left, post and core build up followed by full coverage restoration on it, can be done. [1] [2] the studies indicate that the restorations that enhance structural integrity would be expected to increase

the prognosis of root canal treated teeth exposed to heavy masticatory loading forces [3]

A post and core is used when there is inadequate tooth structure remaining to support a traditional restoration or a full coverage artificial crown. The post is a small rod of biocompatible material that is inserted into the root canal of the tooth and protrudes from the root, for core build-up. The core is build on the post or the tooth structure left, to replace missing tooth structure, which is then prepared for making a full coverage crown. The dental core can also be directly built up from composite materials on the tooth structure left, without a post to hold it in place.

The ancient history of post and core is since Tokugawa era (1603 to 1867). At that time the Japanese used wooden dental restorations, which were designed in such a way that they function like the modern dowel crown. Pierre Fauchard (1678 – March 22, 1761) was a French physician, who is known as being the "father of modern dentistry" in 1728 described the use of "tenons," which were metal posts screwed into the roots of teeth to retain bridges. [4] He in his book "The Surgeon-Dentist" or "Treatise on the Teeth" published in 1728, described a technique in which a silver post was used to retain a natural tooth crown or an ivory crown to a root. [5]. In 1800, wood replaced metal as the post material. The wooden post fitted with artificial crown was known as "pivot crown". They became very popular amongst dentists. Their disadvantage was, as they were made of wood, they absorbed fluid and expand, which gave pressure on the root and frequently causes root fracture. [4] C. M. Richmond (1835–1902), an American dentist designed a Richmond crown in 1878, with a threaded tube incorporated into the root canal with a screw-retained crown. [6] Then it is modified as a single piece post retained crown with a porcelain facing. It is a customised castable post and crown system as both are single unit, in

which both post and crown are fixed and they are casted together. [7] It is still preferred when there is deep-bite cases involving minimum overjet with severely destructed tooth structure. [7] Its disadvantages are, its elastic modulus is more than dentine, therefore chances of fracture are more. It is a time consuming and costly procedure and if ceramic fracture occurs, it is difficult to retrieve. [6] During the 1930s, the custom cast post-and-core was developed to replace the one-piece post crowns. This procedure required casting a post-and-core as a separate component from the crown. This 2-step technique improved marginal adaptation and allowed for a variation in the path of insertion of the crown. [4] The cast post - core system requires multiple appointments accompanied by an intermediate laboratory phase to elaborate the retaining system, making the procedure more expensive. Now a day's prefabricated posts do not require this intermediate phase and therefore, allow the whole restoration to be performed in one visit, resulting in an easier, less expensive technique. [5]

Earlier, it was thought that dentin in root canal treated teeth is more brittle than the dentin in vital teeth, due to water loss and loss of collagen cross linking. [8] Haug in 1992 did the study on difference between mechanical properties of endodontically treated teeth and vital teeth. He concluded that dehydration due to root canal treatment does not hamper the mechanical properties of dentin. [9] The studies further concluded that loss of structural integrity due to access cavity preparation in root canal treatment, lead to a higher occurrence of fractures, when compared with vital teeth. Some studies even suggest that teeth have a protective feedback mechanism that is lost when the pulp is removed in root canal treatment, which also may contribute to tooth fracture. [8]

Indication of post and core

When the residual tooth structure is not sufficient to support the crown or only the core build up, the placement of the post with core build-up is suggested in root canal treated teeth. The purpose of the post is to retain the core, on which crown is given. [8]

Anterior teeth

Anterior teeth with extensive loss of crown structure usually need a post. In anterior teeth, small pulp chamber and single canal is usually there, so it is generally not adequate to retain a core, therefore post is necessary. In addition, anterior teeth are subjected to lateral and shearing type of forces during function. [10] [3]

Molar teeth

There are very less chances for molar teeth to require post. The pulp chamber and multiple canals of the molar teeth, provide sufficient retention. But, when there is extensive destruction of the crown structure, post and core treatment is required. [8] The posts should be placed in distal canal in mandibular molars which is the largest and straightest canal and the palatal canal in maxillary molars, because the other canals are thinner and more curved. Molars are subjected primarily to vertical forces. [10] Rarely, more than one post is required in a molar [8]

Premolars

Premolars require post more often than molars. They are usually bulkier than anterior teeth, but are often single rooted with relatively small pulp chamber, for this reason, they require more post and core treatment as compared to molars [8] Premolars have got transitional morphology. Therefore, before post placement, they are more subjected to clinical judgment. The remaining dentin will dictate whether the post is indicated or not. [10] They are subjected to lateral forces during mastication. [3]

Contraindications for post

When there is sufficient tooth structure left to retain the core, dentist should avoid using the post.[10] After the access cavity preparation in root canal treatment, if there is minimum loss of tooth structure, tooth structure may be restored with a bonded restoration in the access opening. A post is of little or no use in a structurally sound teeth and increases the likelihood of a non-restorable failure. [3] Unless the teeth is extensively destructed, molars do not require post, as their pulp chamber and canals provide adequate retention for core build up. [8]

Principles of post and core

The influence of gap between the post and the residual gutta purcha on the clinical outcome of root canal treated teeth was studied. Studies found that, the best outcome was seen, when there is minimum gap between gutta purcha and post. [1] Studies suggest that minimum 3 mm of gutta purcha should be left in the canal after post space preparation to prevent microleakage. To prevent the risk of recontamination, a barrier like Triage intraorifice barrier or Vitrebond is suggested over the gutta purcha. [1] Retention of the post is dependent on the length of the post. Studies suggest that, the post should be as long as possible without disturbing the apical 3mm gutta purcha. Short posts are harmful and have a higher failure rate in the root canal treated teeth. The retention of the post is independent of the diameter of the post. Studies suggest that, more the diameter of the post, more will be the chances of fracture of the root. [11]

Retrievability of the post is important. If the root canal treatment fails, it becomes necessary to retrieve the post. Metal and fiber posts are easy to retrieve. In contrast ceramic and zirconium posts are considered to be very difficult and sometimes impossible to retrieve. [3]

Ferrule is a sound tooth structure which is present above the free gingival margin of the teeth. In root canal treated

teeth which require post and core, if the ferrule tooth structure left is 1.5- 2.0mm in the occlusal direction, it is of maximum benefit. [12] If adequate ferrule is not left, crown lengthening or orthodontic eruption of a tooth can be done to provide the same. [8]

Resistance is the ability of the post, core and tooth to withstand lateral and rotational forces. It depends on the length of the post, ferrule, rigidity of the post, the presence of antirotation features and the remaining tooth structure. [8]

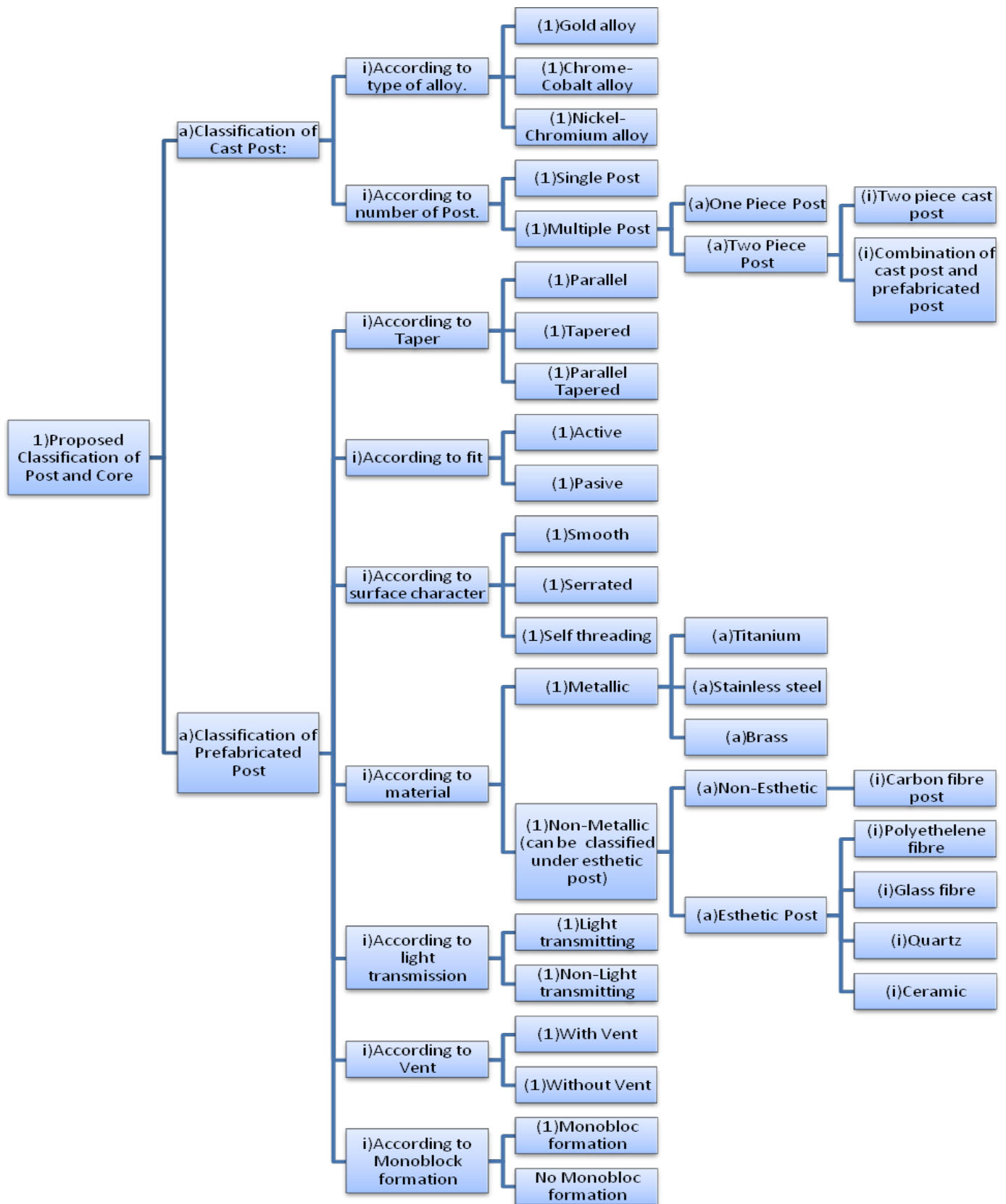
Preservation of the tooth structure should be done, whenever possible. Minimum dentin should be removed after root canal treatment for post placement. [13]

Classification of post and core according to material and method:

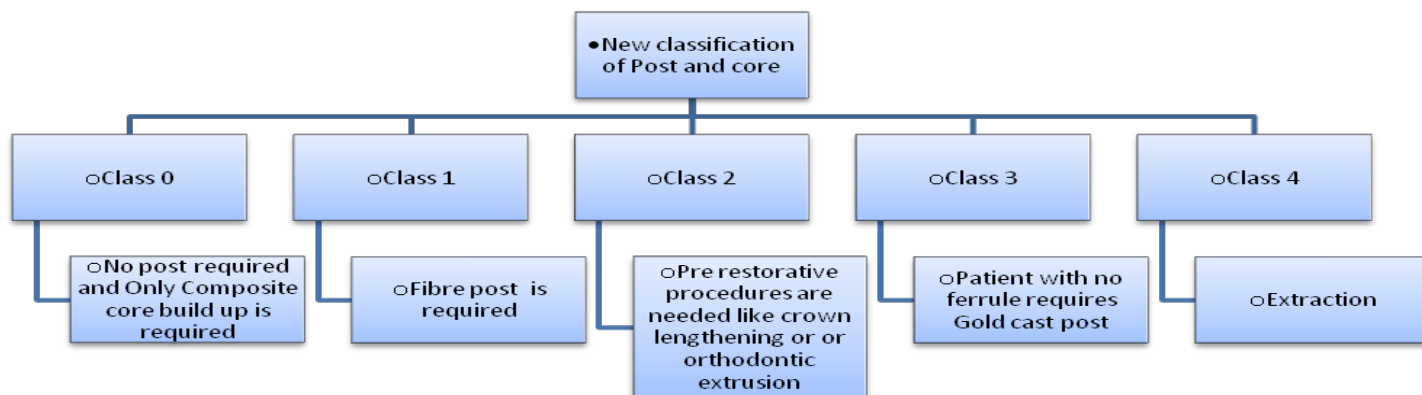
Studies suggest that the metal posts that are cemented do not strengthen the root. [14] Bonded posts are reported to strengthen the root initially in some studies, but then it was found that strengthening effect is probably lost over time as the tooth is exposed to functional stresses and the resin bond with the dentin of the root weakens. [13]

Classification

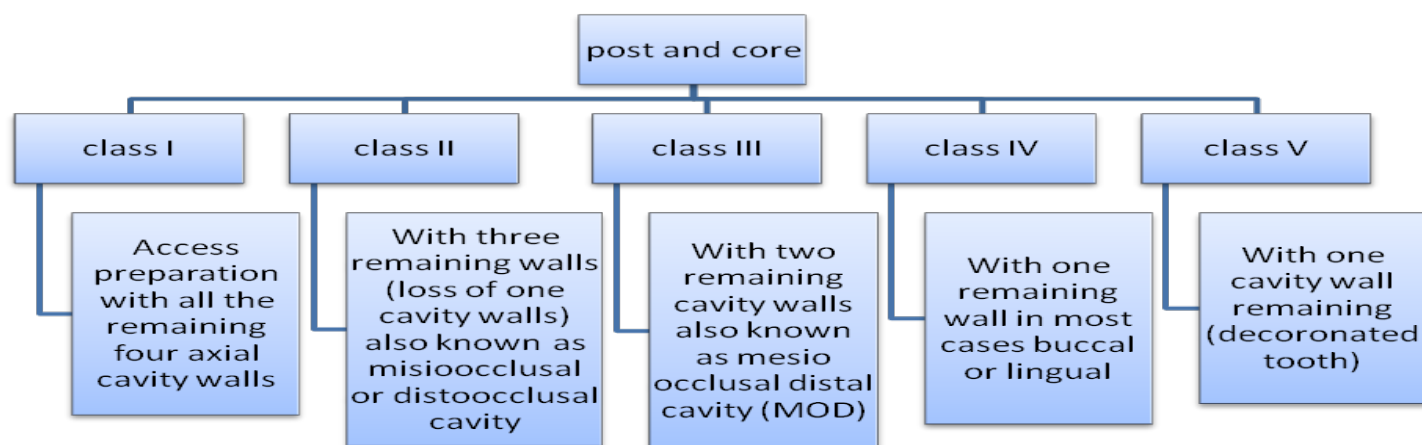
We can find several classifications for Post and Core amongst which below are few that covers from classifications different aspects: [15]



M Zarow , A Ramirez-Sebastia , G Paolone , J de Ribot Porta , J Mora , J Espona , F Durán-Sindreu , M Roig in there article classified post and core based on five categories of teeth: [16]



S Vijay Singh, Anil Chandra, I K Pandit classified post and core according to the remaining tooth structure. The classification describes five classes, depending on the number of remaining axial cavity walls: [17]



S Vijay Singh, Anil Chandra, I K Pandit gave another classification which was based on the number of primary canals in endodontically treated teeth where the teeth were divided into three groups: [17]

Class I; Class II and Class III.

Each class was further

subdivided on the basis of the percentage of remaining tooth structure as:

C- complete clinical crown

P-partial clinical crown

N-no clinical crown

Different types of posts

1. Active posts: Active posts contains threads which engage the walls of the canal. They provide more retention than passive posts. But their disadvantage is, they induce more stress into the roots than passive

posts. The threads of the active post actually engage or screw into the peri canal dentin; which produces severe apical stress levels, that may lead to root fracture. [18]Active posts are only used in short roots, where maximum retention is needed [3]

2. Passive post: passive post requires luting agent for retention. [3] They are less retentive than active posts. [8] The retention of passive posts relies mostly on the cement used for luting. Studies suggest that resin-based cements have greater bond strength than conventional cements. [19]
3. Parallel posts: Parallel post provide superior retention than tapered posts. However, more removal of the dentin is required from the apex of root canal. This generate more stress at the apex and can even cause perforation of the root canal. [20] Parallel posts are more retentive than tapered posts. [21] They produce less stress than tapered post, as wedging effect is less. Therefore, they are less likely to cause root fracture than tapered post. Studies show that they have higher success rate than tapered post. [8]
4. Tapered posts: - Tapered post follows the shape of the prepared root canal. They conserve the tooth structure. [20] however when they are placed, they have a wedging effect on the root canal. Due to this, the stress concentration on the root canal increases, which can cause fractures which are not restorable. [22] They are indicated in teeth with thin roots and delicate morphology. [8]
5. Threaded posts: Threaded posts are most retentive posts. They distribute stresses better in short roots, but the incidence of vertical fracture is increased with the use of these posts. [20]
6. Cast post: Cast post and cores were the standards for many years and are still used by some clinicians. They are custom made and fit to the canal. [22] There are studies that report a high rate of success with cast post and cores, and they offer advantages in certain clinical situations. For example, when multiple teeth require posts, it is sometimes more efficient to make an impression and fabricate them in the laboratory rather than placing a post and build-up in individual teeth as a chair-side procedure. A cast post and core may be indicated when a tooth is misaligned and the core must be angled in relation to the post to achieve proper alignment with the adjacent teeth. Cast post and cores also may be indicated in small teeth such as mandibular incisors, when there is minimal coronal tooth structure available for antirotating features or bonding. Cast post and cores are generally easy to retrieve when endodontic retreatment is necessary. [8] Their disadvantages are cast post and core procedures are expensive, time-consuming and require more than two appointments, with a potential for post and root fracture and a high risk of corrosion, when different metals were used. [20] Metals have high modulus of elasticity than dentine, therefore they have more potential to fracture the root of the teeth as compared to other posts, as they can produce more stress in the root of the teeth. [21]
7. Fiber post: A non-metallic Carbon-fiber post system was introduced in the year 1990 by Duret. The combination of fiber post, resin core, and resin cement results in interfaces having nearly similar modulus of elasticity like dentin and hence give a homogenous Monoblock effect. Although considered as having significant advantages as compared to metal post, especially with respect to mechanical properties, the carbon fiber post showed limitations of material's radiolucency and masking difficulties under all ceramic and resin composite restorations because of its grey colour. This drawback of carbon-fiber posts leads to the introduction of glass/quartz fiber posts. These posts are made of quartz or glass fiber embedded in a matrix of epoxy or methacrylate resin. [23] The mechanical properties of these posts are

similar to those of carbon posts and provide an additional

8. esthetic benefit. Fiber posts appear to be biocompatible, are easy to insert, and are time and cost-effective. [20] Studies show that fiber posts display overall higher success rate than metal post. [24] The main advantage of these posts is that by flexing slightly under load, they distribute stresses to the root dentine in a more favourable manner than metal posts. [23] The addition of fiber to a polymer matrix; have enhanced mechanical properties like strength, fracture toughness stiffness and fatigue resistance. [23]
9. Serrated post: serrations, roughening and grooves increases the retention of the post in the root canal. Serrated posts are 30-40 percent more retentive than smooth posts. [22] Serrated parallel posts distribute forces on both sides of the post. They place the root under less stress than other posts. [22]
10. Prefabricated post and core: The material for the fabrication of prefabricated post is stainless steel or nickel chromium alloy or brass or titanium alloy. They all are very rigid except titanium. They are round in shape and offer little resistance to rotational forces. Hence, they should be used only when adequate tooth structure remains. When minimum tooth remains, anti-rotational features should be incorporated into post preparation with slots or pins. The radiodensity of titanium post is similar to gutta-percha and sealer. Therefore, they are hard to detect on radiographs. They have low fracture strength and their removal is difficult. Posts made of brass can corrode. For these reason titanium and brass posts should be avoided. [3] Passive, tapered posts offer the least retention of the prefabricated posts, but allow minimal removal of radicular dentin because their tapered shape resembles

the root canal morphology. If adequate canal length is available, they are a good choice, particularly in thin roots such as maxillary premolars. Adequate length is considered to be greater than 8 mm. Additional retention can be gained with a parallel post, bonded by resin cement, or by the use of an active post [8]

11. Ceramic and zirconium post: These are known as esthetic posts. They have to be kept thicker for strength. Therefore, more removal of tooth structure has to be done. They cannot be etched; therefore, composite core build-up is not possible. Their retrievability is difficult. They require grinding for retrieval, which is tedious and dangerous, as there is risk of perforation of root of the teeth. It is not possible to grind away zirconium post from the root of the teeth. The elastic modulus of zirconium post is more than dentin, therefore chances of root fracture are more, as they transfer more stress to the root [3] [25] Studies suggest that glass-ionomer cement as well as MDP modified adhesive cement can be used for cementation of zirconia crowns [26]

To summarise according to the literature, the ideal post is: at least as long as the crown, not wider than 1/3rd the root diameter, serrated or rough or grooved and parallel. [22]

Core build up materials

The development of adhesive techniques in recent times, have changed the face of dentistry. The residual tooth structure which is left, do not require removal due to newer adhesive techniques. There is even no need for creation of micromechanical retentive features in existing tooth structure. [27] Studies suggest that conventional amalgam core showed the least fracture resistance whereas, composite resin and bonded amalgam core showed fracture resistance similar to that of natural tooth. [28]

Luting cements

Several studies suggest the survival and failure of teeth restored with posts and cores. Loss of retention of the post, fracture of the root and fracture of the post or the core are the failures. Loss of retention of post is reported as one of the most frequent types of failure. The retention of post is influenced by numerous factors, luting cements is one of them. [29] The most common luting cements for posts are zinc phosphate cement, resin cement, glass ionomer cement, and resin modified glass ionomer cement. Several studies found, the retention of the post is more when it is luted with resin cement. [29] For fiber post a self-cure or dual cure resin cement should be used. For ceramic post, a resin cement should be used along with silanating agent. [22] Studies suggest that Glass ionomer cement was found to have slightly higher retentive property than Zinc phosphate cement, but there was no much statistical significance in the difference between these two cements. [30]

Clinical procedure of post and core

The first step of any clinical procedure is recording the case history of the patient. Then diagnostic radiograph of the tooth, on which post and core has to be done is taken. From the radiograph we can determine, whether the tooth is root canal treated or not. If not, root canal of the tooth is done. From the diagnostic radiograph, we can even evaluate the root and determine the length of the post, diameter and the type of the post we can use. The ideal post placement should be three fourth of the root length. This cannot be achieved by many teeth, without compromising the apical seal. When restoring long-rooted teeth, achieving a length as close as possible to three fourths of the root is possible, whereas many teeth will have posts that are equal in length to the clinical crown because of a shorter root and the need to maintain at least 4 mm of gutta percha apical seal. Therefore, the dentist

should select a post that is as long as possible within the long axis of the tooth, and of a minimum diameter to maximize preservation of remaining dentin. [11]

There are several methods for preparing the post space like rotary instruments, heated instruments and solvents. In studies no method is found superior than other. [11] Generally, Gates Glidden drill is used. The post space should be prepared as conservatively as possible. For custom made post, impression of the prepared canal for fabrication of post is recorded. For prefabricated post, after the placement of the post, the radiograph was taken with the post inside the prepared canal, which confirms the post space and fit of the post. Then the post is luted with luting cement and placed into the root canal. Then core build-up is done and prepared and final impression is taken for final crown. [31]

Clinical significance

The teeth whose root canal treatment has been done successfully but has less coronal structure left can be restored successfully with post and core treatment. Otherwise the other option left is extraction of teeth. There are many patients whose teeth are in good condition but due to coronal fracture, teeth have to be extracted. These patients can be successfully treated with post and core treatment. There are many patients whose coronal structure is lost due to caries (no coronal structure left for teeth preparation and full coverage crown), but the teeth are periodontally firm and no mobility seen, they can be treated with complete caries removal, then root canal treatment, then post and core. The other option would be extraction of teeth. If extraction is done, there are only two options left for restoration of teeth- one option is fixed partial denture (FPD) and other is implant. In FPD according to Ante's law, minimum two abutments are used. These abutments are prepared according to the crown which has to be given. This is a less conservative

approach, as abutments are involved. The second option is implant. Implant are more expensive and time consuming treatment option.

Conclusion

Till date, no universal system of post and core is found optimal for all teeth. Although studies have found that the parallel-sided, serrated, vented post can satisfy many clinical situations. [11] Studies have found that metal posts which are used from long past can cause fracture of the root of the teeth in which post is placed, due to high concentration of stresses and can cause failure of the system.

But still, metallic posts are widely used.

Recently non-metallic posts are used widely in the market. Fiber-reinforced composite material posts are the most used systems nowadays [32] All ceramic posts and zirconium posts are the recent advances. However, many authors believe that before zirconia posts to be used widely in clinical practice, more studies are required for them [25]

References

1. H. S. C. G. a. A. S. Iris Slutzky-Goldberg, "Restoration of Endodontically Treated Teeth Review and Treatment Recommendations," International Journal of Dentistry, pp. 1-19, 2009.
2. D. B. J. Y. N. Warattama Suksaphar, "Survival rates against fracture of endodontically treated posterior teeth restored with full-coverage crowns or resin composite restorations: a systematic review," Restorative Dentistry and Endodontics. 2017 Aug;42(3):157-167, vol. 42, no. 3, pp. 157-167, 2017.
3. N. V. V. Vidyashree V, "Current concepts in the restoration of endodontically treated teeth," The journal of indian prosthodontic society, vol. 6, no. 2, pp. 63-67, 2006.
4. E. J. S. Douglas A. Terry, "Post-and-Cores: Past to Present," Dentistry today , vol. 29, no. 1, pp. 134-135, 2010.
5. D. V. S. S. D. V. F. D. D. K. H. S. Dr. Raman Mishra, "Evolution of Posts - From Rigidity to Flexibility," International Journal of Science and Research (IJSR), vol. 6, no. 5, pp. 2671-2677, 2017.
6. S. K. M. Faisal Khan, "Restoration of anterior esthetics with Richmond crown," BLDE University Journal of Health Sciences, vol. 2, no. 2, pp. 109-111, 2017.
7. M. M. Sachin Metkari, "Successful Rehabilitation of Anterior Crowns with Richmond Crown: Case Series," Journal of Dental Problems and Solutions, vol. 4, no. 2, pp. 40-43, 2017.
8. J. W. R. Richard S. Schwartz, "Post Placement and Restoration of Endodontically Treated Teeth: A Literature Review," JOURNAL OF ENDODONTICS, vol. 30, no. 5, pp. 289-301, 2004.
9. S. H. N. D. Huang TJ, "Effects of moisture content and endodontic treatment on some mechanical properties of human dentin.," journal of endodontics, vol. 18, no. 5, pp. 209-215, 1992.
10. a. a. o. endodontics, "restoration of endodontically treated teeth: The Endodontist's Perspective, Part 1," ENDODONTICS: Colleagues for Excellence, 2004.
11. L. W. Stockton, "Factors affecting retention of post systems: A literature review," THE JOURNAL OF PROSTHETIC DENTISTRY, vol. 81, no. 4, pp. 380-385, 1999.
12. J. S. Mamoun, "On the ferrule effect and the biomechanical stability of teeth restored with cores, posts, and crowns," European journal of dentistry, vol. 8, no. 2, pp. 281-286, 2014.
13. B. F. S. J. Heydecke G, "Fracture strength and survival rate of endodontically treated maxillary

- incisors with approximal cavities after restoration with different post and core systems: an in-vitro study," *Journal of Dentistry*, vol. 29, pp. 427-433, 2001.[14
14. M. D. T. L. Trope M, "Resistance to fracture of restored endodontically treated teeth.," *Endodontics and Dental Traumatology*, vol. 1, pp. 108-111, 1985.
15. A. Chandra and S. V. Singh, "A new classification of post and core," *Indian Journal Of Restorative Dentistry*, vol. 4, no. 3, pp. 56-58, 2015.
16. M. Zarow, A. Ramirez-Sebastia, G. Paolone, J. d. R. Porta, J. Mora, J. Espona, F. Duran-Sindreu and M. Roig, "A new classification system for the restoration of root filled teeth," *International Endodontic Journal*, vol. 51, pp. 318-334, 2018.
17. A. C. Sougajam Vijay Singh, "Need of a new classification for post and core failure," *Dental Hypotheses*, vol. 6, no. 4, pp. 141-145, 2015.
18. P. V. S. B. R. R. C. V. C. J. S. Paulo Cesar Freitas Santos Filho, "Effects of threaded post placement on strain and stress distribution of endodontically treated teeth," *brazilian oral research*, vol. 27, no. 4, 2013.
19. S. T. R. R. N. P. J. P. S. C. S. Y. Varun Pruthi, "Evaluation of retention and fracture resistance of different fiber reinforced posts: An in vitro study," *journal of conservative dentistry*, vol. 21, no. 2, pp. 157-161, 2018.
20. j. o. c. dentistry, "Evaluation of retention and fracture resistance of different fiber reinforced posts: An in vitro study," Varun Pruthi, Sangeeta Talwar, Ruchika Roongta Nawal, Preeti Jain Pruthi, Sarika Choudhary, Seema Yadav, vol. 21, no. 2, pp. 157-161, 2018 .
21. M. F. C. Goracci, "Current perspectives on post systems: a literature review," *australian dental journal*, vol. 56, no. 1, pp. 77-83, 2011
22. j. j. maggio, "when to place a post and how: a scientific approach to a clinical question".
23. S. B. V. M. R. D. Nupur Jhavar, "Recent Advances in Post Systems: A Review," *Journal of Applied Dental and Medical Sciences*, vol. 1, no. 3, pp. 128-136, 2015.
24. S. X. Z. Y. Y. B. J. Y. Z. K. Wang X, "Evaluation of fiber posts vs metal posts for restoring severely damaged endodontically treated teeth: a systematic review and meta-analysis.," *Quintessence International*, vol. 50, no. 1, pp. 8-20, 2019.
25. U. i. E. k. Zeynep ozkurt, "Zirconia ceramic post systems: a literature review and a case report," *Dental Materials Journal*, vol. 29, no. 3, pp. 233-245, 2010.
26. M. W. Katarzyna Walczak, "Is mechanical retention for adhesive core build-up needed to restore a vital tooth with a monolithic zirconium crown? – An in vitro study," *Acta of Bioengineering and Biomechanics*, vol. 18, no. 4, pp. 117-125, 2016.
27. J. C. F. Mannocci, "Restoration of endodontically treated teeth," *British Dental Journal*, vol. 216, pp. 341-346, 2014.
28. V. S. a. S. K. Prashant Monga, "Comparison of fracture resistance of endodontically treated teeth using different coronal restorative materials: An in vitro study," *journal of conservative dentistry*, vol. 12, no. 4, pp. 154-159, 2009.
29. A. B. S. F. A. P. A. Sahafi, "Retention of Root Canal Posts: Effect of Cement Film Thickness, Luting Cement, and Post Pretreatment," *operative dentistry*, vol. 40, no. 4, pp. 149-157, 2015.
30. D. M. M. S. D. N. L. D. S. M. Dr. Muthuraj. H, "Evaluation of Retention of Custom- Made Posts Using Different Types of Luting Cements – An In-Vitro Study," *Journal of Dental and Medical Sciences*, vol. 13, no. 12, pp. 12-18, 2014.
31. H. M. K. Milap H Karia, "Prosthetic Management of Endodontically Restored Tooth," *International Journal*

of Oral Care and Research, vol. 5, no. 1, pp. 1-4,
2017.

32. P. A. s. f. a. m. m. v. Joana Machadoa, "currently used
systems of dental posts for endodontic treatment,"
Procedia Structural Integrity , vol. 5, p. 27–33, 2017.