

Irritational Fibroma of Lower Buccal Mucosa: A Case Report

¹Dr. Shoborose Tantray, MDS, Senior Lecturer, Oral and Maxillofacial Pathology and Microbiology, Santosh Dental College and Hospital Ghaziabad

²Dr. Seema Sharma, Prof and Head, Department of Oral and Maxillofacial Pathology and Microbiology, Santosh Dental College and Hospital Ghaziabad

³Dr. Nazima Nasrullah, PhD, Prof Institute of Eminence Healthcare Chirag Delhi, New Delhi

⁴Dr. Sajad ul islam Mir, DM Department of Endocrinology, Skims Srinagar Kashmir

Corresponding author: Dr. Shoborose Tantray, MDS, Senior Lecturer, Oral and Maxillofacial Pathology and Microbiology, Santosh Dental College and Hospital Ghaziabad

Citation of this Article: Dr. Shoborose Tantray, Dr. Seema Sharma, Dr. Nazima Nasrullah, Dr. Sajad ul islam Mir, “Irritational Fibroma of Lower Buccal Mucosa: A Case Report”, IJDSIR- April - 2020, Vol. – 3, Issue -2, P. No. 96 – 100.

Copyright: © 2020, Dr. Shoborose Tantray, et al. This is an open access journal and article distributed under the terms of the creative commons attribution noncommercial License. Which allows others to remix, tweak, and build upon the work non commercially, as long as appropriate credit is given and the new creations are licensed under the identical terms.

Type of Publication: Case Report

Conflicts of Interest: Nil

Abstract

Traumatic or irritational fibroma is a general benign exophytic tumor or neoplasm of fibrous connective tissue origin that can be considered a reactionary connective tissue hyperplasia in response to trauma and irritation. They are clinically marked by solid well-demarcated rounded, sessile, or pedunculated growths covered by normal mucosa and are a relatively uncommon lesion. Local trauma can generate ulceration of these lesions. They are usually seen on the buccal mucosa but can also occur at any intra-oral site. These lesions are more common in adults and can befall at any age. A malignant transformation in such fibroma or lesion is uncommon. Simple, complete excision and removal of the cause of irritation

are the preferred treatment. It is the most common type of lesion and the treatment of choice is complete surgical excision.

Keywords: Fibroma, Lower Mucosa, Soft Tissue, Irritational Fibroma. Benign Tumour

Introduction

A general soft tissue reaction to strain from tooth/teeth or dental prostheses was first reported in 1846 as fibrous polyp and polypus. It is currently also known as Irritation fibroma, Traumatic fibroma, Peripheral fibroma, Focal fibrous hyperplasia, Inflammatory fibrous hyperplasia, Fibrous lump, or Fibroepithelial polyp[1]. The fibroma, is the common oral fibrous tumor resembling growth[2]. Traumatic fibroma is a local reactive growth and proliferation of mucosa of the oral cavity in retort to injury or irritation[3].

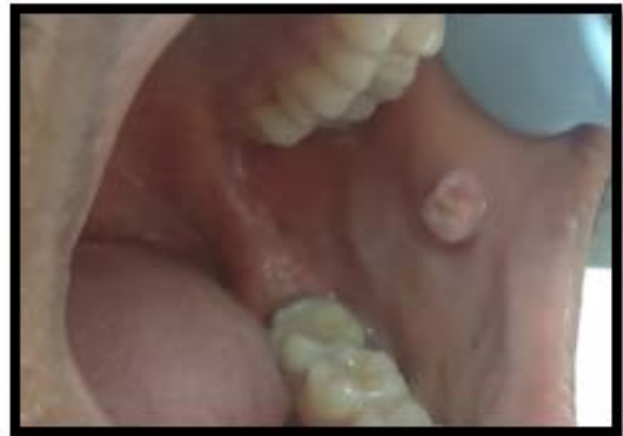Case Report

A 30 year old male reported to the Department of Oral and Maxillofacial pathology and Microbiology with a complaint of overgrowth in the left lower back region since 6-7 months. On examination, it was an asymptomatic nodular lesion of mucosal color on the lower back buccal mucosa in the region of 36 and 37 [Figure 1 (B)]. The asymptomatic lesion increased gradually in size when it was the first noticed by the patient. there was a history of chronic irritation from the left maxillary molars. (sharp cusp). (Figure 2) No history of bleeding was present from the lesion . On clinical examination, the lesion revealed a pale pink solitary, nodular, Sessile, non tender growth present on the left mandibular buccal mucosa in line of occlusion. wrt 36, 37 measuring approx. 6mm x 7mm x 5mm was Soft in consistency . By history and clinical findings, a provisional diagnosis of irritation fibroma was given. The list of differential diagnosis included lipoma, chronic fibrous epulis, peripheral giant cell granuloma, osteosarcoma, chondrosarcoma, pyogenic granuloma, and peripheral odontogenic fibroma. Complete hemogram revealed all blood cell counts were within normal limits. As the patient reported discomfort during mastication and speaking, it was decided to go for an excisional biopsy performed under local anesthesia using a scalpel. The surgical exposure revealed that the lesion was well demarcated from buccal mucosa permitting relatively easy separation of a tumor from its soft tissue bed and suturing was done. The excised tissue was received by Department of Oral Pathology for histopathological examination. On gross examination the excised tissue was creamish in colour, round shaped, soft in consistency measuring about 6mm x 7mm x 5mm in size . (Figure 3) On Histopathological examination the given soft tissue revealed stratified squamous parakeratinized epithelium covering the

connective tissue stroma The connective tissue is collagenous with dense collagen fibres, fibroblasts . (Figure 4 scanner view). The connective tissue stroma consists of dense bundles of collagen, blood vessels and spindle shaped fibroblast (Figure 5&6) (10x & 40x view) On the basis of clinical and histopathological reports thus, a final diagnosis of irritation fibroma was given.



Figure 1: (A) Extra oral view.



(B) Intra oral view: showing a nodular growth on the left buccal mucosa in line of occlusion.

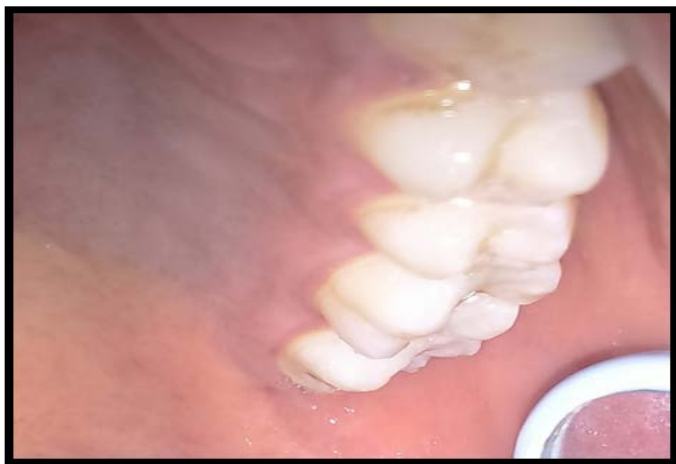

Figure 2: Intra oral view :showing a sharp mesiobuccal cusp of maxillary second molar.

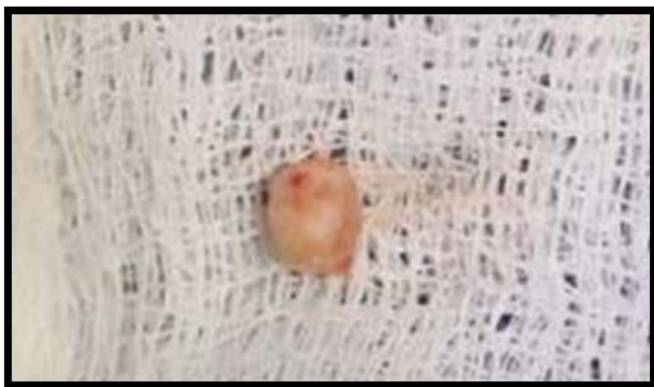

Figure 3: On gross examination the excised tissue was creamish in colour, round shaped, soft in consistency measuring about 6mm x 7mm x 5mm in size.

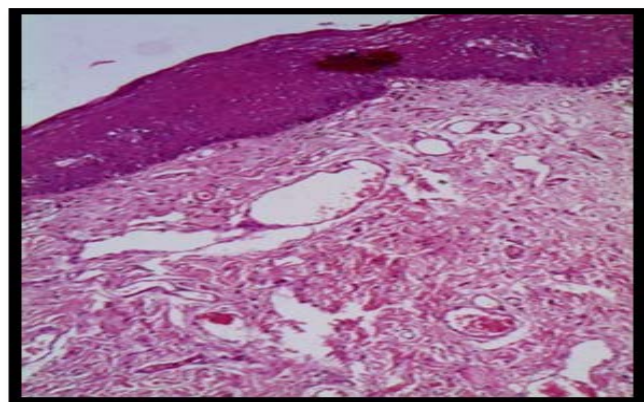


Figure 4: 4X view: Shows stratified squamous parakeratinized epithelium covering the connective tissue stroma. The connective tissue is collagenous with dense collagen fibres and fibroblasts.

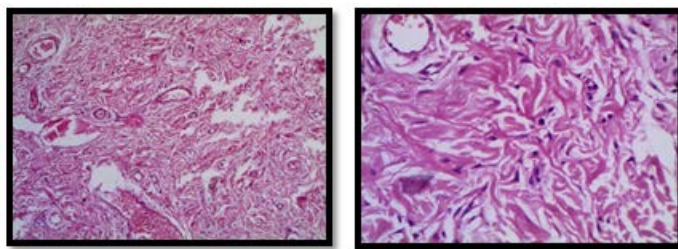


Figure 5 & 6: Connective tissue shows dense bundles of fibers and spindle shaped fibroblasts.

Discussion

Irritational fibromas are the most common benign soft tissue tumors seen in the oral cavity. It is also known as focal fibrous hyperplasia, oral fibroma or as fibromatosis. It is characterized by fibrous tissue and mineralized material that does not fuse with its surroundings. Thus, the lesion is demarcated or encapsulated (rhinology). Irritational fibromas show variable amounts of woven and lamellar bone trabeculae and osteoblasts may rim the trabeculae. A psammomatoid variant is a subtype of irritational fibroma with distinctive histomorphological and clinical features.[4,5] Histologically, spherical ossicles with irregular seams of osteoid in a highly cellular fibrous tissue, separated by fibrous tissue were observed.[1] It is a slowly progressive lesion with the potential to create a sizeable defect in the orbit and the sinonasal tract.

According to WHO classification of jaw tumors, juvenile aggressive irritational fibroma is divided into two types: Juvenile psammomatoid irritational fibroma and juvenile trabecular irritational fibroma.[3] The juvenile psammomatoid irritational fibroma mainly involves the orbit and paranasal sinuses seen in older people. Juvenile trabecular irritational fibroma mainly affects the jaw bones in children and adolescents.[6] Psammomatoid irritational fibroma was initially described by Gogli as early as in 1949.[4] In 1985, Margo described psammomatoid juvenile irritational fibroma as a distinctive solitary fibrous osseous lesion of young adults.

Psammomatoid juvenile irritational fibroma is not classified under osseous tumors of the jaw in the Armed Forces Institute of Pathology book. Afflicted individuals tend to be young. In general, the patients with psammomatoid irritational fibroma are a few years older than those with trabecular psammomatoid irritational fibroma. But as in the case of trabecular juvenile irritational fibroma, there is no sex predilection. The majority of psammomatoid irritational fibromas originate in the paranasal sinuses and about 10% have been reported to originate in the calvarium. In this study, the tumor was in the paranasal sinuses. Clinically, it presents as proptosis, visual complaints, nasal obstruction, ptosis, and papilledema. Confusion between trabecular juvenile irritational fibroma and psammomatoid irritational fibroma is due to the use of term juvenile irritational fibroma to describe these two entities. Trabecular juvenile irritational fibroma is trabecular, i.e., favors gnathic bones, whereas psammomatoid juvenile irritational fibroma is psammomatoid, i.e., involves periorbital bones. This case fits into the criteria. The patient came with a recurrent lesion after 6 months. Campos and Gomez[5] and Weathers and Campbell[6] suggested that the stellate and multinucleate cells of giant cell fibroma have a fibroblast phenotype and are large atypical fibroblasts. Irritational fibromas may happen at any age but are more typical in young adults. A variant of irritational fibroma, juvenile (aggressive) irritational fibroma, has been described in children and young adults who are younger than 15 years of age.[6] Females are more commonly affected than males and anterior maxilla is the most common location of involvement where lesion predominates in the second decade of life.[4] Hormonal influences may play a role, given the higher incidence of peripheral irritational fibroma among females, increasing occurrence in the second decade, and declining incidence after the third

decade.[5-7] In the present case, posterior mandible was involved, and the patient was of third decade. However, interestingly in our case, the patient was male although it is seen more commonly in females. Histologically, few benign lesions are also fibro-osseous in nature. They are composed of cellular fibrous tissue with areas of fibrovascular connective tissue that often contain an inflammatory component with abundant plasma cells. Usually Ossification is seen in the cellular zone and shows considerable variations both quantitatively and qualitatively. From small rounded calcified deposits to large trabecular bone areas surrounded by osteoblasts may be observed.[8-11] The predominant cell of this lesion is a bland spindle cell. Mitotic figures are rare. Admixed in the fibrous background are irregularly shaped osseous islands. The histopathologic hematoxylin and eosin stained section of lesion revealed stratified squamous parakeratinized epithelium covering the connective tissue stroma. The connective tissue is collagenous with dense collagen fibres and fibroblasts. The fibrous tissue is of varying cellularity with few chronic inflammatory cells. (Figure 4 scanner view). The connective tissue stroma consists of dense bundles of collagen, blood vessels and spindle shaped fibroblast. The most common site for such benign lesion is buccal mucosa, tongue, and lower labial mucosa. In the present case the lesion was present on the most common site i.e buccal mucosa. On clinical inspection appearance of such lesion is lighter in color than the surrounding normal tissue with surface often appearing white because of hyperkeratosis or with surface ulceration caused by secondary trauma.[11-13] Bad oral habits lead to imbalance in orofacial muscular when repeated excessively becomes harmful, contributing to associate with alterations in bone growth, dental malposition, and dentofacial abnormalities. Biting, licking, or sucking of lips and cheeks are frequently accompanied by chapping,

dryness, erosion, irritation of one of both lips, and/or vermilion borders.[11-13] The treatment of choice for peripheral irritational fibroma is local resection with peripheral and deep margins including both the periodontal ligament and the affected periosteal component.[2,9] In addition, elimination of the local etiological factors such as plaque and tartar is required.[2,8] The teeth associated with peripheral irritational fibroma are generally not mobile, though there have been reports of migration secondary to bone loss.[2,9,13]

Conclusion

Irritational/traumatic fibroma is a benign lesion with significant growth potential. This lesion is mainly characterized by slow growing soft tissue nodule primarily involving the buccal mucosa, maxilla, and mandible in the second decade of life. Many patients do not approach a dentist as it is mainly asymptomatic during initial stages until the size increases considerably. Conservative excisional biopsy is curative, and its findings are diagnostic; however, recurrence is possible if the exposure to the offending irritant persists. In rural India due to lack of proper guidance, early diagnosis and prompt treatment of such lesions is not possible. Treatment consists of complete surgical excision of the lesion, and these lesions have considerable reoccurrence rates hence requiring close post-operative follow-up visits

References

1. Farquhar T, Maclellan J, Dymont H, Anderson RD. Peripheral irritational fbroma: A case report. J Can Dent Assoc 2008;74:809-12.
2. Kumar SK, Ram S, Jorgensen MG, Shuler CF, Sedghizadeh PP. Multicentric peripheral ossifying fbroma. J Oral Sci 2006;48:239-43.
3. García de Marcos JA, García de Marcos MJ, Arroyo Rodríguez S, Chiarri Rodrigo J, Poblet E. Peripheral ossifying fibroma: A clinical and immunohistochemical study of four cases. J Oral Sci 2010;52:95-9.
4. Bhaskar SN, Jacoway JR. Peripheral fibroma and peripheral fbroma with calcification: Report of 376 cases. J Am Dent Assoc 1966;73:1312-20.
5. Campos E, Gomez RS. Immunocytochemical study of giant cell fbroma. Braz Dent J 1999;10:89-92.
6. Weathers DR, Campbell WG. Ultrastructure of the giant-cell fbroma of the oral mucosa. Oral Surg Oral Med Oral Pathol 1974;38:550-61.
7. Sarode SC, Sarode GS, Waknis P, Patil A, Jashika M. Juvenile psammomatoid ossifying fibroma: A review. Oral Oncol 2011;47:1110-6.
8. Smith SF, Newman L, Walker DM, Papadopoulos H. Juvenile aggressive psammomatoid ossifying fibroma: An interesting, challenging, and unusual case report and review of the literature. J Oral Maxillofac Surg 2009;67:200-6.
9. Rangil JS, Silvestre FJ, Bernal JR. Cemento-irritational fbroma of the mandible: Presentation of a case and review of the literature. J Clin Exp Dent 2011;3:e66-9.
10. Pal S, Hegde S, Ajil V. The varying clinical presentations of peripheral ossifying fbroma: A report of three cases. Rev Odonto Cien 2012;27:251-5.
11. Dhanuthai K, Banrai M, Limpanaputtajak S. A retrospective study of paediatric oral lesions from Thailand. Int J Paediatr Dent 2007;17:248-53.
12. Chi D, Kanellis M, Himadi E, Asselin ME. Lip biting in a pediatric dental patient after dental local anesthesia: A case report. J Pediatr Nurs 2008;23:490-3.
13. Leache EB, Naranjo AM, Couso R, Conzalez DG. Are the oral piercing important in the clinic? Dent Pract 2006;1:45-9.