

Impacted Mandibular Third Molar and Associated Pathologies: A Descriptive Study

¹Shreedevi Bhoi, Reader, Department of Oral & Maxillofacial Surgery, Hazaribag College of Dental Sciences and Hospital, Hazaribag, Jharkhand 853001

²Rashmi. Jayanna, Prof & HOD, Department of Paediatrics & Preventive Dentistry, Hazaribag College of Dental Sciences and Hospital, Hazaribag, Jharkhand 853001

³Supreya Patel, Senior Lecturer, Department of Paediatrics & Preventive Dentistry, Hazaribag College of Dental Sciences and Hospital, Hazaribag, Jharkhand 853001

⁴Ramya Kalyanpur, Associate Professor, Department of Public Health & Dentistry, SDM College of Dental Sciences & Hospital, Dharwad, Karnataka.

⁵Jayesh. Anand, ⁵Sr. Lecturer, Department of Oral & Maxillofacial Surgery, Hazaribag College of Dental Sciences and Hospital, Hazaribag, Jharkhand 853001

⁶Arundhati Singh, Sr. Lecturer, Department of Oral & Maxillofacial Surgery, Hazaribag College of Dental Sciences and Hospital, Hazaribag, Jharkhand 853001

Corresponding author: Shreedevi Bhoi, Reader, Department of Oral & Maxillofacial Surgery, Hazaribag College of Dental Sciences and Hospital, Hazaribag, Jharkhand 853001

Citation of this Article: Shreedevi Bhoi, Rashmi. Jayanna, Supreya Patel, Ramya Kalyanpur, Jayesh. Anand, Arundhati Singh, “Impacted Mandibular Third Molar and Associated Pathologies: A Descriptive Study”, IJDSIR- May - 2020, Vol. – 3, Issue -3, P. No. 01 – 06.

Copyright: © 2020, Shreedevi Bhoi, et al. This is an open access journal and article distributed under the terms of the creative commons attribution noncommercial License. Which allows others to remix, tweak, and build upon the work non commercially, as long as appropriate credit is given and the new creations are licensed under the identical terms.

Type of Publication: Original Research Article

Conflicts of Interest: Nil

Abstract

Aim of the study: To assess the pathologies associated with the impacted mandibular third molar and the need for the removal of impacted tooth.

Material & Methods: This study was conducted on total number of 300 patients, who underwent surgical removal of impacted mandibular third molar in the Department of Oral & Maxillofacial Surgery from January 2019 to December 2019, both genders were included and the age group was ranging from 17-60 years. Factors assessed in

this study were type of Impaction and associated pathologies such as distal surface caries of second molar, Pocket formation, Cyst formation and space infection.

Results: A total of 300 impacted mandibular third molar surgical extractions were carried out during the study period from January 2019 to December 2019. According to Winter`s classification, Mesioangular impacted teeth were 117 (39%), Horizontal 101 (33.67%), Distoangular 45 (15%), Vertical 37 (12.33%). The most prevalent pathologic condition caused by mandibular third molar

impacted teeth was caries on distal surface of second molar 156 (52%), followed by pocket formation 91 (30.33%), space infection 37 (12.33%) and cyst formation 4 (1.3%).

Conclusion: In this study the most common type of impaction found was Mesioangular with most common associated pathology was Dental Caries.

Keywords: Impaction, Mandibular third molar, Associated Pathology.

Introduction

The word impaction is originated from the Latin word “impact” means organ or structure, which because of an abnormal mechanical condition has been prevented from assuming its normal position. William stated impacted tooth as one which is completely or partially unerupted and is positioned against another tooth, bone, or soft tissue so that its further eruption is unlikely¹. Mead has defined an impacted tooth as a tooth that is prevented from erupting into position because of malposition, lack of space, or other impediments. Later, Peterson characterized impacted teeth as those teeth that fails to erupt into the dental arch within the expected time. In 2004, Farman wrote that impacted teeth are those teeth that prevented from eruption due to a physical barrier within the path of eruption^{2, 3, 4}. The third molar impaction occurs in about 73% of the young adults, these teeth generally erupt between the ages of 17 and 21 years, and it has been reported that the third molar eruption varies with race^{5, 6, 7}. The average age for the eruption of mandibular third molars in male is approximately 3 to 6 months ahead of females⁸. Factors such as the nature of the diet that may lead to attrition, reduced mesiodistal crown diameter, degree of use of the masticatory apparatus and genetic inheritance also affect the timing of third molar eruption. It has been suggested that the major basic cause of aberrant/impacted teeth in the adults of Western Europe,

Great Britain and Ireland, U.S.A, and Canada is due to artificial feeding of babies, the habits developed during childhood, due to cross breeding, more consumption of sweet food by the children and youth which produces disproportion in the jaws and thus the teeth^{8, 9}. Most authors claim that the incidence of mandibular third molar impaction is higher in females^{7, 10, 11}.

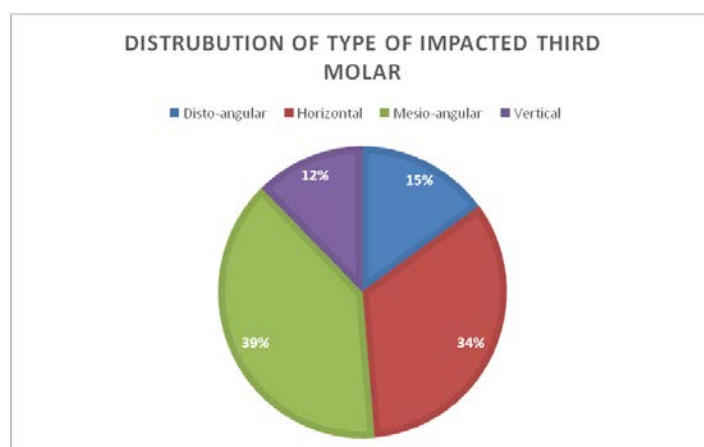
When impacted mandibular molars are symptoms free, it does not necessarily relate to lack of other pathologic conditions¹², also symptoms associated with the sequelae of presence and removal of impacted mandibular third molars affects oral health related quality of life of patient^{13, 14}. Reported pathologies that are associated with retained and impacted third molars include; cystic lesions, neoplasms, pericoronitis, periodontitis and pathological root resorption as well as injurious effects on the adjacent molar teeth especially distal caries formation^{15, 16}.

Third molars impaction is a global clinical condition that is rising^{17, 18}. Literature is still lacking on the reported cases of associated pathologies with impacted mandibular third molars despite its richness in prevalence and its surgical removal^{19, 20}. In view of these factors, this study was conducted to assess the pathologies associated with the impacted mandibular third molar and the need for the removal of impacted tooth.

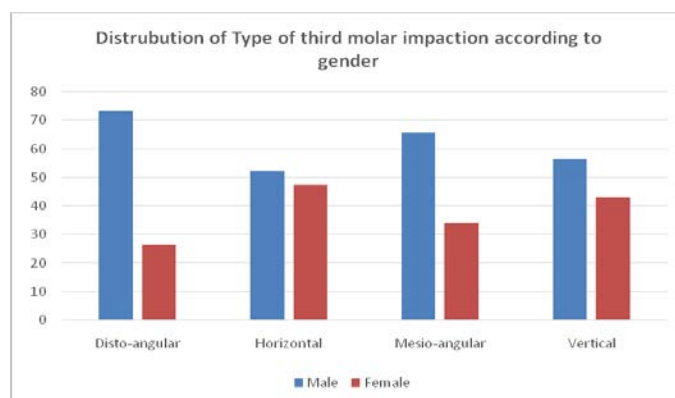
Material & Methods: The study was conducted on total number of 300 patients, during the period of January 2019 to December 2019, who underwent surgical removal of mandibular third molar in the Department of Oral & Maxillofacial Surgery. This study included age group of 17-60 years with both the genders. Factors assessed in this study were 1) Type of Impaction 2) Association of impaction and caries on distal surface of second molar 3) Association of impaction and pocket formation on second molar 4) Association of impaction and cyst formation 4) Association of impaction and space infection. Patient chief

complaint, age, gender, medical history was recorded and clinical examination and radiographic examination was carried out to assess the type of impaction (According to Winter`s Classification) and associated pathologies, and collected database was statistically analyzed. Patients who underwent surgical removal for Orthodontic reason were excluded from this study.

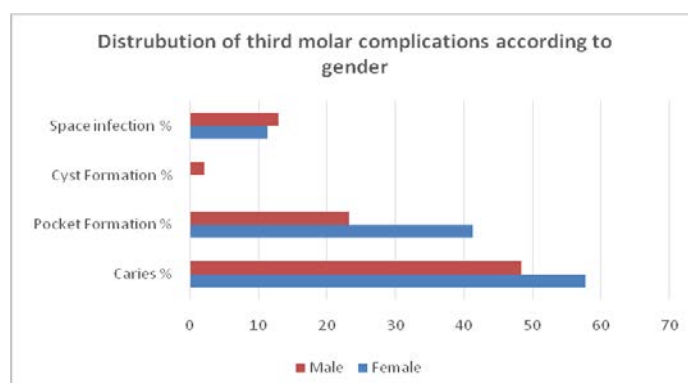
Results: A total number of 300 mandibular impacted third molar surgical extractions were carried out during the study period with, 116 (38.6%) females and 184 (61.4%) males (F: M = 1:1.7). According to Winter`s classification Mesioangular impacted teeth were 117 (39%), Horizontal 101 (33.67), Distoangular 45 (15%) and vertical 37 (12.33%) (Fig1).



In relation to gender 12 females (26.6%) and 33 males (73.3%) had distoangular impaction, 48 females (47.5%) and 53 males (52.4%) showed horizontal impactions, 40 females (34.1%) and 77 males (65.8%) had mesioangular impactions and 16 females (43.2%) and 21 male (56.7%) showed vertical impaction (fig 2). The statistical analysis showed that there was no significant difference in the prevalence of impacted mandibular third molar teeth with regard to gender (P=0.060)



Out of 300 patients, 288 patients (96%) had associated pathology and 12 patients (4%) did not report with any associated pathologies. Out of 288 patients, 160 males (55.56%) and 128 were females (44.44%). Distal caries on the second molar tooth accounted for the highest number of associated pathologies 156 (52%) followed by pocket formation 91(30.33%), space infection 37 (12.33%) and cyst formation 4 (1.3%) (Figure 3).



When associated dental caries was correlated with spatial relationship of the impacted mandibular third molar, mesio-angular impaction was highly associated with dental caries 81(69.2%), while vertical impaction was less associated with dental caries 7 (18.9%), which was statistically significant (P = 0.000) (Table 1).

Type of Impaction	Caries on distal surface of second molar	
	Absent n (%)	Present n (%)
Disto-angular	36 (80%)	9 (20%)
Horizontal	42 (41.5%)	59 (58.4%)

Mesio-angular	36 (30.7%)	81(69.2%)
Vertical	30 (81%)	7 (18.9%)
Total	144 (48%)	156 (52%)
Chi-square value = 50.27, df =3, p = .000		

Table 1: Association between mandibular third molar impaction and Caries

When associated pocket formation was correlated with spatial relationship of the impacted mandibular third molar, mesio-angular impaction was mostly associated with pocket formation 44 (37.6%), while Disto angular was least associated 4 (8.8%), which was statistically significant P = 0.000 (Table 2).

Type of Impaction	Pocket formation	
	Absent n (%)	Present n (%)
Disto-angular	41 (91.1%)	4 (8.8%)
Horizontal	64 (63.3%)	37 (36.6%)
Mesio-angular	73 (62.3%)	44 (37.6%)
Vertical	31 (83.7%)	6 (16.2%)
Total	209 (69.6%)	91 (30.3%)
Chi-square value = 18.11, df =3, p = .000		

Table2: Association between mandibular third molar impaction and pocket formation

When cyst formation was correlated with spatial relationship of the impacted mandibular third molar, disto-angular impaction was highly associated with cyst formation 3(6.6%), while horizontal impaction was least associated with cyst formation 1(0.1%), which was statistically not significant (P = 0.008) (Table 3).

Impacted Teeth	Cyst formation	
	Absent n (%)	Present n (%)
Disto-angular	42 (93.3%)	3 (6.6%)
Horizontal	100 (99%)	1 (0.1%)
Mesio-angular	117 (100%)	0 (0%)
Vertical	37 (100%)	0 (0%)
Total	296 (98.6%)	4 (1.3%)
Chi-square value = 11.90, df =3, p = .008		

Table 3: Association between mandibular third molar impaction and cyst formation

When space infection was correlated with spatial relationship of the impacted mandibular third molar, disto-angular impaction was mostly associated with space infection 13 (28.3%), while mesioangular impaction was least associated 8 (6.9%), with a statistical significant difference of P = 0.000 (Table 4).

Impacted Teeth	Space infection	
	Absent n (%)	Present n (%)
Disto-angular	33 (71.7%)	13 (28.3%)
Horizontal	93 (92%)	8 (7.9%)
Mesio-angular	108 (93.1%)	8 (6.9%)
Vertical	29 (78.3%)	8 (21.6%)
Total	263 (87.7%)	37 (12.3%)
Chi-square value = 19.29, df =3, p = .000		

Table 4: Association between mandibular third molar impaction and space infection

Discussion

Disagreements continue to swirl the issue of third molar retention among researchers and clinicians despite several informed reasons to make the clinician take a position. As the controversies persist, advocates of retaining third molars have justified this by the morbidity associated with the surgical extraction of these teeth²⁰. Similarly, lacks of symptoms have also been a reason for retaining impacted third molars¹⁸. Other clinicians have recommended a wait and see approach and when symptomatic should be removed^{21, 22}. Very few studies have reported early removal based on possibility of associated pathologies with the impacted tooth¹². It is therefore important that retained wisdom teeth are judiciously checked for signs of pathology because most of them are either impacted or partially erupted¹⁸. Male predilection was observed in our study which doesn't upheld previous findings on gender predilection of third molars^{18, 23}.

In this study most frequent type of impaction found was Mesio-angular impaction (39%) this was in accordance

with other studies¹⁵, followed by horizontal impaction (33.67%), distoangular (15%) and vertical (12.33%).

In terms of indications for third molar extraction, caries and its sequelae and pericoronitis accounted for most of the reasons for third molar extraction. This was supported by previous studies on the indications for third molar removal¹⁸. Latest evidence has suggested an increase in periodontal probing depths, associated with an impacted mandibular third molar¹⁵. The exploratory depth leads to stagnation areas for pathological bacteria proliferation that will further lead to deep periodontal disease¹⁵. We also observed that deep probing depths were also associated with other pathological conditions like caries. These combined pathologies have been reported in the literature⁵. In our study out of 288 patients, distal caries 156 (52%) on the second molar tooth accounted for the highest number of associated pathologies which was in accordance with other studies where they found, distal surface caries of second mandibular molar as a common pathology associated with impacted mandibular third molar especially the mesio angular impaction because of the angulation^{5, 15, 18}, followed by pocket formation 91(30.33%) Similar to other studies, they are most seen with mesio angular impaction because of stagnation and difficult to clean¹⁸, studies show low incidence of cyst and associated impacted mandibular third molar might be because of the fact that most pathologies go unnoticed as many practitioner discard the erupted tissues after surgical removal of the impacted teeth rather than sending the tissues for histopathological examination which was in consistent with our studies 4 (1.3%). Our study revealed 12.33% of space infection as an associated pathology with impacted mandibular third molar could be attributed to secondary to dental caries in impacted tooth or pocket formation as an individual cause or combination of both⁵.

Conclusion

Distal surface of second mandibular molar caries and pocket formation between the mandibular impacted teeth, were the most frequent associated pathology in the current study. Dental practitioners should be vigilant and look out for these associated pathologies in order to take informed decision on removal or retention of an impacted tooth when symptomatic or not.

References

1. William HA. Oral and Maxillofacial Surgery. 5th ed. Philadelphia, PA: WB Saunders; 1975. p. 1859.
2. Archer WH. Oral Surgery: A Step-By-Step Atlas of Operative Techniques, 4th ed. Philadelphia: W.B. Saunders Company; 1966. p. 507-10.
3. Peterson LJ. Principles of Management of Impacted Teeth. In: Peterson LJ, Ellis E III, Hupp JR, Tucker MR, editors. Contemporary Oral and Maxillofacial Surgery, 3rd ed. St. Louis: Mosby; 1998. p. 215-48.
4. Agarwal KN, Gupta R, Faridi MM, Kalra N. Permanent dentition in Delhi boys of age 5-14 years. Indian Pediatr. 2004 Oct; 41(10):1031-5. [Medline: 15523129]
5. Santosh P. Impacted mandibular third molars: Review of literature and a proposal of a combined clinical and radiological classification. Ann Med Health Sci Res 2015; 5:229-34.
6. Pahkala R, Pahkala A, Laine T. Eruption pattern of permanent teeth in a rural community in northeastern Finland. Acta Odontol Scand 1991; 49:341-9.
7. Kruger E, Thomson WM, Konthasinghe P. Third molar outcomes from age 18 to 26: Findings from a population based New Zealand longitudinal study. Oral Surg Oral Med Oral Pathol Oral Radiol Endod 2001; 92:150-5.
8. Hattab FN, Alhajja ES. Radiographic evaluation of mandibular third molar eruption space. Oral Surg Oral

- Med Oral Pathol Oral Radiol Endod. 1999 Sep; 88(3):285-91. [Medline: 10503855].
9. Alling CC, Alling RD. Indications for management of impacted teeth. In: Alling CC, Helfrick JF, Alling RD, editors. *Impacted Teeth*. Philadelphia: W.B. Saunders; 1993. p. 49-54.
 10. Yuasa H, Sugiura M. Clinical postoperative findings after removal of impacted mandibular third molars: prediction of postoperative facial swelling and pain based on preoperative variables. *Br J Oral Maxillofac Surg*. 2004 Jun; 42(3):209-14.
 11. Juodzbaly G, Daugela P. Mandibular Third Molar Impaction: Review of Literature and a Proposal of a Classification. *J Oral Maxillofac Res* 2013;4(2):e1
 12. White RP, Proffit WR (2011) Evaluation and management of asymptomatic third molars: lack of symptoms does not equate to lack of pathology. *Am J Orthod Dentofacial Orthop* 140(1): 10-16.
 13. Braimah RO, Ndukwe KC, Owotade FJ, Aregbesola SB (2016) Oral Health Related Quality of Life (OHRQoL) following third molar surgery in Sub-Saharan Africans: An observational study. *Pan Afr Med J* 25: 97
 14. Braimah RO, Ndukwe KC, Owotade FJ, Aregbesola SB (2017) Impact of oral antibiotics on health related quality of life outcomes in Nigerian patients following mandibular third molar surgery. *Niger J Clin Pract* 20(9): 1189-1194.
 15. Pentapati KC, Gadicherla S, Smriti K, Vineetha R. Association of impacted mandibular third molar with caries on distal surface of second molar. *Pesquisa Brasileira em Odontopediatria e Clínica Integrada* 2019; 19:e4455
 16. Khawaja NA, Khalil H, Parveen K, Al-Mutiri A, Al-Mutiri S, et al. (2015) A Retrospective Radiographic Survey of Pathology Associated with Impacted Third Molars among Patients Seen in Oral & Maxillofacial Surgery Clinic of College of Dentistry, Riyadh. *J Int Oral Health* 7(4): 13- 17.
 17. Owotade FJ (1999), Current concepts in the management of impacted third molars. *Nig J Med* 8: 135-138.
 18. Braimah Ramat Oyebunmi. Complications Associated with The Occurrence of Impacted Mandibular Third Molars in Saudi Arabian Sub-Population: Najran Province Experience. *Am J Biomed Sci & Res*. 2019 - 3(3). AJBSR.MS.ID.000669.
 19. Obiechina AE, Arotiba JT, Fasola AO (2001) Third molar impaction: evaluation of the symptoms and pattern of impaction of mandibular third molar teeth in Nigerians. *Odontostomatol Trop* 24(93): 22-25.
 20. Campbell JH (2013) Pathology Associated with the Third Molar. *Oral Maxillofacial Surg Clin N Am* 25(1): 1-10.
 21. Kandasamy S (2011) Evaluation and management of asymptomatic third molars: watchful monitoring is a low-risk alternative to extraction. *Am J Orthod Dentofacial Orthop* 140(1): 11-17.
 22. Hill CM (2006) Removal of asymptomatic third molars: an opposing view. *J Oral Maxillofac Surg* 64(12): 1816-1820.
 23. Quek SL, Tay CK, Tay KH, Toh SL, Lim KC (2003) Pattern of third molar impaction in a Singapore Chinese population: a retrospective radiographic survey. *Int J Oral Maxillofac Surg* 32(5): 548-552.