

Dyke Davidoff Masson Syndrome-Oral Manifestations

¹Banerjee Sohini, M.D.S., Periodontology, Institutional Affiliations: Assistant Professor, Dept. of Periodontics, Dr. R. Ahmed Dental College & Hospital, Kolkata.

²Dr. Debkamal Kar, Ex Post Graduate Student, Dept of Oral & Maxillofacial Pathology, Guru Nanak Institute of Dental Sciences & Research, Kolkata.

Corresponding Author: Banerjee Sohini, M.D.S., Periodontology, Institutional Affiliations: Assistant Professor, Dept. of Periodontics, Dr. R. Ahmed Dental College & Hospital, Kolkata.

Citation of this Article: Banerjee Sohini, Kar Debkamal, “Dyke Davidoff Masson Syndrome-Oral Manifestations”, IJDSIR- February - 2020, Vol. – 3, Issue -1, P. No. 440 – 443.

Copyright: © 2020, Banerjee Sohini, et al. This is an open access journal and article distributed under the terms of the creative commons attribution noncommercial License. Which allows others to remix, tweak, and build upon the work non commercially, as long as appropriate credit is given and the new creations are licensed under the identical terms.

Type of Publication: Case Report

Conflicts of Interest: Nil

Abstract

A twenty year old female patient reported with complaints of gum swelling and bleeding from gums for last six to eight months associated with additional medical findings of seizures, hemi-facial atrophy, left sided hemiparesis of the body, mental retardation, impaired speech, and learning disabilities. Patient was on anti-convulsant drug for last three years due to recurrent seizures. Intra-oral examination revealed gingival over-growth in anterior teeth region along with unilateral gingival enlargements in left posterior teeth region with the abundant deposition of plaque and calculus. Advanced radiographic imaging (MRI) revealed right sided cerebral atrophy which along with the history of seizures, mental retardation diagnosed the case to be uncommon condition namely Dyke Davidoff Masson syndrome.

Keywords: Gingival enlargements, Hemi-facial atrophy, Hemiparesis, Seizures.

Introduction

Dyke Davidoff Masson syndrome was initially described by as skull radiographic and pneumato-encephalographic changes in the series of nine patients whose clinical characteristics included hemiparesis, seizures, facial asymmetry, and mental retardation which was proposed in 1933.^[1-6] It usually occurs due to an insult to the developing brain in fetal or early childhood period.^[2-4]

It is a rare condition resulting in atrophy or hypoplasia of one cerebral hemisphere (hemi-atrophy) along with characterization of variable degrees of facial asymmetry, recurrent seizures, contralateral hemiparesis, and mental retardation, speech and language disorders along with learning disabilities along with psychiatric manifestations in some cases.^[2-6] The male predominance is usually seen along with left cerebral hemisphere involvement.^[4-8] Age of presentation depends on the time of neurologic insult, and characteristic changes may be seen only in adolescence. Imaging studies usually reveal unilateral

loss of volume of brain and calvarial changes, cerebral atrophy, ventricular dilatation and enlargement of sulci.^[5-7]

This case report will highlight about the oral manifestations of Dyke Davidoff Masson Syndrome in a female patient having anti-convulsant drugs for management of occasional seizures associated with the syndrome.

Case report

A female patient aged 20 years reported to the department along with the chief complaint of gum swelling, bleeding from gums for last six to eight months. The patient was accompanied by her mother. On enquiring about the medical history, her mother reported that she was having history of recurrent seizures since early childhood, and she was also admitted to the hospital a few years back (approximately three years) for the same reason and was having medications for preventing seizures (anti-convulsants, Phenytoin 300 mg daily) since then. She was also reported that her daughter had a history of fall on the ground while playing during her early childhood days and she slowly developed deteriorated mental status and difficulty in learning and communications since then. She was then consulted with the general physician by her parents but further investigations, treatments were not done.

On general examination, facial asymmetry was noted with the hemiparesis of left side of body along with mental retardation, impaired speech, delayed milestones and reduced IQ. The asymmetry in upper limbs (hands) were also noted. The magnetic resonance imaging (MRI) of brain revealed right sided cerebral hemi-atrophy along with dilation of left lateral ventricle and compensatory calvarium thickening [Fig.1]. The medical report of the patient revealed that she was already diagnosed with Dyke Davidoff Masson syndrome based on clinical, radiological findings and having anti-convulsant (Phenytoin 300mg

daily) for last three years and was under periodic neurological check-ups.

On intra-oral examination, generalized gingival swelling was noted on the buccal aspect of upper and lower anterior teeth [Fig.2]. The typical firm, beaded appearance of drug induced gingival enlargements involving the marginal, interdental, and attached gingiva were noted on upper anterior teeth covering most of the crown portions. However, gingival enlargements were only noted in the left posterior teeth regions of both jaws along with accumulations of plaque and calculus [Fig.3 & Fig.4]. Increased tooth mobility were noted in left upper and lower molar teeth regions along with increased probing pocket depth. Orthopantomogram of the jaws showed carious lesions in left lower posterior teeth along with periapical radiolucency and mild horizontal bone loss of posterior teeth [Fig.5].

The patient's blood reports were found to be within the normal range. As per the medical reports the patient was having phenytoin for last three years. The patient was referred back to the physician for possible substitution of the anti-convulsant drug. The patient was then undergone thorough oral prophylaxis regimen and was put under antibiotic prophylaxis, and chlorhexidine anti-microbial rinse to reduce the inflammation, microbial load and advised for further surgical therapy.

After obtaining proper consent both from the physician and the parents to undergo further surgical therapy, surgical excision of the fibrotic gingival tissues were done and the patient was then followed up to six months post-operatively [Fig.6] with no history recurrence. Patient was then advised for regular dental check-ups to reduce any further complications.

Discussion

Dyke-Davidoff-Masson syndrome (DDMS) is usually characterized by unilateral cerebral atrophy or hypoplasia

due to an insult to the developing brain in fetal or early childhood period.^[1-8] The patients are usually reported with facial asymmetry, seizures, learning difficulties, delayed milestones and contralateral hemiparesis.^[1-3,8] The underlying etiology is cerebral insult that may occur in prenatal, perinatal, or postnatal period. Prenatal causes include congenital abnormalities, cerebral infarction, vascular malformations, infections. Birth trauma, hypoxia, intracranial haemorrhage, tumors, infections, and prolonged febrile seizures after birth are also important peri- and post-natal causes.^[2-4] First description of it was in 1933, when Dyke, Davidoff and Masson described the plain skull radiographic and pneumato encephalographic changes in a series of nine patients.^[5] The clinical findings in DDMS may be of variable degree ranging from seizures, facial asymmetry, contralateral hemiplegia or hemiparesis, mental retardation, and rarely sensory symptoms and psychiatric disorders.^[1-6] The typical radiological features are cerebral hemi-atrophy with ipsilateral compensatory hypertrophy of the skull and sinuses.^[2-6] The syndrome had been documented mainly in adolescents and adults but also reported in children.^[2] MRI is a valuable method of examination in the analysis of cerebral hemi-atrophy.^[6,7]

In this present case the patient was presented to the department with the chief complaint of gum swelling and bleeding from gums. On examination, generalized gingival enlargements were observed in anterior teeth regions along with unilateral gingival swelling of left posterior teeth. Since, the patient was already having phenytoin for last a few years, the enlargements were not uncommon. But, the unilateral gingival enlargements were most probably due to effect of disuse atrophy of the left side of the jaw as an effect of contralateral hemiparesis, as being diagnosed with right sided cerebral hemi-atrophy.

The patient was advised for regular dental check-ups to reduce complications.

Conclusion

Dyke Davidoff Masson syndrome is a rare finding and might be a cause of unilateral drug –induced gingival enlargements in patients having anti-convulsants for controlling seizures. Therefore, proper medical history are essential to effectively manage these cases and further investigations, follow-ups are also necessary for these atypical cases.

References

1. Jilowa CS, Meena PS, Jain M, Sharma KK. Dyke-Davidoff-Masson syndrome: A rare case report. Med J DY Patil Univ 2016; 9:730-2.
2. Thakkar PA, Dave RH. Dyke–Davidoff–Masson syndrome: A rare cause of cerebral hemiatrophy in children. Journal of Pediatric Neurosciences. 2016;11(3):252-254.
3. Jain D, Aggarwal HK, Goyal S, Mittal A. Dyke–Davidoff–Masson syndrome: A rare case report. Iran J Neurol 2014; 13(4): 255-6.
4. Sharma S, Goyal I, Negi A, Sood RG, Jhobta A, Surya M, authors. Dyke-Davidoff-Masson Syndrome. Ind J Radiol Imag. 2006;16:165–6
5. Dyke CG, Davidoff LM, Masson LB. Cerebral hemiatrophy with homolateral hypertrophy of skull and sinus. Surg Gynecol Obstet.1933;57: 588 – 600.
6. Singh P, Saggarr K, Ahluwalia A. Dyke-Davidoff-Masson syndrome: Classical imaging findings. J Pediatr Neurosci 2010;5:124-5.
7. Kochar DK, Jain N, Sharma BV. Dyke-Davidoff-Masson syndrome-Neuroimage. Neurol India 2001;49:417-8.
8. Behera MR, Patnaik S, Mohanty AK. Dyke-Davidoff-Masson syndrome. J Neurosci Rural Pract 2012; 3(3): 411-3.

Legends Figure

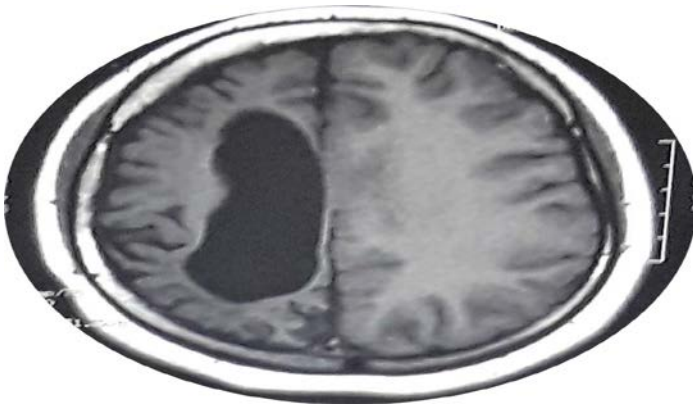


Fig.1: MRI of the patient revealed unilateral cerebral hemi-atrophy.

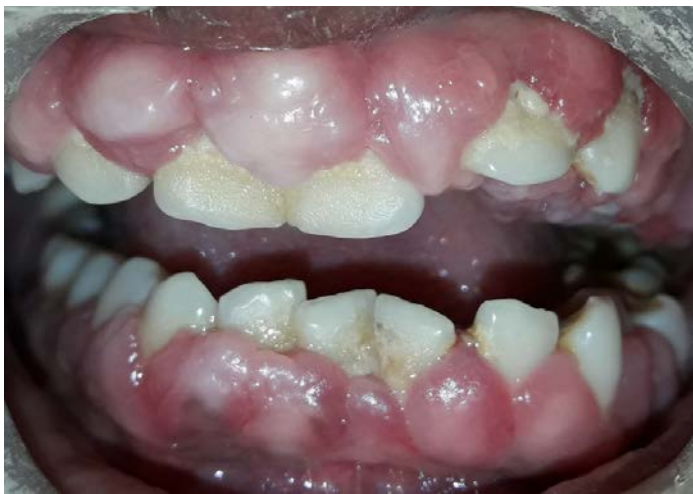

Fig. 2: Gingival enlargement noted on buccal aspect of upper and lower anterior teeth.

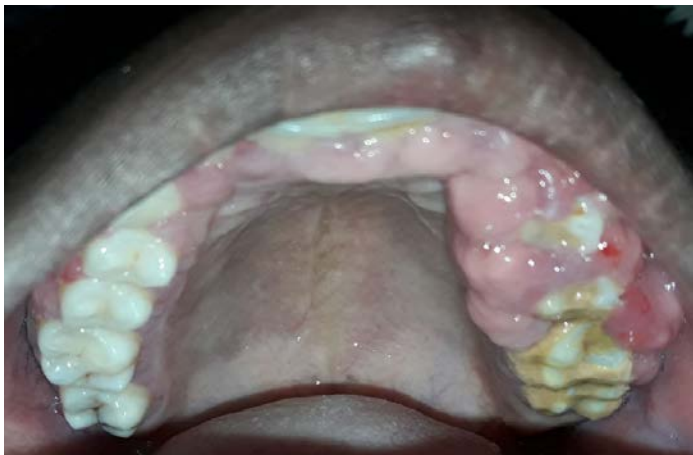

Fig.3: Unilateral gingival enlargement noted on left upper posterior teeth.

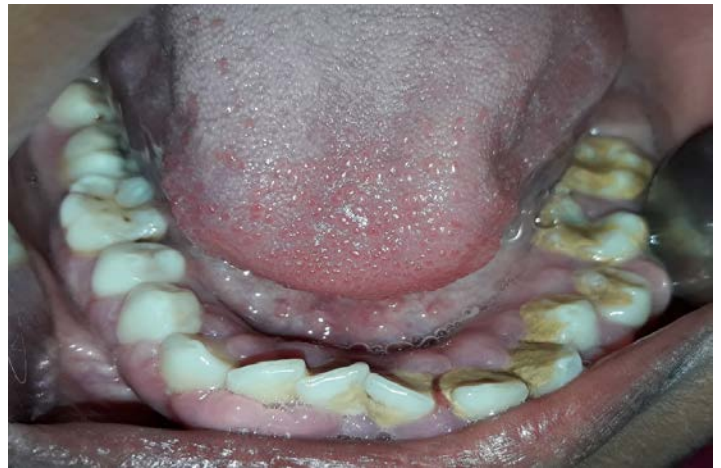

Fig.4: Unilateral gingival enlargement noted on left lower posterior teeth.

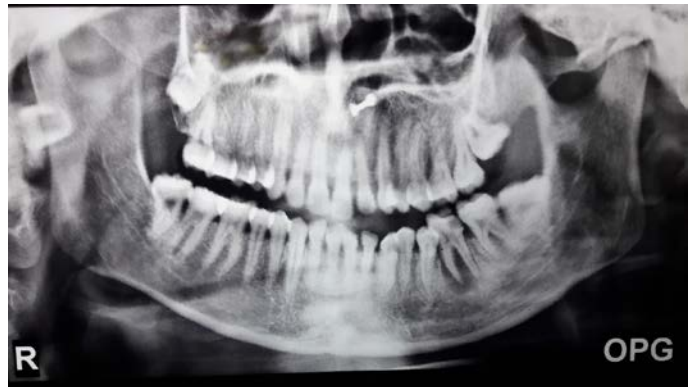

Fig.5: OPG of the jaws

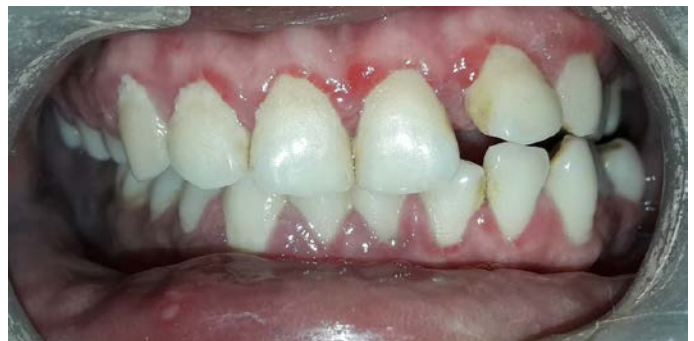

Fig.6: Post op intraoral view of the patient