

**Assessment of total alloplastic temporo-mandibular joint replacement (TMJR) with various prostheses: A comparative study**

<sup>1</sup>Dr. Davinderjit Kaur Shergill, Assistant prof. Department of Prosthodontics, Maharaja Ganga Singh Dental College and Research Centre, Sri Ganganagar.

<sup>2</sup>Dr. Ranjana Balla, Assistant prof. Department of Prosthodontics, Adesh Institute of Dental Sciences and Research, Bathinda.

<sup>3</sup>Dr. Anita Mehta, Professor, Department of Periodontology & Implantology, Dasmesh institute of Research & Dental Sciences Faridkot, Punjab, India.

<sup>4</sup>Dr. Nitin Khuller, Prof and HOD, Department of Periodontology & Implantology, Dasmesh institute of Research & Dental Sciences Faridkot, Punjab, India.

<sup>5</sup>Dr. Preetinder Singh, Professor, Department of Periodontology & Implantology, Swami Devi Dyal hospital and Dental College, Barwala, Panchkula, Haryana.

**Corresponding Author:** Dr. Anita Mehta, Professor, Department of Periodontology & Implantology, Dasmesh institute of Research & Dental Sciences Faridkot, Punjab, India.

**Citation of this Article:** Dr. Davinderjit Kaur Shergill, Dr. Ranjana Balla, Dr. Anita Mehta, Dr. Nitin Khuller, Dr. Preetinder Singh, “Assessment of total alloplastic temporo-mandibular joint replacement (TMJR) with various prostheses: A comparative study”, IJDSIR- March - 2020, Vol. – 3, Issue -2, P. No. 158 – 162.

**Copyright:** © 2020, Dr. Anita Mehta, et al. This is an open access journal and article distributed under the terms of the creative commons attribution noncommercial License. Which allows others to remix, tweak, and build upon the work non commercially, as long as appropriate credit is given and the new creations are licensed under the identical terms.

**Type of Publication:** Original Research Article

**Conflicts of Interest:** Nil

---

**Abstract**

**Background:** Certain TMJ conditions and pathology require reconstruction with a total joint prosthesis for predictable treatment outcomes. Hence; we planned the present study to assess patients undergoing total alloplastic temporo-mandibular joint replacement (TMJR) with various prostheses.

**Materials & methods:** The present study included assessment of patients undergoing total alloplastic temporo-mandibular joint replacement with various prostheses. For the manufacturing of the TMJR's

mandibular component, cobalt-chromium-molybdenum (Co-Cr-Mb) alloy was used. We carried out postoperative evaluation preoperatively, and at sixth month and twelfth month postoperatively. All the follow-up outcomes were recorded and analyzed by SPSS software. Visual analogue scale (VAS) and maximum jaw opening were used for clinical assessment of patients.

**Results:** A total of 30 subjects were included in the present study. Among these 30 subjects, 18 were males while the remaining were females. Mean age of the

patients of the present study was 42.5 years. We observed significant improvement in the pain level in patients during follow-up time. Similar results were obtained while assessing the maximum jaw opening.

**Conclusion:** The authors favour and advocate that surgical procedure involving the placement of TMJ prosthesis is efficacious and is associated with considerable advantages in comparison to other treatment options.

**Keywords:** Alloplastic, Replacement, Temporomandibular joint

### **Introduction**

Certain TMJ conditions and pathology require reconstruction with a total joint prosthesis for predictable treatment outcomes.<sup>1, 2</sup> Some of these conditions include  $\geq 2$  previous TMJ surgeries; previous TMJ alloplastic implants containing Proplast/ Teflon (PT), Silastic, acrylic, or bone cements; inflammatory or resorptive TMJ pathology; connective tissue or autoimmune disease (i.e., rheumatoid arthritis, psoriatic arthritis, scleroderma, Sjögren's syndrome, lupus, and ankylosing spondylitis); fibrous or bony ankylosis; absence of TMJ structures due to pathology, trauma, or congenital deformity; and tumors involving the condyle and mandibular ramus area.<sup>3-5</sup>

With stainless steel implant of glenoid fossa attempted for the correction of ankylosis in the 1960s, total temporomandibular joint (TMJ) replacement--which minimizes foreign body reaction and consists of highly biocompatible materials such as Cr-Co-Mo alloy, titanium, and ultra-high-molecular-weight polyethylene--began to be applied.<sup>6</sup>

Hence; we planned the present study to assess patients undergoing total alloplastic temporomandibular joint replacement (TMJR) with various prostheses.

### **Materials & methods**

The present study was conducted in the department of prosthodontics of Maharaja Ganga Singh Dental College and Research Centre, Sriganganagar and it included assessment of patients undergoing total alloplastic temporomandibular joint replacement with various prostheses. Inclusion criteria for the present study included:

- Patients scheduled to undergo Cranio-Mandibular Joint Replacement,
- Patients who gave informed written consent for the study,
- Patients in which replacement of the skull base component (glenoid fossa) and the mandibular condyle

For the manufacturing of the TMJR's mandibular component, cobalt-chromium-molybdenum (Co-Cr-Mb) alloy was used. Implantation of all the parts of the prosthesis was done under general anaesthesia. Intraoperative use of templates was done for determination of the fitting of the prosthesis, followed by final insertion of the prosthesis. 6Al/4V titanium alloy screws were used in the present study. In case of custom-made trays, it was unnecessary to use the templates. We carried out postoperative evaluation preoperatively, and at sixth month and twelfth month postoperatively. All the follow-up outcomes were recorded and analyzed by SPSS software. Visual analogue scale (VAS) was used for assessment of pain. We also recorded maximum jaw opening at various time intervals. Univariate regression curve was used for assessment of level of significance.

### **Results**

A total of 30 subjects were included in the present study. Among these 30 subjects, 18 were males while the remaining were females.

Mean age of the patients of the present study was 42.5 years. Mean Pain value as measured by VAS at preoperative, 6 months postoperative and 12 months postoperative was found to be 6.98, 2.52 and 1.42 cm respectively. We observed significant improvement in the pain level in patients during follow-up time. Similar results were obtained while assessing the maximum jaw opening. Mean preoperative jaw opening was found to be 2.82 while mean jaw opening at 6 months postoperative and at 12 months postoperative was found to be 3.98 and 4.23 cm respectively. Significant results were obtained while comparing the maximum jaw opening in between the subjects at different time intervals.

### **Discussion**

Although the longevity of the TMJ Concepts total joint prosthesis is yet unknown, clinical experience over the past 10 years shows promising long-term results. Based on material selection and treatment philosophy, it is believed that these devices will provide service life comparable with or longer than that of hip stem devices.<sup>7-9</sup> Mean Pain value as measured by VAS at preoperative, 6 months postoperative and 12 months postoperative was found to be 6.98, 2.52 and 1.42 cm respectively. We observed significant improvement in the pain level in patients during follow-up time. Similar results were obtained while assessing the maximum jaw opening. Mean preoperative jaw opening was found to be 2.82 while mean jaw opening at 6 months postoperative and at 12 months postoperative was found to be 3.98 and 4.23 cm respectively. Significant results were obtained while comparing the maximum jaw opening in between the subjects at different time intervals. Sanovich R et al reported the subjective and objective outcomes of temporomandibular joint (TMJ) replacement with Biomet stock prostheses at a single institution in Florida.

In this retrospective study, patients who underwent TMJ replacement using a Biomet stock prosthesis from 2005 to 2012 were analyzed. Subjective (pain, diet) and objective (maximal incisal opening) information was obtained. In addition, a quality of life measure was obtained pre- and postoperatively. Significance was set at  $<0.01$ . Thirty-six patients (26 bilateral, 6 left, and 4 right) who underwent TMJ replacement using a Biomet stock prosthesis were eligible for the study. Maximal incisal opening improved from 26.1mm preoperatively to a mean of 34.4mm postoperatively. The pain score decreased from 7.9 preoperatively to a mean of 3.8 postoperatively. Diet restriction decreased from 6.8 preoperatively to a mean of 3.5 postoperatively. Quality of life improved from a median of 4 preoperatively to a postoperative median of 2. Four implants were removed/replaced because of heterotopic bone formation, infection, and/or loose hardware. Follow-up ranged from 6 to 83 months. Overall, TMJ reconstruction using the Biomet stock joint is effective and safe in this patient population.<sup>10</sup>

Machon V et al presented initial subjective and objective data compiled between 2005 and 2009 from those cases. Data were collected from 27 patients (38 joints) reconstructed with the Biomet-Lorenz stock and custom TMJ prostheses during a mean follow-up period of 24 months. The variables of pain and mouth opening were evaluated pre- and postoperatively. Patients classified pain on a scale of 0-5 (none - unbearable). The extent of opening was investigated by a physician (the distance between the points of the incisors on the upper and lower jaw was measured). The most common indication for replacement was ankylosis. There was an improvement in pain score in 15 patients. 4 patients reported worsening of pain and 8 patients did not complain of pre- or postoperative pain.

Mandibular opening increased from a mean of 17.7 mm preoperatively to a mean of 29.1mm postoperatively. There were complications related to the surgery, but no significant complications related to the devices. Total alloplastic TMJ replacement appears to be a safe and effective method of reconstruction in the patients in this initial study.<sup>11</sup> Gonzalez-Perez LM et al investigated outcomes achieved with a stock temporomandibular joint (TMJ) replacement system in the management of end-stage TMJ disorders. Fifty-two patients requiring reconstruction (36 unilateral/16 bilateral) were operated on during the period 2006-2012; 68 total prostheses were implanted (Biomet Microfixation TMJ Replacement System). The mean age at surgery was 52.6±11.5 years. Changes in the values of inclusion diagnostic criteria at entry were assessed. These included persistent and significant TMJ pain, functional impairment after failure of other surgical therapies, and imaging evidence consistent with advanced TMJ disease of more than 1-year duration. Subjects were excluded if they presented insufficient quantity/quality of bone to support the TMJ replacement, severe hyperfunctional habits, active infectious disease, or an inability to follow postoperative instructions. Over the 2 years of postoperative follow-up, mean pain intensity was reduced from 6.4±1.4 to 1.6±1.2 (P<0.001), and jaw opening was improved from 2.7±0.9cm to 4.2±0.7cm (P<0.001). During the study period, three of 68 implants (4%) were explanted and new TMJ replacements fitted. The results of this study supported the view that the surgical placement of stock TMJ prostheses provides significant long-term improvements in pain and function, with few complications.<sup>12</sup>

## Conclusion

Under the light of above results, the authors favour and advocate that surgical procedure involving the placement of TMJ prosthesis is efficacious and is associated with considerable advantages in comparison to other treatment options. However; further studies are recommended.

## References

1. Driemel O, Braun S, Müller-Richter UD, Behr M, Reichert TE, Kunkel M, et al. Historical development of alloplastic temporomandibular joint replacement after 1945 and state of the art. *Int J Oral Maxillofac Surg.* 2009;38:909–920.
2. Westermark A, Leiggener C, Aagaard E, Lindskog S. Histological findings in soft tissues around temporomandibular joint prostheses after up to eight years of function. *Int J Oral Maxillofac Surg.* 2011;40:18–25.
3. Guarda-Nardini L, Manfredini D, Ferronato G. Total temporomandibular joint replacement: a clinical case with a proposal for post-surgical rehabilitation. *J Craniomaxillofac Surg.* 2008;36:403–409.
4. Mercuri LG. Alloplastic temporomandibular joint reconstruction. *Oral Surg Oral Med Oral Pathol Oral RadiolEndod.* 1998;85:631–637.
5. Voiner J, Yu J, Deitrich P, Chafin C, Giannakopoulos H. Analysis of mandibular motion following unilateral and bilateral alloplastic TMJ reconstruction. *Int J Oral Maxillofac Surg.* 2011;40:569–571.
6. Henry CH, Wolford LM. Treatment outcomes for temporomandibular joint reconstruction after Proplast-Teflon implant failure. *J Oral Maxillofac Surg.* 1993;51:352–358.

7. Mosby EL, Wagner JD, Robinson RC. Assessment of Teflon-Proplast implants in temporomandibular joint reconstruction following meniscectomy. J Oral Maxillofac Surg. 1986;44(Suppl):13.
8. Granquist EJ, Chou JC, Giannakopoulos H, Livolsi VA, Quinn PD. Post-surgical neuromas in patients with total alloplastic temporomandibular joint reconstruction: a retrospective case series. Int J Oral Maxillofac Surg. 2011;40:366–371.
9. Wolford LM, Karras SC. Autologous fat transplantation around temporomandibular joint total joint prostheses: preliminary treatment outcomes. J Oral Maxillofac Surg. 1997;55:245–251
10. Sanovich R1, Mehta U2, Abramowicz S3, Widmer C4, Dolwick MF5. Total alloplastic temporomandibular joint reconstruction using Biomet stock prostheses: the University of Florida experience. Int J Oral Maxillofac Surg. 2014 Sep;43(9):1091-5.
11. Machon V1, Hirjak D, Beno M, Foltan R. Total alloplastic temporomandibular joint replacement: the Czech-Slovak initial experience. Int J Oral Maxillofac Surg. 2012 Apr;41(4):514-7.
12. Gonzalez-Perez LM1, Fakh-Gomez N2, Gonzalez-Perez-Somarriba B3, Centeno G3, Montes-Carmona JF2. Two-year prospective study of outcomes following total temporomandibular joint replacement. Int J Oral Maxillofac Surg. 2016 Jan;45(1):78-84. doi: 10.1016/j.ijom.2015.08.992. Epub 2015 Sep 14.

**Legends Table and Figure**

Table 1: Demographic details

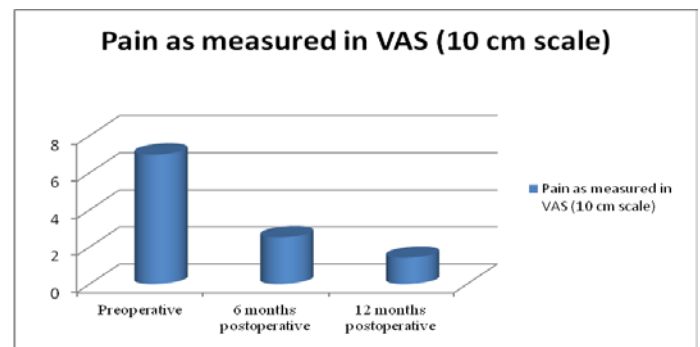
Parameter		Value
Mean age (years)		42.5
Gender	Males	18
	Females	12
Total		30

Table 2: Evaluation of outcome measures

Time period	Pain as measured in VAS (10 cm scale)	P-value	Maximum jaw opening (cm)	P-value
Preoperative	6.98	0.002*	2.82	0.003*
6 months postoperative	2.52		3.98	
12 months postoperative	1.42		4.23	

\*: Significant

Graph 1: Measurement of pain level at different time interval



Graph 2: Measurement of maximum jaw opening at different time interval

