

## **Multidisciplinary Approach to Restore Broken Anterior Teeth with Zirconia Crowns - A Case Report**

Dr.Rahul Patil, Department of Prosthodontics, Ras Al Khaimah Specialised, Dental Center, Ministry of Health and Prevention, UAE

**Corresponding Author:** Dr.Rahul Patil, Department of Prosthodontics, Ras Al Khaimah Specialised Dental Center, Ministry of Health and Prevention, UAE

**Citation of this Article:** Dr.Rahul Patil,“ Multidisciplinary Approach to Restore Broken Anterior Teeth with Zirconia Crowns - A Case Report”, IJDSIR- February - 2020, Vol. – 3, Issue -1, P. No. 230 – 235.

**Copyright:** © 2020, Dr.Rahul Patil, et al. This is an open access journal and article distributed under the terms of the creative commons attribution noncommercial License. Which allows others to remix, tweak, and build upon the work non commercially, as long as appropriate credit is given and the new creations are licensed under the identical terms.

**Type of Publication:** Case Report

**Conflicts of Interest:** Nil

### **Abstract**

Due to an increasing interest in aesthetics and concerns about toxic and allergic reactions to certain alloys, zirconia was proposed as a new ceramic material in the later part of 20th century. It has become a popular alternative to alumina as biomaterial and is being used in dental applications for fabricating endodontic posts, crown and bridge restorations and implant abutments. This article presents a brief history, methods for fabrication of zirconia, its mechanical properties and advantages of using it in endodontically treated anterior teeth. Additionally, crown lengthening and biologic width along with some aspects and basis of smile design philosophy are discussed. The methods of the improvement of aesthetics with zirconia have also been highlighted. A similar case report including all aspects of restorative dentistry is discussed in detail.

**Keywords:** Trans-gingival Probing (TP),Cemento-enamel Junction (CEJ),Bone Crest(BC), Gingivectomy, Zirconia.

**Introduction:** A smile is a facial expression that is closely related to the emotions and psychological state of a person. It is evident that each smile is Different and particular to each individual. An impaired smile on the other hand, has been associated with higher incidences of depression. Aesthetics deals with objective and subjective beauty. Smile aesthetics is multifactorial which needs to be adequately addressed for any aesthetic treatment. The objective beauty of a smile can be established with the application of various principles of smile design, and the creation of subjective beauty may enhance cosmetic value. Aesthetic restorative treatment is based on the patient's chief complaints such as Poor crowns or bridges, Exposed Roots, Dark/Pigmented Gingiva, Black holes between teeth, Gummy smile or uneven gum line. Out of the various restorative materials, Zirconium oxide restorative materials got their start as tooth-coloured replacements for traditional full-gold crowns on posterior teeth. However, early zirconia materials were very opaque and only indicated for first or second molars. Because zirconia is a metallic oxide (zirconium oxide), it can be used like a

PFM crown to cover dark tooth preparations like for non-vital teeth, and it can also be cemented with a conventional (non-adhesive) cement. Since there are certain clinical indications where zirconia might be a desirable choice for use in the aesthetic zone, the challenge has been to provide the necessary aesthetic characteristics that are required for anterior restorations.<sup>[1]</sup> Zirconia restorations are mainly fabricated by two techniques- Layered and Monolithic. The challenge that the clinician and laboratory technician face with the advent of CAD/CAM-fabricated ceramic cores is finding a porcelain material that can reproduce the aesthetics found in the all-ceramic restorations without ceramic cores. Ceramic restorations from CAD/CAM machines tend to be very bright, white, high-value, opaque materials. The traditional method of layering porcelain tends to produce high-value and low-translucency restorations, which when placed adjacent to human dentition have a less-than-desirable outcome; the lack of translucency serves as the most important challenge of these new ceramic frameworks. A case which was managed by layered zirconia crowns is discussed in detail in the report.

### **Case Report**

A. Chief Complaint-A 26yr old female patient reports to clinic expressing concern about broken fixed prosthesis in her mouth. She was hesitant to give a broad smile since few months due to unaesthetic upper front teeth. Patient had no relevant medical history. Dental history revealed that patient had done previous restorations and crown placements for carious teeth.

B. Intraoral Examination -After intraoral examination it was analysed that patient had metal with acrylic facing bridge on maxillary incisors 12-22 which was placed before 5-6 years (fig.1). Currently the prosthesis was stained, broken and perforated. Patient also had an issue with more visibility of her gums during smile

(fig.2). Radiographic examination showed that teeth 12-22 were not treated endodontically before placement of bridge. Patient desired replacement of this broken bridge and an aesthetic smile.

C. Treatment Plan-Clinical photos were taken and diagnostic impressions were made. Proposed treatment plan after understanding patients concern was to replace old broken prosthesis on 12-22 with new crowns along with correction of gummy smile. Before removal of broken prosthesis, patient desired some immediate provisional prosthesis till the final prosthesis was made. Diagnostic wax up was done on the primary cast till the present crown margin to fabricate immediate provisional acrylic prosthesis (fig.3). Gingivoplasty or aesthetic crown lengthening was planned to reduce the gummy smile and to provide adequate crown structure to receive aesthetic crowns. Old prosthesis was cut and removed taking care of underlying tooth. After removal of previous prosthesis, teeth were analysed for restorability and vitality was checked using cold test. Teeth were vital but with very limited dentin over the pulp chamber and less remaining tooth structure to receive crowns. Acrylic Provisional prosthesis was made using putty index of wax up and luted provisionally. Elective Endo treatment was done for all four teeth 12 -22 as very limited dentin present over the pulp chamber. Post and core built up was done after endo treatment using resin post and composite built for 12 and 22. As the teeth were treated endodontically, a restoration which was opaque was desired. So it was planned to use zirconia crown 6restorations. Composite filling was done after removal of decay mesial to 13. The amount of gingival display was marked during patient smile along with lip line. The teeth 12-22 were seen to be passively erupted. Amount of attached gingiva was measured in 12-22 region with WHO probe and Trans-gingival Probing (TP) Method (fig.4). Around 3.5-4mm of attached gingiva

was present. As per Ernesto classification, Type I aesthetic crown lengthening surgery was performed and around 1.5mm of the gingival tissue was removed in 12-22 region and gingival zenith was shifted more apically (fig.5). Periodontal dressing was applied after gum surgery and previously made provisional prosthesis using the index was placed initially for a day but later it was relined till the new gingival margin and luted for around 2 weeks till the gingival healing was complete (fig.6). After complete healing of soft tissues, teeth 12,11,21,22 were prepared to receive zirconia crowns and margins were moved apically till the new gingival margin which was achieved after surgery (fig.7). Gingival retraction was done and final impression was made using silicone impression material. Shade selection was done. Patient was re-called after a week and coping trial for CAD-CAM fabricated zirconia copings was done to check fit, occlusal clearance and margin adaptation (fig.8). Copings were later layered with ceramic (fig.9) and Bisque trial for the final zircon crowns was done and necessary adjustments were made. Anterior guidance was established and Proper centric stops were achieved (fig.10). Final crowns were glazed and checked for aesthetics. Teeth and crowns were surface treated and luted using self-adhesive resin cement. Patient was satisfied and overwhelmed with her new smile (fig.11). Care and hygiene instructions were given to the patient. Periodic follow ups were done for the patient.

#### Steps of Luting Zirconia Crown

- Crowns were sandblasted with aluminium oxide after final try in
- Cleaned with alcohol and air dry with oil free air
- Prepared teeth were cleaned with pumice paste
- Self-adhesive resin cement was directly dispensed in the crowns
- Crown was seated firmly one time each

Excess cement removed and instructions given to patient.

**Discussion:** Zirconia-based all-ceramic restorations provide a better alternative to metal-based restorations for endodontically treated tooth due to its excellent clinical performance by virtue of its highly aesthetic nature, superior mechanical properties, and compatibility with the oral tissues. Properties that make zirconia the material of choice for fabrication of crowns in fixed partial prosthesis are the aesthetic nature, high mechanical strength (Resistance to traction = 900 – 1200 MPa; Compression resistance = 2000 MPa), toughness, corrosion resistance, resistance to altering temperatures and excellent compatibility.<sup>[2]</sup> Structurally, Zirconia is organized in three different patterns: monoclinic (M), tetragonal (T), and cubic (C). The addition of Yttrium to zirconia is meant to stabilize the transformation of the crystalline structure under the conditions of increased temperature and also to improve the physical properties of zirconium. While the first integral ceramic dental restorations were limited to single-tooth restorations or small bridges, these zirconia structures may be used in larger prosthesis both in the anterior or posterior regions. All of which added to classical uses like posts and cores or more recently as a material for dental implants. Dental prosthetic restorations made from zirconia may be obtained using the CAD-CAM technology with two possible methods-

- In first technique the prosthetic restorations are milled from zirconia blocks already sintered which means there is no shrinkage to the final structure
- In second method the zirconia prosthesis is milled from a block replicating the form of the final prosthesis but with bigger dimensions so it compensates for the shrinkage that occurs after sintering.
- In order to achieve an aesthetic appearance of the zirconia ceramic restoration a multilayer covering

technique is used for veneering zirconia framework with compatible ceramics.<sup>[3]</sup>

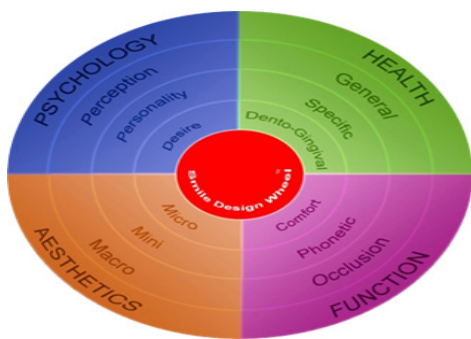

Figure 1 : The Smile Design Wheel For any smile design procedure, the clinician needs to consider the elements of the smile design—Psychology, Health, Function And Aesthetics [4]

A careful diagnosis and treatment plan are essential to reach to the most predictable treatment outcome for such cases. The most common diagnostic method for assessing periodontal tissues is Trans gingival Probing (TP), which is used to detect the CEJ that is sub gingival and to calculate the real clinical crown dimension. The soft tissue height is measured with a periodontal probe down to the Bone Crest (BC), and this dimension can also be used to guide the amount of tissue resection to be achieved.<sup>[5]</sup>

A. **Biologic Width:** The concept of the biologic width was first originated by research conducted by Gargiulo, Wentz, and Orban where the distance between the apical end of the gingival sulcus and the crest of the alveolar bone was measured on several cadaver specimens. In areas that present with periodontal health, that distance, now regarded as the biologic width, was reported to be an average of 2.04 mm, where approximately 0.97 mm is occupied by the junctional epithelium and 1.07 mm is occupied by connective tissue attachment to the root surface.<sup>[6]</sup> The physiologic location of the biologic width can vary with age, tooth migration due to loss of arch or occlusal integrity, or orthodontic treatment. *Violation* of the biologic width is a common

occurrence in the practice of restorative dentistry. A familiar clinical situation in which the biologic width can be violated is by the placement of a deep sub gingival restoration. The need to establish a sub gingival restorative margin can be dictated by caries, tooth fracture, external root resorption, or the need to increase axial height of a tooth preparation for retention purposes. If the apical margin of the restorative preparation is placed within the biologic width (i.e., too close to the bone), a zone of chronic inflammation is likely to develop.<sup>[7]</sup> One of the theories proposed is that there is insufficient space for a “normal” length of junctional epithelium to develop; the junctional epithelium is short, weak, and does not exert an effective sealing effect of the dento-gingival unit. Moreover, the area is easily damaged by mechanical oral hygiene practices, and chronic inflammation persists or is easily induced. Others believe a deeply placed sub gingival restorative margin, close to the alveolar bone crest, impairs proper plaque control promoting inflammatory changes not conducive to a healthy periodontal environment.<sup>[8]</sup>

**B. Crown Lengthening**<sup>[9]</sup>

Indications	Contra-Indications
Restorative needs –short teeth	Inadequate crown to root ratio
To increase clinical crown height lost due to caries, fracture or wear	Non restorability of caries or root fracture
To access sub-gingival caries	Aesthetic compromise
To produce a ferrule for restoration	High furcation and poor hygiene
To access a perforation in the coronal third of the root	Inadequate predictability
Excessive gingival display/Gummy smile	Tooth arch relationship inadequacy
To relocate margins of restorations that is impinging on biological width.	Compromised adjacent periodontium or aesthetics

**Pre-surgical Analysis for crown lengthening**<sup>[10]</sup>

Smukler and Chibi (1997) recommended following pre-surgical clinical analysis prior to crown lengthening procedures:

- Determine the finish line prior to surgery
- If non determinable, it should be anticipated
- Trans-crevicular / Trans-gingival circumferential probing prior to surgery is performed for establishing the biologic width (Bone Sounding)
- The biologic width requirements will determine the amount of alveolar bone removal amount of tooth structure necessary for exposure
- Tooth structure topography, anatomy, and curvature are analysed for determining the osseous scallop and gingival form.

The combination of biologic width and prosthetic requirements determines the total

Soft Tissue Assessment	Hard Tissue Assessment
Situation 1- If width of attached gingiva adequate (>3mm)- external bevel Gingivectomy or internal bevel Gingivectomy	Situation 1- If bone crest is low i.e. more apically – no Ostectomy
Situation 2- If width of attached gingiva inadequate (<3mm)- apically positioned flap	Situation 2- If bone crest is high i.e. more coronal- Ostectomy performed.

### Classification of Aesthetic Crown Lengthening by ERNESTO <sup>[11]</sup>

Proposed Classification System for Aesthetic Crown Lengthening Procedures			
Classification	Characteristics	Advantages	Disadvantages
Type I	Sufficient soft tissue allows gingival exposure of the alveolar crest or violation of the biologic width.	May be performed by the restorative dentist. Provisional restorations of the desired length may be placed immediately.	
Type II	Sufficient soft tissue allows gingival excision without exposure of the alveolar crest but in violation of the biologic width.	Will tolerate a temporary violation of the biologic width. Allows staging of the gingivectomy and osseous contouring procedures. Provisional restorations of the desired length may be placed immediately.	Requires osseous contouring. May require a surgical referral.
Type III	Gingival excision to the desired clinical crown length will expose the alveolar crest.	Staging of the procedures and alternative treatment sequence may minimize display of exposed subgingival structures. Provisional restorations of desired length may be placed at second-stage gingivectomy.	Requires osseous contouring. May require a surgical referral. Limited flexibility.
Type IV	Gingival excision will result in inadequate band of attached gingiva.		Limited surgical options. No flexibility. A staged approach is not advantageous. May require a surgical referral.

**Conclusion:** Zirconia-based all-ceramic restorations are reliable suggestive alternatives to metal-based restorations due to its superior mechanical and biological properties.

**Clinical Significance:** The performance of zirconia-based systems depends on a number of factors such as selection

of patient cases, clinician’s knowledge and skill and adherence to technological protocols, which when coupled together results in a successful treatment outcome. Further research to overcome the shortcomings of this zirconia-based material and long term evaluation of the same is recommended to ensure a perfect treatment option for patient seeking oral health care.

### References

1. Chevalier J. What future for zirconia as a biomaterial? .Biomaterials 2006; 27(4):535–43. 10.
2. Current status of zirconia restoration. J Prosthodont Res 2013; 5(4): 236–61.
3. Piconi C, Maccauro G. Zirconia as a ceramic biomaterial: a review. Biomaterials 1999; 20: 1-25
4. Dr Sushil Koirala, Nepal. A practical approach to smile design.Cosmetic Dentistry 2009;3 (4)
5. Greenberg J, Laster L, Listgarten MA. Transgingival probing as a potential estimator of alveolar bone level. J Periodontol 1976; 47: 514–517.
6. Kois J. The restorative-periodontal interface: biological parameters. 1996;11:29-38
7. Gunay H, Seeger A. Placement of the preparation line and periodontal health- a prospective two-year clinical study. Int J Periodontics Restorative Dent 2000; 20:171-81.
8. Holmes JR, Sulik WD.Marginal fit of castable ceramic crown. J Prosthet Dent 1992; 67:594-9
9. Camargo PM, Melnick PR, Camargo LM. Clinical Crown Lengthening in Esthetic Zone. C D A Journal 2007;35 (7):487- 498
10. Smukler H, Chaibi M. Periodontal and dental considerations in clinical crown extension. A rational basis for treatment. Int J Periodontics Restorative Dent 1997; 17:464-77
11. Ernesto A. Lee, Cir Dent. Aesthetic Crown Lengthening: Classification, Biologic Rationale, And

Treatment Planning Consideration .Pract Proced  
Aesthet Dent 2004; 16 (10): 769- 778

**Legends Figures**

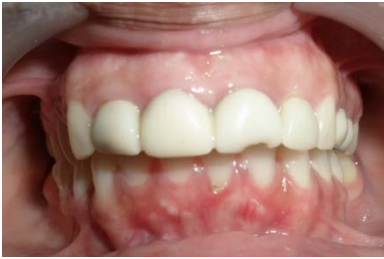

Fig.1:Pre Operative – Frontal View

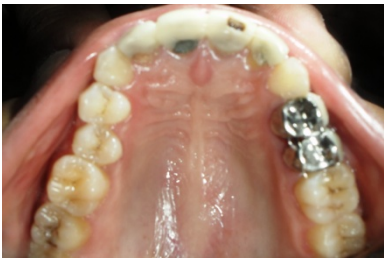

Fig.2: Occlusal View-Maxillary Arch

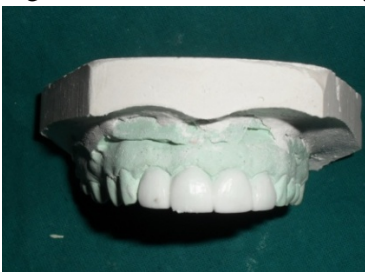

Fig.3: Wax Up 12-22

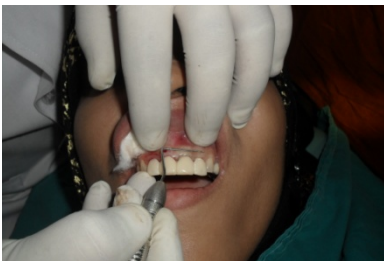


Fig.4: Marking Gingival Tissue Length For Aesthetic Crown Lengthening 12-22 After Placement of Provisionals

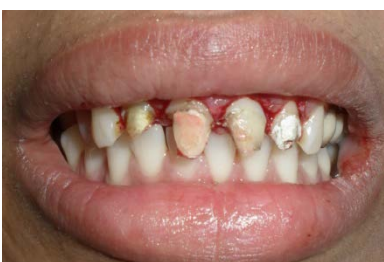

Fig.5: Amount of Tooth Exposed Post Crown Lengthening 12-22

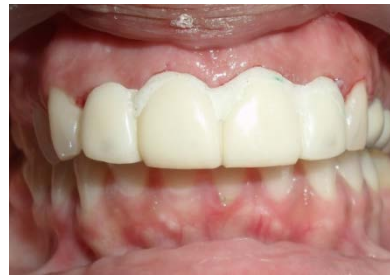

Fig. 6: Relined Provisional Prosthesis

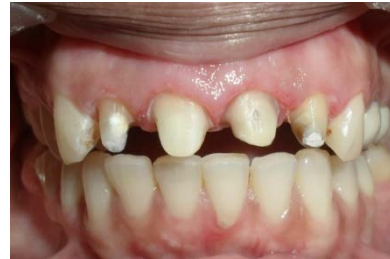

Fig.7: Tooth Preparation 12-22 up to new gingival margin

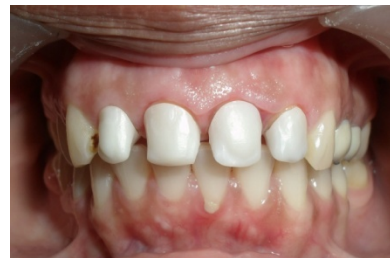

Fig.8: Zirconia Coping Trial for Crowns 12-22

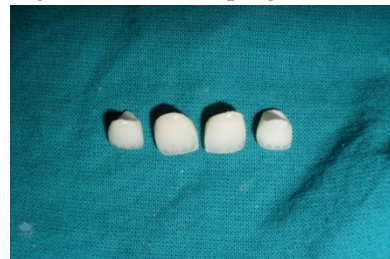

Fig 9: Layered Zirconia Crowns

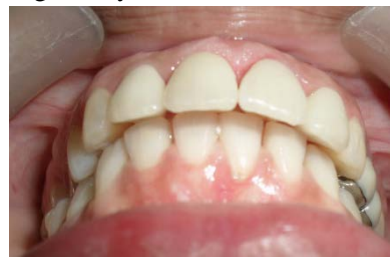

Fig 10: Proper Centric Stops

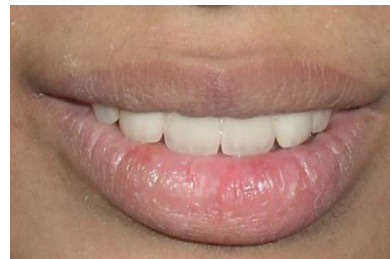

Fig. 11: Final Luted Crowns With New Smile