

**Bilateral Radix Entomolaris in a Fourteen Year Old Male: A Clinical Case Report**

<sup>1</sup>Dr Vinay Thakur, Reader, Department Of Pedodontics and Preventive Dentistry, Himachal Dental College, Sundernagar (H.P), 175019

<sup>2</sup>Dr Karan Thakur, PG Student, Department of Pedodontics and Preventive Dentistry, Himachal Dental College, Sundernagar (H.P), 175019

<sup>3</sup>Dr Vasundhara Pathania, Reader, Department of Pedodontics and Preventive Dentistry, Himachal Dental College, Sundernagar (H.P), 175019.

<sup>4</sup>Dr Diksha Sharma, PG Student, Department of Pedodontics and Preventive Dentistry, Himachal Dental College, Sundernagar (H.P), 175019.

<sup>5</sup>Dr Munnasha Uppal, PG Student, Department of Pedodontics and Preventive Dentistry, Himachal Dental College, Sundernagar (H.P), 175019.

**Corresponding Author:** Dr Karan Thakur, PG Student, Department of Pedodontics and Preventive Dentistry, Himachal Dental College, Sundernagar (H.P), 175019

**Citation of this Article:** Dr Vinay Thakur, Dr Karan Thakur, Dr Vasundhara Pathania, Dr Diksha Sharma, Dr Munnasha Uppal, “Bilateral Radix Entomolaris in a Fourteen Year Old Male: A Clinical Case Report”, IJDSIR- February - 2020, Vol. – 3, Issue -1, P. No. 17 – 20.

**Copyright:** © 2020, Dr Karan Thakur, et al. This is an open access journal and article distributed under the terms of the creative commons attribution noncommercial License. Which allows others to remix, tweak, and build upon the work non commercially, as long as appropriate credit is given and the new creations are licensed under the identical terms.

**Type of Publication:** Case Report

**Conflicts of Interest:** Nil

**Abstract**

A comprehensive knowledge of the anatomy of the root canal is basic prerequisite for the success of endodontic treatment Mandibular molars may have an additional root located lingually (radix entomolaris) or buccally (radix paramolaris). An awareness of potential for understanding of unusual external and internal root canal morphology contributes to the successful outcome of root canal treatment. Here, we report a case of bilateral radix entomolaris to increase awareness and understanding of this unusual morphology so that procedural errors during endodontic therapy might better be avoided.

**Keywords:** Anatomical Variation- Mandibular Molar- Radix Entomolaris- Radix Paramolaris

**Introduction**

A thorough knowledge of dental anatomy and in depth understanding of potential for variation from the norm are required to achieve success in endodontic therapy. Missed canals, incomplete instrumentation, cleaning of the root canal space, and faulty obturation are main reasons for failure of endodontic treatment<sup>1</sup>.

It is known that mandibular first molar can display several anatomical variations. Majority of Caucasian first molars are two rooted with two mesial and one distal canal. In

most cases mesial root has two canals, ending in two distinct apical foramina. Sometimes these merge at tip to end in one foramen. Distal root has one kidney shaped root canal, If canal is narrow and round second distal canal may be present. A number of anatomical variations has been described in mandibular first molar; Fabracampos and Bond reported presence of three mesial canals and Stroner noted three distal canals. Like number of root canals, number of roots may also vary. An additional third root. First mentioned in literature by Carabelli is called radix entomolaris. This is located distolingually in mandibular molars. An additional root at mesiobuccal side is called radix paramolaris.<sup>2</sup>

In European, African, Eurasian and Indian population it has been reported that separate RE is present in mandibular first molar with frequency of <5%, while in population with Mongoloid traits RE occurs with frequency between 5% and 40%.<sup>3</sup>

Knowledge of both normal and abnormal anatomy of the molars dictates the parameters for execution of root canal therapy and can directly affect the probability of success<sup>4</sup>.

Thus present case report demonstrates the prevalence, morphology, canal configuration and endodontic treatment of bilateral radix entomolaris.

### **Case Report**

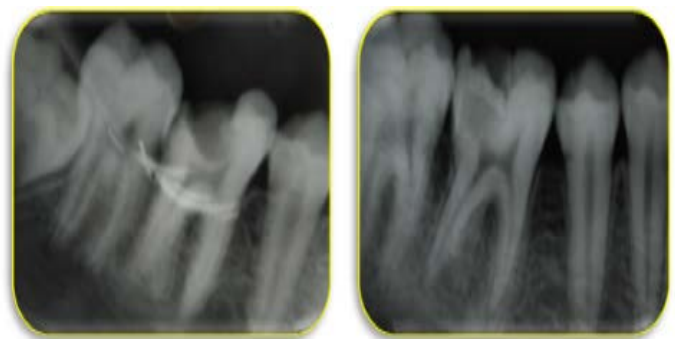
A 14 years old male patient accompanied by his father reported to the Department of Pedodontics And Preventive Dentistry, Himachal Dental college Sundernagar, Himachal Pradesh with a chief complaint of pain in right and left lower back region of jaw over a period of one month. Patient described a history of intermittent pain which was aggravated by hot food and sometimes persisted, even after removal of stimulus. Tooth was not mobile and EPT gave premature response. Preoperative IOPA #36, #46 revealed distal coronal deficit with radiolucency involving distal pulp horn. Three roots were

also revealed in IOPA. Based on the clinical findings tooth was diagnosed with caries with symptomatic irreversible pulpitis wrt #36, #46.

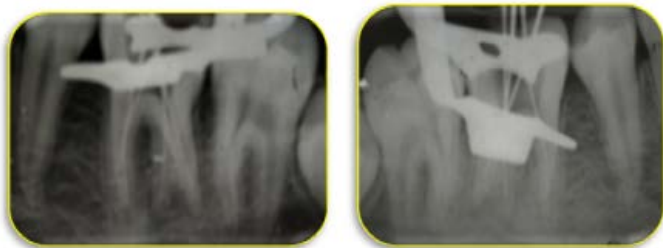Local Anesthesia was administered (2% Lidocaine with 100000 epinephrine) and tooth was isolated with rubber dam. Access was established with Endo access bur No.1, distal canal was located slightly off centre buccally, indicating canal would be in lingual side. Access cavity was modified to trapezoidal shape. Close inspection of pulp chamber revealed 2 mesial 2 distal canal orifices. Presence of all canals was confirmed with Endodontic explorer (DG16). Patency was established with No 10 K file. Working length was determined radiographically. Cleaning and Shaping was done with rotary NiTi protaper (gold), the orifices and coronal part were prepared with S<sub>x</sub>,S<sub>1</sub>,S<sub>2</sub> files and apical portion of canals were prepared with F<sub>1</sub> and F<sub>2</sub> files in crown down manner with 5.25% of NaOCl, 15% EDTA (RC Prep). Finding of separate DL canal orifice and outline of root in subsequent radiograph indicated presence of radix entomolaris wrt #36, #46.

GP Master cones were selected (protaper). Canals were dried with paper points and obturated using F<sub>2</sub> protapers and AH plus sealer. Access cavity was restored with silver amalgam and stainless steel crowns were delivered after two weeks. Patient was kept on follow up.

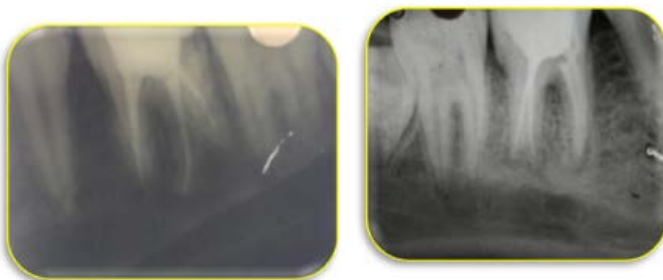PREOPERATIVE IOPA #36 #46



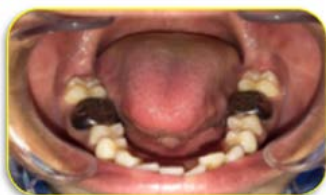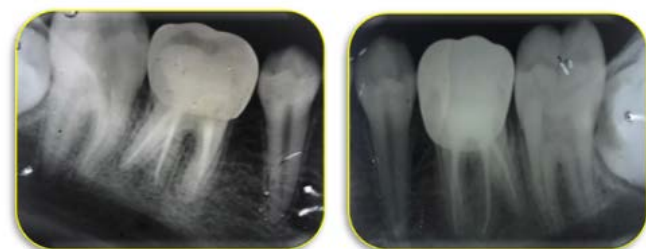
**Working Length**



### Obturation



### Post Operative Iopa With Crowns



### Discussion

Anatomical variations of mandibular molars are documented in literature. The variability of root canal anatomy in distal root of mandibular molars may not be common knowledge. Next to distolingual canal, a third distolingual root in mandibular molar teeth, with an incidence ranging from 0.9 to 20% is possible in some population<sup>5</sup>. Endodontic success in the presence of RE depends on its diagnosis, anatomy or morphology, canal configuration and clinical approach. An accurate diagnosis of RE can avoid complications like missed canal which is

common reason for endodontic failure. Clinically, apart from awareness about the possible existence and racial prevalence of RE, factors such as an extra cusp, prominent DL lobe, cervical convexity, complex external contour of furcation can indicate presence of RE. Also double periodontal ligament can hint to presence of RE. An angled radiograph (25-30°) can be more useful in this regard and it is said that mesial angled radiograph is better than distal for RE detection. Modification of conventional triangular access to obtain trapezoidal outline form assists in locating orifice of RE. RE is generally smaller than distobuccal and mesial roots. Further, depending upon location of its cervical part, RE has been categorized into types A,B,C and AC. RE having a distally located cervical part and two normal distal root components belongs to type A, while a similar RE with one normal distal root is considered as type B. Type C refers to a mesially located cervical part, while type AC refers to RE centrally located between distal and mesial root components<sup>6,7</sup>. Conventional radiographs give only 2- dimensional view of teeth, whereas Spiral Computerized Tomography show detailed 3-dimensional images for endodontic applications. CT images seem to be more accurate and look to be a promising tool for investigating prevalence and features of DL roots in molars<sup>8</sup>. Clinicians need to know about short length and severe curvature of DL roots because it can increase the risk of accidents such as instrument separation and ledge formation. It is known that cyclic fatigue decreases with increase in angle of curvature. Thus, decreasing taper tonicity, using smaller apical diameters, NiTi files and preflaring of cervical third are indicated to avoid accidents. considering the prevalence and characteristics of DL root, clinicians should be able to diagnose and develop skills to provide adequate root canal treatment when this variation is present<sup>9-11</sup>

## Conclusion

Clinicians should be aware of the potential for unusual root morphologies in the mandibular first molars. An initial diagnosis of an RE before root canal treatment is important in facilitating endodontic procedures and avoiding missed canals. Care should be taken in interpreting preoperative periapical radiographs so that any additional roots might be identified. Opening cavity will have to be modified depending on the location of additional root and its root canal orifice. The morphology of an RE will vary in terms of root inclination and canal curvature, which means that great care should be taken in choosing a clinical approach that will prevent or overcome procedural errors during endodontic therapy. This case report explains in detail how to diagnose and endodontically manage cases of RE.

**Acknowledgments:** The Authors declare that there is no conflict of interests regarding publication of this paper

## References

1. Sinha DJ, Mahesh S, Jaiswal N, Vasudeva A. Radix Entomolaris: A Report of two cases. Bull Tokyo Dent Coll (2016) 57(4):253-258
2. Calberson FL, De Moor RJ, Deroose CA. The Radix Entomolaris and Paramolaris: A Clinical approach in endodontics. American Association of Endodontics (2007) 33:58-63
3. Abrami S. The Radix Entomolaris :management of distolingual root canal. Giornale Italiano di Endodonzia (2016) 30:120-123
4. Verma S, Goel M, Singh M, Mandhotra P, Kumar V. Prevalence of Radix Entomolaris in Mandibular First Molars of North Indian Population of Sundernagar, Himachal Pradesh. Journal of Advances In Medicine And medical research. (2018) 27(5):1-6
5. De Moor R.J.D, Deroose C.A.J.G, Calberson F.L.G. The radix entomolaris in mandibular first molars: an endodontic challenge. International endodontic journal.(2004) 37:789-799
6. Pai A.R.V, Jain R, Colaco A.S. Detection and endodontic management of radix entomolaris: Report of case series. Saudi endodontic journal. (2014) 4:77-82
7. Chourasia HR, Meshram G.K, Warhadpande M, Dakshindas D. Root canal morphology of mandibular first permanent molars in an Indian population. International journal of dentistry. 2012 ,6 pages
8. Garg A.K, Tewari R.K, Agrawal N. Prevalence of three rooted mandibular first molars among Indians using SCT. International journal of dentistry. 2013, 6 pages
9. Rodrigues C.T, Santos C.D.O, Bernardineli N, Duarete M.C.H, Bramante C.M, Bonfante P.G.M, Zapata R.O. Prevalence and morphometric analysis of three rooted mandibular first molars in Brazilian subpopulation. Journal of applied oral science. (2016) 24(5):535-42
10. Selvakumar H, Kavitha S, Bharathan R, Varghese J.C. Five canalled and three rooted primary second mandibular molar. Case reports in dentistry. 2014, 4 pages
11. Peikoff M.D, Perry J.B, Chapnick L.A. Endodontic failure attributable to a complex radicular lingual groove. Journal of endodontics. (1985) 11(12):573-7