

Multidisciplinary Management of a Subgingivally Fractured Tooth: A Case Report

¹Avani Gupta, Post graduate student, Sri Aurobindo College of Dentistry, Madhya Pradesh Medical Science University, Indore, India

²Bharath Bhushan A.K., Professor & Head of the Department, Madhya Pradesh Medical Science University, Indore, India

³Fenu Dafaria, Post Graduate Student, Madhya Pradesh Medical Science University, Indore, India

⁴Dr. Abhilasha Manker, Senior lecturer, Sri Aurobindo College of Dentistry, Madhya Pradesh Medical Science University, Indore, India

⁵Dr. Binti Rani Chand, Reader, Sri Aurobindo College of Dentistry, Madhya Pradesh Medical Science University, Indore, India

⁶Dr. Khushboo Barjatya, Reader, Sri Aurobindo College of Dentistry, Madhya Pradesh Medical Science University, Indore, India

Corresponding Author: Avani Gupta, Post graduate student, Sri Aurobindo College of Dentistry, Madhya Pradesh Medical Science University, Indore, India

Citation of this Article: Avani Gupta, Bharath Bhushan A.K., Fenu Dafaria, Dr. Abhilasha Manker, Dr. Binti Rani Chand, Dr. Khushboo Barjatya, “Multidisciplinary Management of a Subgingivally Fractured Tooth: A Case Report”, IJDSIR- January - 2020, Vol. – 3, Issue -1, P. No. 212 – 218.

Copyright: © 2020, Avani Gupta, et al. This is an open access journal and article distributed under the terms of the creative commons attribution noncommercial License. Which allows others to remix, tweak, and build upon the work non commercially, as long as appropriate credit is given and the new creations are licensed under the identical terms.

Type of Publication: Case Report

Conflicts of Interest: Nil

Abstract

Anterior teeth with subgingivally extending fractures requires a complex treatment plan addressing biologic, esthetic, and functional factors, such as mastication and speech, especially in pediatric patients. The purpose of this clinical report was to present multidisciplinary management of a vertical crown root fracture extending subgingivally of a permanent maxillary left central incisor in a 10-year-old boy by describing a technique using direct composite restoration. Due to the complex nature of the treatment, a multidisciplinary approach was used to restore the tooth. The crown fragment was removed, and

endodontic treatment was performed. A glass fiber post was placed to improve retention, and a direct composite restoration was placed followed by polycarbonate crown. A clinical and radiographic evaluation at a follow-up appointments of 1 month, 3 month and 6 months later confirmed that the technique used in this case can be a good option for restoring anterior teeth with subgingival fractures.

Keywords: Complicated crown fracture, complicated crown root fracture, glass fibre post, traumatic dental injuries.

Introduction

Seeing children grow into adolescents is an incredible experience for parents. Throughout this youthful and energetic period children are constantly subjected to new experiences and adventures that help them develop their survival instincts. Simultaneous with the growing up process, they are also more prone to accidents especially accidental injuries to the oro-facial region, in particular dental trauma.[1]

Etiological factors commonly reported for dental related injuries include fall, especially from a bicycle or contact sports and also motor vehicle accidents.[2-5] The most frequently affected teeth are the maxillary incisors, particularly maxillary central incisors with reportedly more trauma in boys than in girls[5]. Children between the ages of 8 to 11 years old are generally reported to be affected (78.53%)[2]. Increased overjet more than 4 mm and incomplete lip closure are said to be some of the common predisposing factors for dental trauma[6].

Complicated crown-root fracture is a rare injury in which the fracture line originates in the crown portion and extend apically into the root in an oblique direction[7] usually resulting from horizontal impact, which involves enamel, dentin and cementum, occurs below the gingival margin and is classified as complicated or uncomplicated, depending on whether pulp involvement is present or absent[8]. Epidemiological statistics revealed that crown-root fractures represent 5% of dental injuries. Several factors influence the management of coronal tooth fractures, including extent of fracture i.e. biological width violation, endodontic involvement, alveolar bone fracture, pattern of fracture and restorability of fractured tooth and associated root fracture, secondary trauma injuries, soft tissue status, presence/absence of fractured tooth fragment and its condition for use (fit between fragment and the

remaining tooth structure), occlusion, aesthetics, finances, and prognosis[9-11].

Trauma to anterior teeth is undesirable and an untreated and unsightly fracture of it affects the behavior of a child, his/her progress in school, and have more impact on their daily living. Thus, prevention of this is beneficial for the personality development of the child. The treatment decisions in pediatric patients should be made according to available technical capability, behavior management, continuing growth guidance, and motivation of the patients throughout a comprehensive and multidisciplinary treatment plan[12].

The purpose of this paper is to present a multi-disciplinary treatment approach in a case of traumatized maxillary central incisor tooth with sub-gingival fracture and its management while maintaining the healthy periodontal tissue and alveolar bone.

Case Report

A 8-year-old male child resident of Bihar with no contributory medical history reported to the Department of pediatric and preventive dentistry with chief complaint of broken tooth in upper front tooth region. The history revealed trauma 1 month back when he had a fall while sitting on a buffalo which was associated with gingival bleeding. No gross facial asymmetry was reported on extraoral examination.(Fig. 1a).

The intraoral examination revealed fractured 21 with fractured line extending from incisal edge to passing sub gingivally in the labiopallatal aspect (Fig. 1b), (Fig. 1c). Tooth was tender on percussion, with grade III mobility and only gingival attachment present with respect to fractured mesial fragment. Also, patient was unable to approximate his teeth on biting. Provisional diagnosis of Ellis's class VI fracture wrt 21 was formulated and intra oral periapical radiograph was advised.

Intra-oral radiograph revealed vertical cleavage line of the traumatised tooth extending from coronal portion to the middle third of the root (approximately 7mm subgingivally) with no apparent periapical pathology (Fig. 2). The apices of the central incisors were nearly completely formed. Clinical and radiographic findings showed no pathological signs in the adjacent teeth.

Clinical and radiographic examinations were suggestive of complicated vertical crown root fracture of 21 involving enamel, dentine, pulp and cementum that is Spinus subclass d1 fracture wrt 21. Treatment plan of endodontic therapy with 21 with fibre post and core build up followed by prosthetic rehabilitation was formulated.

Fractured 21 was anaesthetized with local anaesthetic solution. The coronal tooth fragment (mesial fragment) was detached and the extent of trauma was further investigated (Fig. 3a). Due to sub gingivally extending fracture line and overgrowth of tissue in the fragment area, achieving isolation was a great challenge. The pulpal tissue from the root canal was extirpated with barbed broach (Fig. 3b) and the canal was irrigated with physiological saline and dried with paper point. Electrocauterisation of the gingival growth was carried out following pulp extirpation (Fig. 3c). A size 20 K file was used to estimate the working length (18mm), from the incisal edge (Fig. 4a). The canal was prepared using crown down technique with K files up to the size 45. The canal was irrigated with physiological saline and dried with paper points. Gutta percha points were inserted into the prepared canal and the canal was obturated (Fig. 4b). Subsequently post space preparation was done until an apical 5mm of gutta percha was retained using peso reamer No.3. Fibre post No.3 was selected, inserted through the post space, and luted using flowable composite (Fig. 4c). Fractured segment was built up using band material and flowable composite resin (Fig. 5)

followed by prosthetic rehabilitation with polycarbonate crown (Fig. 6). Occlusion was evaluated (Fig. 7). Post-operative instructions were given to the patient and the patient was recalled after 15 days for evaluation. Clinical and radiographic examinations carried out after 1 month, 3 months and 6 months confirmed the satisfactory aesthetic and functional outcome of the treatment with no associated endodontic or periodontal problem (Fig. 8,9).

Discussion

Spinus et al. (2002) proposed an "easy to use" classification of dental crown lesions that helped to gather data easily, to choose the right materials, to improve communication among practitioners including by electronic means.

It consists of 4 classes (A-B-C-D) and 3 subclasses (b1-c1-d1)

Class A: All the simple enamel lesions, which involve a mesial or distal crown angle, or only the incisal edge. **Class B:** All the enamel dentin lesions, which involve a mesial or distal angle and the incisal edge. When a pulp exposure exists defined as a subclass b1.

Class C: All the enamel dentin lesions, which involve the incisal edge and at least a third of the crown surface. In case of pulp exposure defined as subclass c1

Class D: All the enamel dentin lesions, which involve a mesial or distal crown angle and the incisal or palatal surface, with root cement involvement (crown root fracture) in case of pulp exposure exists defined as subclass d1 [13,14].

According to a Brazilian retrospective study, male individuals suffer significantly more traumatic dental injuries in the permanent dentition than females (2.5:1 ratio), possibly because they are more frequently engaged in physical activities involving physical contact. Majority of traumatic dental injuries involved maxillary central incisor (65.65%) and complicated crown root fractures

(1.35%) with high frequency observed among 6-10 year old children. Complicated crown-root involves tooth structures such as enamel, dentine, cementum and pulp. The severity of presentation varies depending on the strength of the impact force and its vector. Cases may present as vertical crown root fracture, oblique crown-root fracture or with multiple crown- root fractures [16]. Fracture line below the gingival attachment presents restorative problems due to difficulty accessibility.[17] To facilitate further treatment in such cases, orthodontic or surgical exposure(gingivectomy with or without osteotomy) of the fracture margin is necessary. Surgical technique is simple and allows restoration to be completed soon after injury however, in aesthetic regions has unacceptable results and is best used only for the palatal surface of anterior teeth. [18, 19]

According to International Association of Dental Traumatology (IADT) treatment guidelines indicates fragment removal and gingivectomy (sometimes ostectomy) that is, removal of the coronal fragment with subsequent endodontic treatment and restoration with a post-retained crown is indicated. This procedure should be preceded by a gingivectomy and sometimes ostectomy with osteoplasty. This treatment option is only indicated in crown-root fractures with palatal subgingival extension. [20] In the case presented here, electrocauterisation was carried out for removal of overgrowing gingival tissue, to achieve proper isolation & haemostasis followed by endodontic treatment and post and core build up. The treatment options for this type of cases also include reattachment (if fracture fragment is available), post supported direct composite build-up, prosthetic restoration or tooth extraction followed by rehabilitation.[21] In the presented case the approximation of the fractured fragment was not possible, so restoration with glass fiber post and direct composite crown buildup was planned.

The technique has some major advantages: it eliminates the need for sacrificing any tooth structure, less time-consuming, more economic and cheaper than indirect restorations that have additional laboratory cost.[17] By using glass fibre post with composite core and with recent advances in adhesive techniques and materials, one can create a mono-block, a multilayered structure with no inherent weak interlayer interfaces. Therefore, the integrity of the final endodontic – restorative continuum mono-block approaches that of the original healthy tooth itself. An additional use of fibre posts is that they help to distribute the stress uniformly to the remaining radicular dentin [22].

The length of the post ideally should be at least as long as the clinical crown, providing 4–5 mm of gutta-percha apical seal. The diameter of the post should be minimal and not more than one-third of the root diameter. Techniques for removing gutta-percha include solvents, thermal and mechanical removal. Solvents are best avoided as they have the potential to damage the root canal filling material that remains. The thermal method of removing gutta-percha using heat pluggers is safer but more time-consuming. Mechanical removal of gutta-percha point using Gates-Glidden drill or peso reamer is efficient and probably is the most commonly used technique, but it is associated with a higher risk of root perforation if carried out incorrectly. To avoid this problem, in present case, 215eso reamers were used on slow speed with continuous up and down motion along with cooling arrangement.[17]

The location of the fracture line in fractured teeth affects not only the treatment options but also the prognosis[6]. The clinical outcomes and prognosis of teeth that are fractured in the subgingival area have been found to be the most bleak because of the loss of the coronal fragment stability and pulpal vitality[12].The favorable clinical

outcome of these kinds of cases, however, often implies a multidisciplinary approach of orthodontic, endodontic, periodontal, and prosthetic therapy with patient cooperation. The treatment approach must be focused on exposure of the subgingivally fractured margins so that all clinical procedures can be managed with strict control of moisture and blood contamination.[7]

In present case, endodontic treatment and surgical exposure of fractured line followed by post and core and prosthetic rehabilitation was found to be the best treatment option. As the fractured fragment of the tooth was not intact and displaced from place, removal of the fragment followed by multidisciplinary t/t approach for tooth was considered.

Conclusion

Smile is the greatest treasure and self confidence the best accessory a person can own. Hence, the necessity for a multidisciplinary approach in the treatment of complicated dental traumas should be considered in respect to biological, functional, and esthetic aspects so that rehabilitation of tooth can be achieved in a conservative and predictable way.

In the case described in this article, root resorption was not found after 6 months of follow-up. Atraumatic extraction, systemic antibiotic prescription, root canal filling with calcium hydroxide between treatment sessions, good coronal restoration with high quality sealing, and patient cooperation for maintaining good oral hygiene are important factors for better prognosis of the treatment procedure. Long-term follow-up is required for such cases.

References

1. Gassner R, Tuli T, Hächl O, Moreira R, Ulmer H. Craniomaxillofacial trauma in children: a review of 3,385 cases with 6,060 injuries in 10 years. *Journal of*

- oral and maxillofacial surgery.* 2004 Apr 1;62(4):399-407.
2. Tapias MA, Jiménez-García R, Lamas F, Gil AA. Prevalence of traumatic crown fractures to permanent incisors in a childhood population: Mostoles, Spain. *Dental Traumatology.* 2003 Jun;19(3):119-22.
3. Glendor U, Marcenes W and Andreasen JO (2007). Classification, epidemiology and etiology. In: Andreasen JO, Andreasen FM and Andersson L (eds.), *Textbook and Color Atlas of Traumatic Injuries to the Teeth.* 4th edn. Copenhagen, Denmark: Blackwell-Munksgaard, pp. 217-244.
4. Castro JC, Poi WR, Manfrin TM, Zina LG. Analysis of the crown fractures and crown-root fractures due to dental trauma assisted by the Integrated Clinic from 1992 to 2002. *Dental traumatology.* 2005 Jun;21(3):121-6.
5. Çetinbaş T, Yildirim G, Sönmez H. The relationship between sports activities and permanent incisor crown fractures in a group of school children aged 7–9 and 11–13 in Ankara, Turkey. *Dental traumatology.* 2008 Oct;24(5):532-6.
6. Andreason JO, Andreason FM, Andreason L, editors. *Textbook and color atlas of traumatic injuries to the teeth.* John Wiley & Sons; 2013.
7. Faghihian R, Eshghi A, Mosleh H, Akhlaghi N. Management of Complicated Crown-Root Fracture in Central Incisors Using Intentional Replantation with 180° Rotation: A Case Report. *Dent Hypotheses* 2017;8:113-6.
8. Fidel SR, Fidel-Junior RA, Sassone LM, Murad CF, Fidel RA. Clinical management of a complicated crown-root fracture: a case report. *Brazilian dental journal.* 2011;22(3):258-62.
9. Islam MA, Wakia T, Alam MS, Howlader MM, Afroz S. Management of a Subgingivally Fractured Central

- Incisor by Re-attachment Using a Fiber Post. Update Dental College Journal. 2013;3(1):37-40.
10. Olsburgh S, Jacoby T, Krejci I. Crown fractures in the permanent dentition: pulpal and restorative considerations. *Dent Traumatol* 2002; 18(3):103–15
 11. Reis A, Francci C, Loguercio AD, et al. Re-attachment of anterior fractured teeth: fracture strength using different techniques. *Oper Dent* 2001; 26(3):287–94
 12. Ulusoy AT, Tunc ES, Cil F, İsci D, Lutfioglu M. Multidisciplinary treatment of a subgingivally fractured tooth with indirect composite restoration: A case report. *Journal of Dentistry for Children*. 2012 Jul 15;79(2):79-83.
 13. Spinass classification Enrico Spinass, Altana. A new classification for crown fractures of teeth. *J Clin Ped Dent.*, 2002; 26: 69-85.
 14. Pagadala S, Tadikonda DC. An overview of classification of dental trauma. *IAIM*, 2015; 2(9): 157-164.
 15. Guedes OA, Alencar AH, Lopes LG, Pécora JD, Estrela C. A retrospective study of traumatic dental injuries in a Brazilian dental urgency service. *Brazilian dental journal*. 2010;21(2):153-7.
 16. Glendor U, Marcenes W and Andreasen JO (2007). Classification, epidemiology and etiology. In: Andreasen JO, Andreasen FM and Andersson L (eds.), *Textbook and Color Atlas of Traumatic Injuries to the Teeth*. 4th edn. Copenhagen, Denmark: Blackwell-Munksgaard, pp. 217-244.
 17. Sheikh MA, Karim FA, Parveen S. Management of a Complicated Crown Fracture in a Tertiary Care Hospital. *Journal of Enam Medical College*. 2017 Jan 30;7(1):35-8.
 18. Andreasen JO, Andreasen FM, Andersson L. Crown-root fractures. In: *Textbook and color atlas of traumatic injuries to the teeth*. 4th edn. Copenhagen: Blackwell Munksgaard, 2007: 314–336.
 19. Emerich-Poplatek K, Sawicki L, Bodal M, Adamowicz- Klepalska B. Forced eruption after crown/root fracture crown. *Dent Traumatol* 2005; 21: 165–169.
 20. Flores MT, Andersson L, Andreasen JO, Bakland LK, Malmgren B, Barnett F, Bourguignon C, DiAngelis A, Hicks L, Sigurdsson A, Trope M. Guidelines for the management of traumatic dental injuries. I. Fractures and luxations of permanent teeth. *Dental traumatology*. 2007 Apr;23(2):66-71.
 21. Torvi SJ, Kala M. Restore the natural — a review and case series report on restoration. *J Clin Exp Dent* 2004; 6(5): e595–e598.
 22. Alexander RN. Management of a Fractured Anterior Tooth by Reattachment using Fiber-reinforced Post Alexander RN. Management of a Fractured Anterior Tooth by Reattachment using Fiber-reinforced Post.

Legends Figures

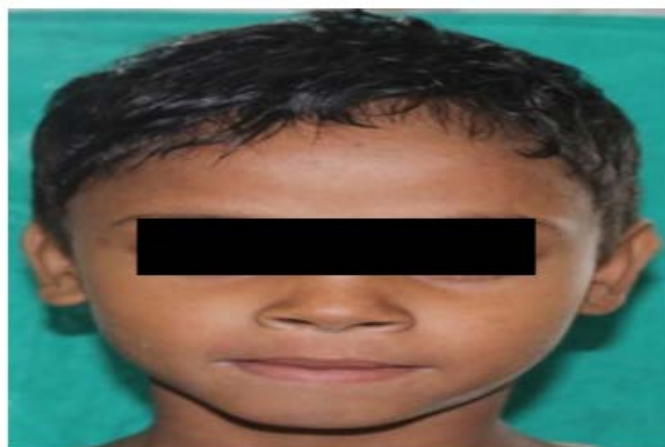

Fig.1a:Extraoral view

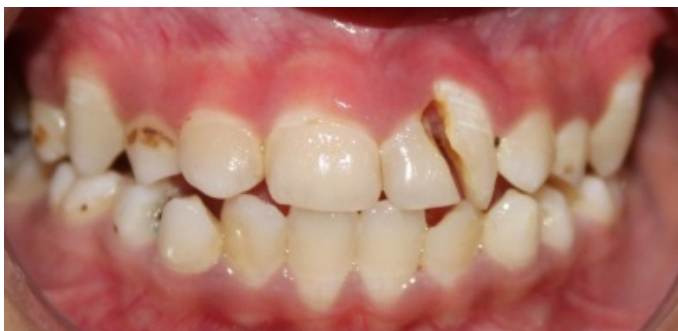

Fig.1b: Intraoral buccal view

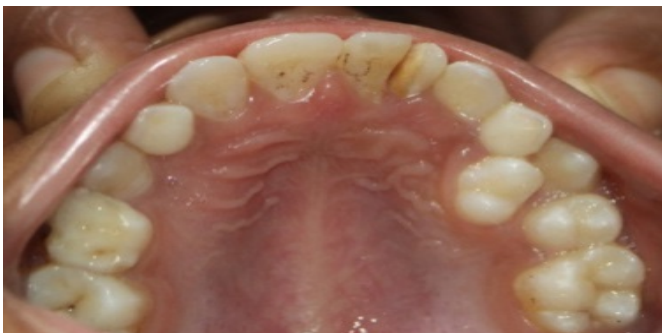

Fig.1c: Intraoral palatal view

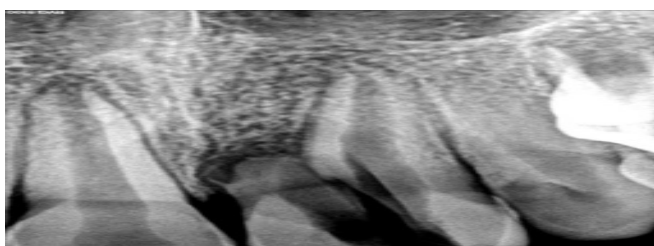


Fig.2 : Initial RVG showing complicated crown root fracture with 21.

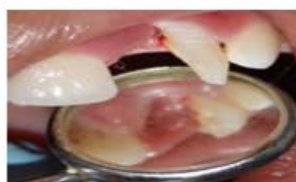

Fig.3a

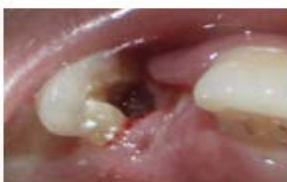

Fig.3b

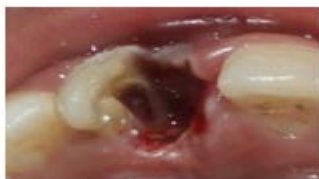

Fig.3c

Fig. 3: Clinical picture (a) after detachment of mesial coronal fragment (b)postpulp extirpation (c)Post electrocauterisation

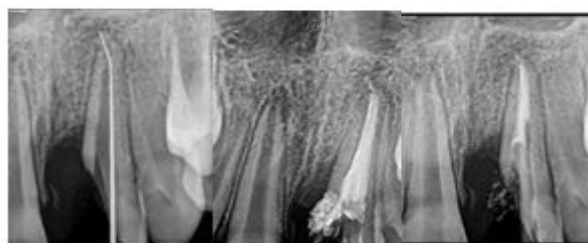

Fig.4a

Fig.4b

Fig.4c

Fig.4 : (a)Working length determination ; (b) Root canal filled with guttapercha ; (c) Post space preparation and fibre post placement

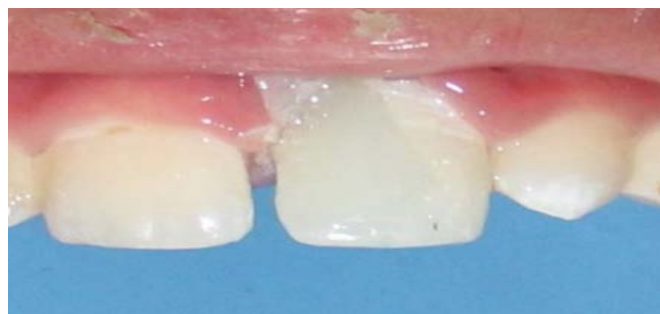

Fig. 5: Composite build up with 21

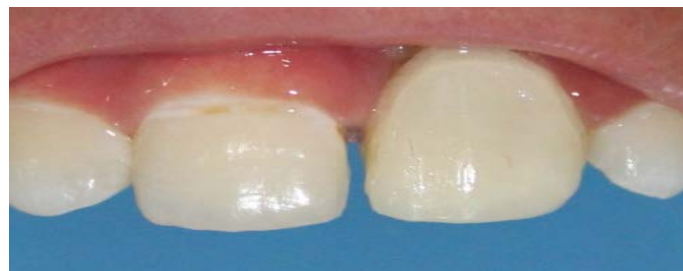

Figure 6: Polycarbonate crown placement

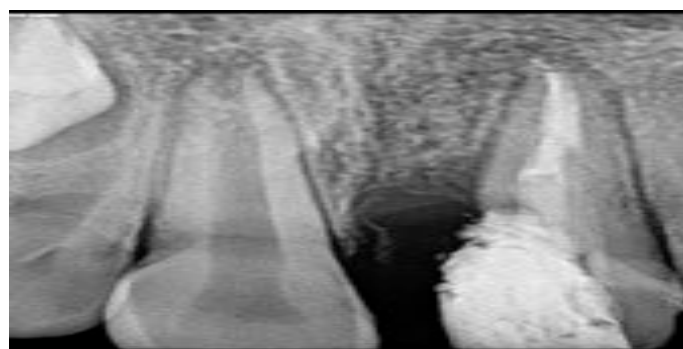


Figure 7 : Check radiograph after composite restoration