

Strategic Implant Key-Hole Placement- A Case Series

¹Dr K S Manjunath, HOD, Department of oral and maxillofacial surgery , Sri hasanamba dental college and hospital
vidyanagar Hassan Karnataka India

²Dr Fathima Shamra, Department of oral and maxillofacial surgery , Sri hasanamba dental college and hospital vidyanagar
Hassan Karnataka India

³Dr Bindhu Ghorpade, Department of oral and maxillofacial surgery, Sri hasanamba dental college and hospital
vidyanagar Hassan Karnataka India

⁴Dr Nivedita Sajeev, Department of oral and maxillofacial surgery, Sri hasanamba dental college and hospital vidyanagar
Hassan Karnataka India

Corresponding Author: Dr Fathima Shamra, Department of oral and maxillofacial surgery , Sri hasanamba dental college and hospital vidyanagar Hassan Karnataka India

Type of Publication: Case Report

Conflicts of Interest: Nil

Abstract

Rehabilitation of atrophied or a resorbed ridge is quite challenging procedure. The main treatment objective is to restore a balanced and efficient masticatory function. Basal implants are one piece implants in which the implant and the abutment are fused into one single piece and procedure is done in one sitting. This article is a review of 3 cases where we treated with cortical implants and immediate loading done within 72 hours. Immediate Loading has gained popularity due to less tissue trauma, reduced overall treatment time and visits, decreased patient's anxiety and discomfort, high patient acceptance and better function and aesthetics.

Keywords: Atrophic jaws, basal implants, full mouth rehabilitation, immediate loading

Introduction

The bi-cortical implants works on the principle of engaging cortical bone or basal bone. Thus it targets to engage mainly crestal and basal cortical bone and if required buccal or lingual cortical bone for support. If the

available vertical bone supply is insufficient, measures are taken to rebuild the morphology of the bone tissue by transplantation, by augmentation or by inducing alveolar bone growth. Many a times these adjuvant measures are considered more time consuming and expensive for the patients to afford. Due to the additional cost of these adjuvant measures, many patients are not able to afford implant treatment. Because of these reasons aesthetic and masticatory functions cannot be restored. Basal implants have become popular in recent years. Advantages of basal implants over endo-osseous implants are no augmentation, distraction or transplantation of bone required, it is a one-step procedure, simple repair in case of any problem during surgery, combination with natural teeth, crestal implant or compressive implants are possible, very few components, laboratory steps are very simple. Roughened implant surfaces close to the oral cavity involve a greater risk of bacterial retention where as in basal implant entire shaft has smooth surface. The smooth surface of the implant prevents any retrograde infection and bacterial

colonization. With this advantage, part of polished bi-cortical implant can be lodged inside the maxillary sinus or above nasal floor in the anterior maxilla without any risk of infection.¹ However smooth surface of the cortical implants offers lesser primary stability against friction and rotation, and hence multiple numbers of such implants are inserted especially in immediate-loading cases.

Case Reports

Case 1

A 34-year-old female patient with severe chronic generalized periodontitis was planned for total extraction of teeth because of very poor periodontal prognosis, and hence treated with bi-cortical implant and immediate loading done within 72 hours. Anterior maxilla planned for 6 bi-cortical implants engaging nasal cortex and maxillary sinus floor and one compressive implant. Posteriorly 3 bicortical implants are engaged to pterygoid junction 1 in the left and 2 in the right side of the maxilla. In mandible four bi-cortical implants are placed in the anterior region, 3 bicortical implants in the posterior region engaging the mylohyoid ridge lingually and one compressive implant. Patient is been followed up since 2 years and she is very much satisfied with the treatment.

Case 2

A 46-year-old female patient with severely atrophied jaws was planned to treat with the combination of compressive and bi-cortical implant and immediate loading. Patient revealed history of loose teeth and got it extracted 2 years back and was using removable complete denture. Patient was not happy with the prosthesis and decided to get it done fixed. Full mouth rehabilitation and immediate loading was done in 3 days. Patient had insufficient bone, resorbed ridge in mandible when compared with the maxilla. Anterior maxilla was planned with 4 bi-cortical implants and one compressive implant in the right side, 4 bi-cortical implants in the left side engage the nasal cortex

and floor of the maxillary sinus. In mandible, 3 bi-cortical implants and 1 compressive implant in right side, 2 bi-cortical and 2 compressive implants on the left side. Patient is regularly followed up since 1.5 years and she is very happy with her fixed prosthesis.

Case 3

A 42-year-old female patient visited to our department complaining of loose denture and wanted to have a fixed denture to be delivered at the earliest. Patient past dental history revealed grossly decayed teeth and were extracted over a period of 3 years. She was using removable complete denture since 6 months and was not happy with the prosthesis as it was found to be less retentive denture. So we planned for full mouth rehabilitation with immediate loading basal and compressive implants. Patient had adequate bone both in maxilla and mandible. Anterior maxilla was planned for 6 bi-cortical implants engaging nasal cortex and maxillary sinus floor and 2 compressive implants. Posteriorly 2 bicortical implants are engaged to pterygoid junction 1 in the left and 1 in the right side of the maxilla. In mandible 4 bi-cortical implants are engaged in the anterior region, in posterior region 4 bicortical implant engaging the mylohyoid ridge lingually in either side. Patient is been followed up since 1 years and she is happy about her fixed prosthesis and she is maintaining it well.

Technique

Preoperative panoramic radiograph and cone beam computed tomography is done for all the cases. All 3 cases are done under local anesthesia infiltration by using lignocaine hydrochloride with 2% adrenaline and preoperative prophylactic antibiotics. The surgical site was disinfected with chlorhexidine mouth wash, 5% povidine iodine solution and normal saline. It is always better to use undersized osteotomy drill in maxilla to increase the primary stability as bone types available are

D3 D4. As in mandible osteotomy drill of same size was used as the bones available are D2 D1. Implants placed in all the 3 cases by using osteotomy implant drills under constant coolants by using normal saline to prevent the thermal injury. First osteotomy drill is done with the use of pathfinder drill to perform osteotomy in cortical bone; this is followed by twist drill to enlarge the implant bed. Second cortical perforation is the most important step because the osteotomy drills have to be extended to involve both the cortex. If the basal bone or the second cortical bone is not perforated, engagement of the implant to second cortical bone does not happen. In maxilla, nasal & sinus floor, pterygomaxillary junction acts as a basal cortical bone. In mandible in posterior region, lingual near to myloid ridge or buccal corical acts as a second cortical bone whereas in anterior mandible if bone is dense, there is no need to perforate any bone, if anterior mandible bone is hollow it is better to perforate base of mandible and engage implant. In case of compressive implants corticalisation of cancellous bone is achieved by preparing under osteotomy and placing an implant of diameter wider than the osteotomy site. Implant is bent after insertion of the implant for parallelism with the help of hand insertion tool. The neck of the implant is bended to make multiple implant heads parallel for passive seating of the prosthesis and also to seat the prosthesis in the most suitable occlusion line.

Discussion

Basal implantology is a fast, safe & painless procedure with unique advantages of immediate loading, avoidance of bone grafting, single piece implantology with the support of basal or cortical bone support done in minimal invasive methods often flapless and involving minimum bone cutting. It is associated with minimum post-operative edema and healing at the procedure sites and often non-eventful. These implants are unique and eminent and they

utilize the available bone in the best possible manner to avoid bone augmentation procedures. Cortical Implantology follows the concepts of Orthopedics and Traumatology the two main principles used in fracture treatment with plates and screws are multi-cortical engagement with non-parallel screws, Immediate rigid splinting of screws with plate and early functional mobilization.² Similarly in Cortical Implantology, implants are engaged in more than one cortex and are kept non-parallel. They are immediately splinted with a rigid metal based prosthesis and are immediately loaded for function. Achieving primary stability is easy in basal implant compared to endo-osseous implant as basal implant is cortical engaged implant and it is less technique sensitive unlike endo-osseous implants. Due to the monobloc design of basal implants, that is basal implants are one piece implants in which the implant and the abutment are fused into one single piece. This will minimize failure of implants due to interface problems between the connections which exist in conventional two and three piece implants.⁴ Good bi-cortical bone engagement with immediate splinting of the implants with the help of prosthesis allows immediate loading of the implant.¹ Due to high primary stability of these implants, prosthesis were loaded immediately, within 72hour. Here the need of provisional dentures is totally eliminated most of the time, and second surgery for implant exposure in order to fix the abutment over the implant. These implants take support from the cortical bone areas which are free from the infection and less prone to resorption. Bi-cortical implant has a polished rounded, noncutting part at the end of the implant which helps in lifting the sinus membrane without perforating. If the implant has to be inserted through the sinus, any infection related to sinus has to be treated in prior to avoid implant loss in future. Peri-implantitis is the most common cause for failure of

conventional crestal implants. This happens usually because of the rough implant surface near the crestal region which makes easy for the micro-organisms to harbor as well as the interface problems between the multiple parts of the implant. Because of the monobloc design and smooth surface of the basal implants it will eliminate the threat of peri-implantitis by almost 98%.⁴ OPG is always recommended prior to treatment to evaluate the vertical bone available at planned implant insertion site. Postoperative antibiotic and analgesics, tablet ornidazole 500mg one bid, tab amoxicillin 500mg + tab clavunic-acid 125mg, tab acefenac 100mg + paracetamol 325mg are given for 5 days. Long term treatment success depends on the close follow up after the treatment; subsequent recalls every 6 months for first one year has been done. Basal implantology is an amazing solution for unfavorable bone situations. Basal implants are the extremely good means of oral rehabilitation in deficient bone or atrophied jaw conditions. Bi-cortical engagement of basal implants provides a good primary stability as well as it permits an infection resistant environment for the implant since the load bearing areas are far away from the areas where the bacteria attempt to invade the crestal alveolar bone. However, a thorough understanding of the maxillofacial anatomy is required for the placement of basal implants as this surgical modality requires a proper set up. The technique of basal implantology resolves all problems associated with conventional implants.

Conclusion

Cortical implantology emerged as a boon in our field and helped both the surgeon and the patient for partial and complete oral rehabilitations with inadequate bone height and resorbed ridges. These implants are specifically designed to engage strong cortical bone of the jaw so they are considered to be the best option for immediate loading.

The augmentation procedures of grafts increase the cost, time and psychological well-being of the patient which can be totally eliminated most of the time in cortical implantology. Virtually every patient can be treated without bone grafting in this system of implants. Evolutions of cortical implants had given positive hope for the patients with atrophied ridges by immediately loading of the prosthesis making them more confident and socialize normally.

Acknowledgement: The success and final outcome of this manuscript required a lot of guidance and assistance from our beloved HOD Dr. K.S MANJUNATH. We are extremely grateful to him for providing constant support, guidance and giving opportunity to write this manuscript. I am very thankful to my co-authors for their effort and co-operation to complete the manuscript.

References

1. Ihde S. Dental implant treatment using cortical bone or corticalized bone areas. *CMF Implant Dir.* 2010;4:04–22.
2. Garg R, Mishra N, Alexander M, Gupta SK. Implant survival between endo-osseous dental implants in immediate loading, delayed loading, and basal immediate loading dental implants a 3-year follow-up. *Ann Maxillofac Surg* 2017;7:237-44.
3. Yadav RS, Sangur R, Mahajan T, Rajanikant AV, Singh N, Singh R. An alternative to conventional dental implants: Basal implants. *Rama Univ J Dent Sci* 2015;2:22-8.
4. S.A.S Sohaib, S.C. Nagaraal, M.M Asad: Basal Implants : A Breakthrough For Atrophic Ridges: *Review Journal of Applied Dental and Medical Sciences* 2454-2288.
5. B Jogeswar, P Nirupam, G Barasha: Demystifying basal implant: *global journal for research analysis* volume-8, issue-4, april-2019 • p no 2277 – 8160.

6. N Grishmi, M Mitul : basal implants- a remedy for resorbed ridges; World Journal of Pharmaceutical and Life Science, 2017, Vol. 3, Issue 1, 565-572.
7. S Rahul, P Jai, A Dhruv, et al: basal implants–an alternate treatment modality for atrophied ridges. International Journal of Current Medical And Pharmaceutical Research, Vol. 3, Issue, 01, pp.1186-1190, January, 2017.
8. S Rahul, P Jai, A Dhruv et al, basal implants – an alternate treatment modality for atrophied ridges;

international journal of research in dentistry: Volume 6 Issue 5 Sep-Oct.2016.

Legends Figures

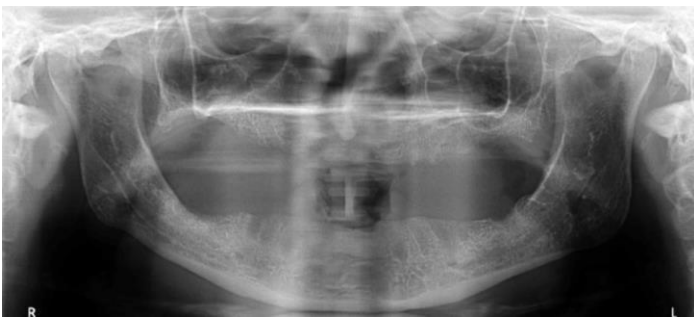


Fig.1: case no.1 preoperative OPG

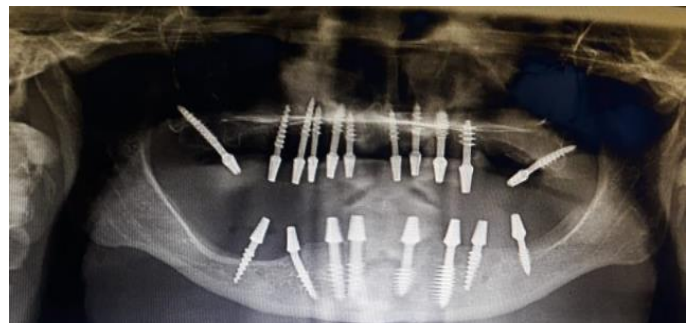


Fig.4: case no.2 postoperative OPG

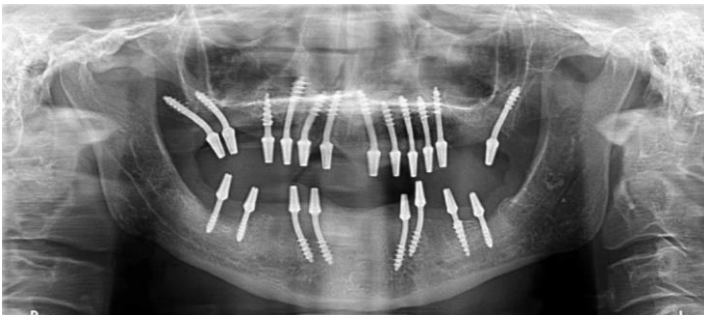

Fig.2: case no. 1 postoperative OPG

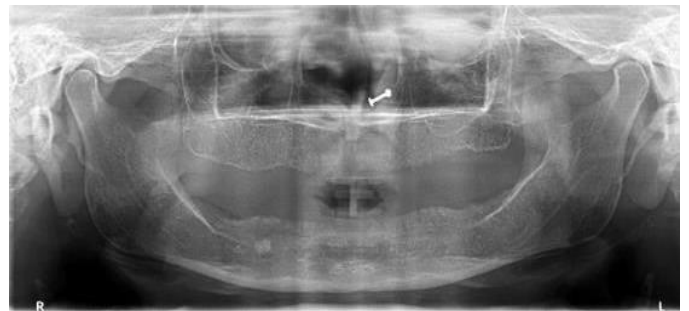


Fig .5: case no.3 preoperative OPG

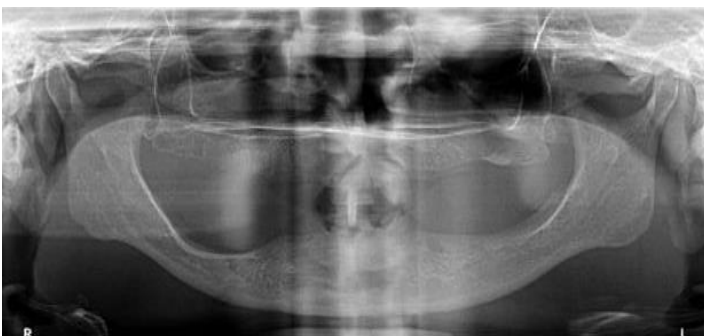

Fig.3: case no.2 preoperative OPG

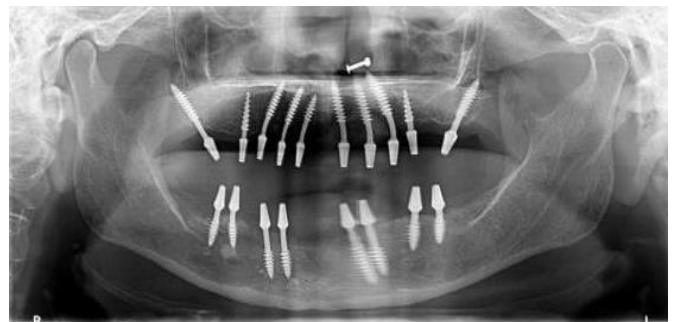


Fig. 6: case no.3 postoperative OPG