

Evaluation of Correlation between Epidermoid Carcinoma and Dermatoglyphics - Research Study

¹Geeta Sharma, Professor and Head, Department of Oral Pathology, Sarjug Dental College, Darbhanga, Bihar

²Randhir Kumar, Professor and Head, Department of Periodontia, Patna Dental College and Hospital, Patna, Bihar

Corresponding Author: Randhir Kumar, Professor and Head, Department of Periodontology, Patna Dental College and Hospital, Patna

Type of Publication: Original Research Article

Conflicts of Interest: Nil

Abstract

Background: Dermatoglyphics is the study of epidermal ridges on the palmar and plantar surfaces¹. After their complete formation, they are unaffected by the environment. This property works as an ideal marker for individual identification as well as detection of defects due to intra uterine irregularities in the early weeks of pregnancy. Oral cancer is one of the 10 leading cancers in the world and is amongst the most frequent cancer in India. Genetically determined susceptibility is the most important etiology for oral cancer. This present study is conducted to analyse the dermatoglyphic patterns in oral cancer patient.

Material and methods: The participants were divided in to two groups- 100 normal and 100 cancer patient without any known etiology. A thin layer of black printing ink material was applied to finger and palm. Imprints of 5 finger tips were recorded in specified boxes and entire palm imprints were recorded in the middle of the A₄ sheets.

Results and conclusion- The difference in the distribution of thenar crease, distal crease and ATD angle is found to be highly significant in oral cancer patient as compared to normal individual loops were also found to be increased in oral cancer.

Keywords: Dermatoglyphics, dermal patterns, distal crease, ATD angle, thenar crease.

Introduction

Cummins and Midlo (1926) were the first to coin the term ‘DERMATOGLYPHICS’². It is the science and art of the study of surface markings of the skin, especially feet and hands. (DERM= Skin, GLYPH= Carving)

Over the past 150 years ,dermatoglyphics has been a useful tool in understanding basic questions in biology, Medicare genetics and evolution, in addition to being the best and most widely used method for personal identification.

Engler³ (1982), in his dermatoglyphics study on breast cancer patients revealed two genes BRCA-1 and BRCA-2 on the q arm of chromosome no. 17 at the 36th position. Dr. Stowens, chief of pathology at St. Luke hospital in Newyork, claims to diagnose Schizophrenia and Leukemia with 90% accurancy from pattern of hand alone

Materials and Method

A cross-sectional study design was conducted and a sample of one hundred patient with squamous cell carcinoma and one hundred normal individual is taken. The patient with cut and wound in the hand are excluded from the study.

The materials used in the study were the basic diagnostic instruments for examination and detection of squamous

cell carcinoma. For recording the palm print, ink pad, magnifying glass and white sheets of paper were used.

Methodology

The study initiated after obtaining approval from institutional ethics committee. Patient's consent was taken before taking the palmer and plantar impression. All the diagnosed cases of squamous cell carcinoma coming to the department of oral pathology were examined.

Recording of finger tip pattern

Subject hands were cleaned and dried before printing. A thin layer of printing ink was applied to the fingers and palms using black printing ink. Imprints of five fingertips were recorded in specified boxes and entire palm imprint was recorded in the middle of A4 sheet. The same procedure was repeated in relation to other hand. Prints were dried and studying using a magnifying lens to identify the finger and palm pattern. After taking the fingerprints of all fingers and palm, ink was removed by using oil, soap and water.

Evaluation of fingertip pattern configurations:

Galton divided the ridge patterns on the distal phalanges of the fingertips into 3 groups. Arches

- 1) Loops
- 2) Whorls

Although numerous sub classifications have been subsequently offered, this simple classification is still recognized and used by majority of investigators today⁴.

(Fig. 1)

1) Arches

It is the simplest pattern found on fingertips. It is formed by succession of more or less parallel ridges, which traverse the pattern area and form a curve that is concave proximal. The arch pattern is subdivided into 2 types.

- 1) Simple arch or plain arch
- 2) Tented arch

The point of confluence is called a triradius, because ridge usually radiate from this point in 3 different directions

2) Loops

It is the most common pattern on the fingertip. A series of ridges enter the pattern area on one side of the digit, recurve abruptly and leave the pattern area on the same side. If the ridge open on ulnar side, resulting loop is termed as ulnar loop.

If the ridge opens toward the radial margin, it is called a radial loop.

- 3) **Whorls**- it is any ridge configuration with two or more triradii. One triradius is on the radial and other on the ulnar side of the pattern.

It is subdivided into 2 types A) Concentric whorl b) Spiral whorl.




Fig. 1: Arch Loop Whorl

Interpretation of palmar print

In the palm of a normal individual, three major creases are seen.

- 1) Distal crease (DC)- originate from the lateral side of the palm and ends in between the pointing finger and the middle finger.
- 2) Proximal thenar crease (PC)- originates from the hypothenar region and ends in between the thumb and pointing finger
- 3) Thenar crease (TC) originate from the base of palm and ends in between the thumb and pointing finger, generally fused with PC⁵

Ridge counting

It is used to indicate the pattern size. The parameter used were-

- a) Total finger ridge count (TFRC)
- b) Absolute finger ridge count (AFRC)
- c) Atd angle

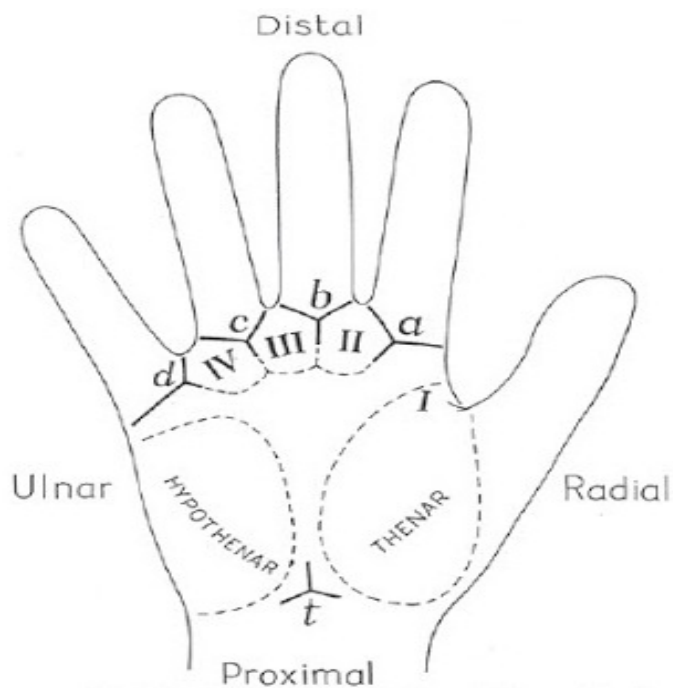


Fig 2: a,b,c,d are the digital triradi, t is axial triradi and II, III and IV are second, third and fourth interdigital areas.

Statistical Analysis

The data recorded was entered in Microsoft excel sheet and applied for statistical analysis.

Chi – square test was applied for each variable, to compare the proportions and p was determined.

Results

Table 1: Distribution of TC in control group and study group

Groups	Normal	Percentage	Variation	Percentage
Control roup(N=200)	165	82.5%	35	17.5%
Study Group(N=200)	147	73.5%	53	26.5%

Table 2: Distribution of PC in control group and study group

Groups	Normal	Percentage	Variation	Percentage
Control Group(N=200)	177	88.5%	23	11.5%
Study Group	185	92.5%	15	7.5%

Table 3: Distribution of DC in Control group and Study group

Groups	Normal	Percentage	Variation	Percentage
Control Group(N= 200)	196	98%	4	2%
Study Group (N= 200)	175	87.5%	25	12.5%

Table 4: Distribution of DC in Control group and Study group

Groups	Normal	Percentage	Variation	Percentage
Control Group(N= 200)	108	54%	92	46%
Study Group (N= 200)	48	24%	152	76%

Table 5: Distribution of variables in variation group

Groups	Normal	Percentage	Variation	Percentage
Control Group(N= 92)	7	8%	85	92%
Study Group (N= 152)	3	2%	149	98%**

Table 6: Distribution of (a) in variables in Control group and Study group

Groups	Normal	Percentage	Variation	Percentage
Control Group(N=92)	199	99.5%	1	0.5%
Study Group (N= 152)	194	9.7%	6	3%***

Table 7: Distribution of (b) in variables in Control group and Study group.

Groups	Normal	Percentage	Variation	Percentage
Control Group(N= 92)	189	94.5%	11	5.5%
Study Group (N= 152)	198	99%	2	1%

Table 8: Distribution of (c) in variables in Control group and Study group

Groups	Normal	Percentage	Variation	Percentage
Control Group(N= 200)	170	94.5%	11	5.5%
Study Group (N= 200)	198	99%	2	1%

Table 9: Distribution of (d) in variables in Control group and Study group.

Groups	Normal	Percentage	Variation	Percentage
Control Group(N= 200)	131	65.5%	69	34.5%
Study Group (N=200)	136	68%	64	32%

Discussion

Dermatoglyphics are the dermal ridge configurations on the digits, palms and soles. They begin to develop about the 13th week of prenatal life, as the fetal mounds on the digit tips, interdigital, thenar and hypothenar areas of the hand. The pattern formation is complete by the 19th week⁶. Dermatoglyphics has been a useful tool in understanding basic questions in biology, medicine and genetics and serves as a tool to predict occurrences and risk for biomedical events. Extensive investigations into chromosomal disorders like Down 's syndrome, turner syndrome etc and their Dermatoglyphic manifestation have been conducted and positive result were found.

Oral cancer, being the most common cancer in India has various etiologic factors like tobacco, alcohol, viral, dietary and genetic factors. Genetically determined susceptibility to external carcinogen may be important in the etiology of squamous cell carcinoma, as many persons exposed to tobacco and alcohol do not develop oral cancer. Identifying persons at high risk for squamous cell carcinoma of head and neck is important thus the present study was planned to check correlation between dermatoglyphic and squamous cell carcinoma.

In the present study, the observations based on 200 cases studied (control group and study group, n= 200), revealed, that the distribution of TC(thenar crease), in the study group, showed normal pattern in 73.5% and varied pattern in 26.5%.

In the distribution of DC(Distal crease), in the study group, was found to be normal in 87.5% and varied in 12.5%

The atd angle was found to be normal in 97% and varied in 3% in the study group. In the varied pattern, the frequency of atd angle above normal and below normal was found to be 2% and 98% respectively.

In the present study, variables that showed statically significant differences between dermatoglyphic pattern of controls and those patients under study-

The difference in the distribution of TC was statistically significant.

The difference in the distribution of DC, atd angle and (c) was highly significant.

In the distribution of patterns of fingertips, the most common pattern seen was ulnar loop (50.7%), followed by single loop whorl (31.8%) in the study group.

Conclusion

Dermatoglyphic is the easy and noninvasive technique to record finger and palm print. Seeing the high cases of oral squamous cell carcinoma this technique can be used as an adjunct to chec genetic susceptibility for high risk patient.

References

1. Boggula Rama M Reddy ,Singararu gowri Sankar & "A Comparative Study of dermatoglyphics in individuals with normal occlusions and malocclusions". J of clinical diagnosis research 2013 Dec, vol – 7(12). 3060-3065
2. Gh.Mohd .Bhat ,M.Arif , Bahin Ahmad shah. Dermatoglyphics : in health and disease. A review. International Journal of Research in Medical Science.
3. Geetha Vishwanath and Ajay Mascarenas: Dermatoglyphics Analysis Of Breast Cancer Patients From Banglore Institute Of Oncology, " Banglore 2002.
4. Blanka Schaumann And Milton Alter, " Dermatoglyphics In Medical Disorders", Newyork Springer Verlag, Berlin.1976: 27-87

5. Geetha vishwanath, Vikram and Michelle D Souza
Dermatoglyphics analysis of Handigodu Joint Disease
Of Maland , Karnataka. J.Ecobiol 2002,14(3):183-188
6. Mathew I, Hedge AM, Rai K. Dermatoglyphics
peculiarities in children with oral clefts. J. Indian Soc
Pedod prev. Dent.2005; 23(4): 179-82.