

**Simplified Technique For Fabrication Of Custom Ocular Tray & Making Ocular Impression - A Clinical Report**

<sup>1</sup>Dr. Santoshkumar P Mastud., MDS, Assistant Professor, Dept of Oral medicine and Radiology, Dr. D Y Patil Dental College and Hospital, Pimpri, Pune.

<sup>2</sup>Dr. Prasad Mhaske, MDS, Assistant Professor, Dept of Prosthodontics, Bharati Vidyapeeth Dental College and Hospital, CBD Belapur, Navi Mumbai.

<sup>3</sup>Dr. Chaitra Mastud, MDS, Assistant Professor, Dept of Orthodontics and Orthopaedics, Dr. D Y Patil Dental College and Hospital, Pimpri, Pune.

<sup>4</sup>Dr. Ketaki Upadhye, MDS, Assistant Professor, Assistant Professor, Dept of Periodontics, Bharati Vidyapeeth Dental College and Hospital, CBD Belapur, Navi Mumbai.

<sup>5</sup>Dr. Deepak M. Vikhe, MDS, Associate Professor, PhD Scholar, Department of Prosthodontics, Rural Dental College, Pravara Institute of Medical Sciences, At/post- Loni (bk), Taluka – Rahata, District – Ahmednagar, Loni – 413736.

**Corresponding Author:** Dr. Santoshkumar P Mastud, MDS, Assistant Professor, Dept of Oral medicine and Radiology, Dr. D Y Patil Dental College and Hospital, Pimpri, Pune.

**Type of Publication:** Case Report

**Conflicts of Interest:** Nil

**Abstract**

Prosthetic rehabilitation of an ocular defect can be successfully achieved with stock eye by using well fitting ocular tray and a proper impression technique. The tissue adaptation of stock prostheses can be improved by making an accurate impression of an ophthalmic socket using custom ocular tray. This article presents a technique for the fabrication of custom ocular tray and procedure for making impression of eye socket using the same.

**Keywords:** Ocular tray, ocular prosthesis, stock eye prosthesis

**Introduction**

Ocular prosthesis is an artificial replacement of bulb of the eye. A well-fitting ocular prosthesis enhances esthetics, improves facial contours and helps the patient overcome psychological trauma. Ocular prostheses are either ready made (stock) or custom made.<sup>1</sup> Stock prostheses are usually advocated when time is limited and cost is a

consideration.<sup>1</sup> No special skills or material are required for its fabrication.<sup>2</sup> The use of stock ocular prosthesis of appropriate contour, size and color can provide an acceptable aesthetic result.

The tissue adaptation of stock prostheses can be improved by making an accurate impression of anophthalmic socket using custom ocular tray. Miller suggested that a custom ocular tray is necessary in certain situations like highly irregular anophthalmic socket or when there is non availability of stock trays.<sup>2</sup>

**Case Report**

A female patient aged 45 years reported to the department of Prosthodontics, Pravara insitiute of medical sciences, Rural dental college, LONI, with a chief complaint of missing right eye. She gave a history of traumatic injury to the right eye in his childhood. On examination, intraocular tissue bed was healthy and with

adequate depth between the upper and lower fornices for retention of the prosthesis.

[Figure 1] - Shows the technique used to fabricate custom ocular tray.

### Technique

A prefabricated stock eye that optimally fits the socket was selected. It was disinfected, lubricated and tissue side of the stock eye was invested with dental plaster (type 2, Goldstone, Asian chemicals, Gujarat, India) to the height of contour [Figure 2].

After the plaster was set, notches were made on the edges. A small amount of polyvinyl siloxane putty (Aquasil, soft putty, Dentsply, Germany) was mixed and adapted over the top of invested prosthesis and into the notched edges. After the putty was set, it was removed and a beveled sprue hole was made in the center of PVS cope. The prosthesis was removed from the mold, plaster surface was lubricated and putty cope was replaced on the mold.

Self cure clear acrylic (DPI RR cold cure; Bombay Burma Trading Corp. Ltd.) was mixed and poured into mold space [Figure 3],

Once it was cured, the acrylic resin tray was removed from the mold and multiple perforations of three to four mm diameter were made in a tray and it was trimmed and polished.

The tube to inject impression material was fabricated by cutting the tip of syringe by about 10mm and it was secured to the ocular tray with cold cure acrylic resin [Figure 4]. The custom tray was disinfected and it was tried in patient for over extension and proper orientation [Figure 5].

### Impression Procedure

The impression tray was placed in the socket and the syringe was loaded with low viscosity poly-vinyl siloxane (Reprosil, Type 1, Dentsply, Germany)

The impression material was injected into the tray and patient was instructed to perform all the movements of the eye [Figure 6].

After removal from the eye socket, the impression was invested first with dental stone (type 3, Goldstone, Asian chemicals, Gujarat, India) till the height of contour and then with dental plaster to get two-piece mold [Figure 8]. After this Wax pattern was obtained.(figure 9).Wax Pattern try – in was done .(figure 10). EYE Centreing was done with the help of grid.(Figure 10)

Stock eye was selected that matched the sclera and iris-pupil complex of the contra-lateral natural eye and it was trimmed precisely until it accurately fits onto the wax pattern.

The bulge of the eye was gained as of the contra-lateral eye by the addition of wax onto the tissue surface [Figure 9].

Once the correct bulge was obtained (figure- 11), the wax pattern was lined with light body rubber base impression material & placed into the socket to record the functional movements of the eye.(figure - 12);

The wax pattern with eye shell invested, dewaxed and packed with heat cure clear acrylic resin (DPI RR Heat cure; Bombay Burma Trading Corp. Ltd.). [Figure 13]

The entire assembly was cured in 70°C water bath for one-and-a-half hours followed by 100° c water bath for 20 to 30 minutes.<sup>4</sup>

After the flask was cooled, prosthesis was separated from the investment and it was polished. The polished prosthesis must be free of roughness that could irritate the eye socket and encourage secretions to accumulate for additional irritation ( figure- 14).

Prior to insertion of the polished prosthesis, it was disinfected in a solution of 0.5% chlorhexidine and 70% isopropyl alcohol for five minutes. After disinfection, the prosthesis was rinsed in sterile saline solution to avoid

chemical irritation. Finally THE Prosthesis was placed & the results were excellent .(figure - 15)

### Discussion

The custom ocular tray is based on the patient's existing anatomy, and therefore conforms accurately to the socket and helps in obtaining accurate impression of the eye socket.<sup>2</sup> This results in intimate adaptation of the stock eye prostheses to internal tissue surface of the socket.

Beumer et al. state that a prefabricated resin eye should not be used in eviscerated sockets because intimate contact between the ocular prosthesis and tissue bed is needed to distribute pressure equally. This is true if a prefabricated is selected and ground to close fit. However when prosthesis is customized to the patient using proper impression technique, distribution of pressure will be equal to.<sup>4</sup> In addition, intimate adaptation of the modified prosthesis to the tissue surface of the defect increases the movement of the prosthesis and enhances its natural appearance [Figure 15].<sup>4</sup>

### Conclusion

A technique for the fabrication of custom ocular tray and impression procedure using the same has been described. This technique permits the finished ocular prosthesis to generate an equal distribution of pressure throughout the defect and intimate adaptation of the prosthesis to tissue surface of the defect.

A well-made, properly planned and functionally molded stock eye prosthesis maintains its orientation when patient performs various eye movements. It give; great psychological benefit and restores the cosmetic appearance of the patient.

### References

1. Cain JR. Custom ocular prosthetics. J Prosthet Dent 1982;48:690.
2. Mathews MF, Smith RM, Sutton AJ, Hudson R. The Ocular Impression: A Review of the Literature and

Presentation of an Alternate Technique. J Prosthodont 2000;9:210-6.

3. Ow RK, Amrith S. Ocular prosthetics: Use of a tissue conditioner material to modify a stock ocular prosthesis. J Prosthet Dent 1997;78:218-22.
4. Taicher S, Steinberg HM, Tubiana I, Sela M. Modified Stock-eye Prosthesis. J Prosthet Dent 1985;54:9S

### Illustrations and Legends

Fig.1.Pre –operative right side ocular defect.



Fig.2. Invested stock eye & putty cope.

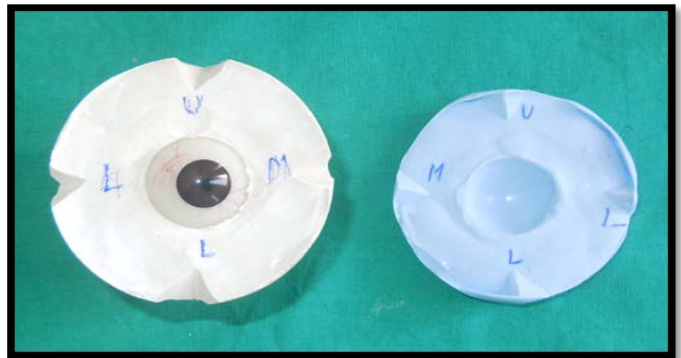


Fig. 3. Mold Space filled with Chemical




Fig. 4. Ocular tray screwed into syringe barrel.

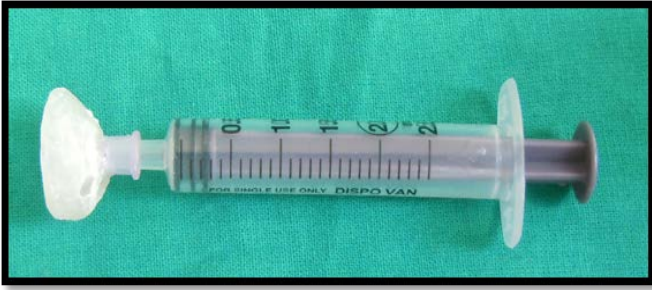

Fig. 5. Ocular tray tried in patient for proper extensions.

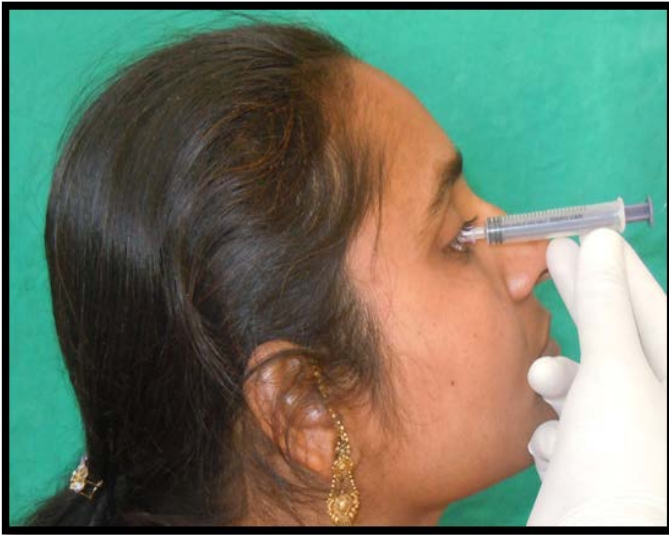

Fig. 6 Ocular impression made using light body impression material.

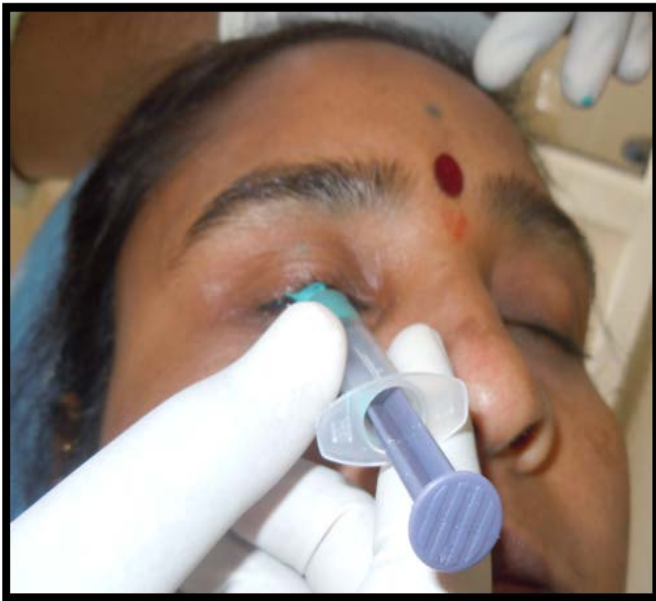

Fig 7 .Ocular impression.



Fig 8.Two piece mold.

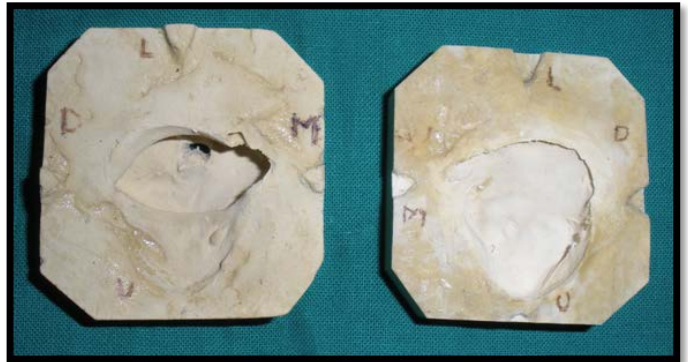


Fig 9.Wax pattern retrieved

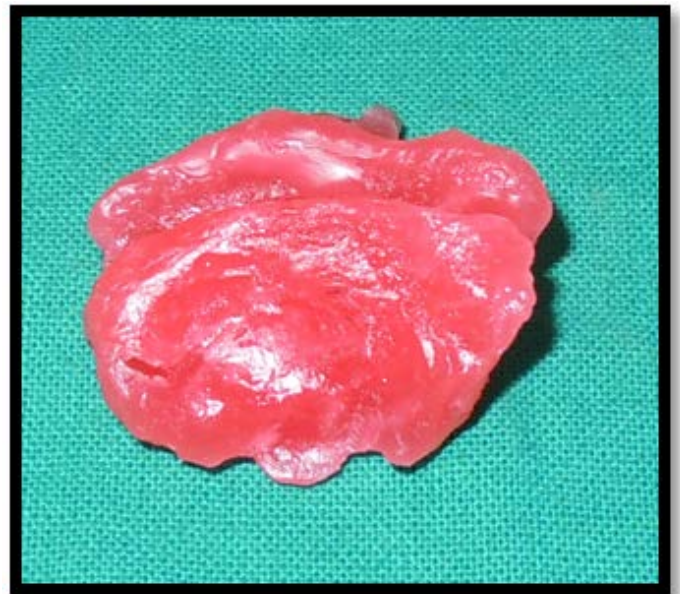

Fig 10 Wax pattern tried for eye shell centring with the help of grid .

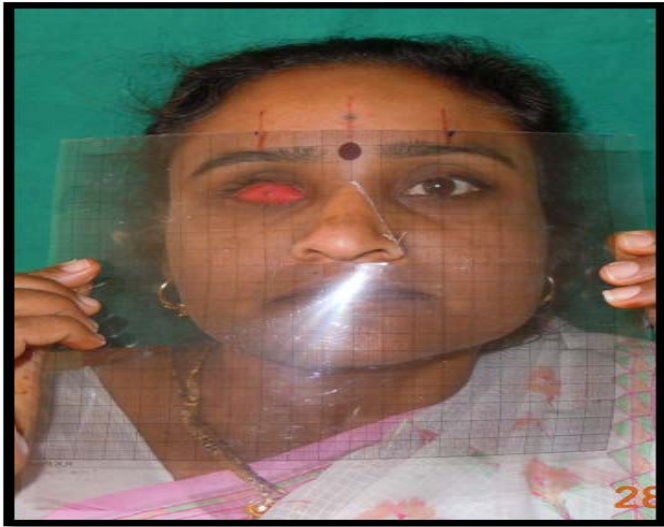

Fig 13. Investing of the waxpattern with eyeshell



Fig 11.Wax pattern with eye shell try-in done.



Fig 14.Final prosthesis.



Fig 12 .Wax Pattern with final impression.

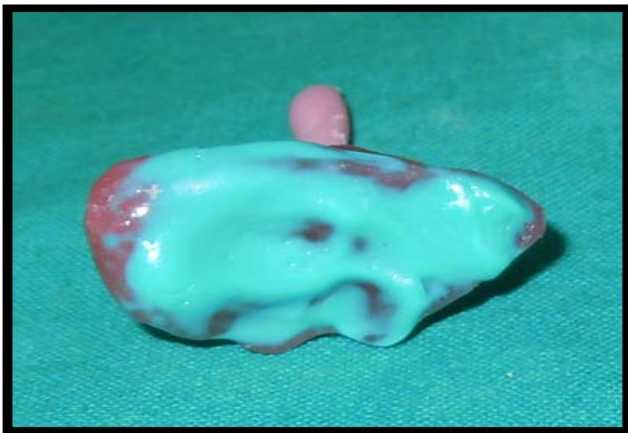

Fig.15.Prosthesis in Situ.

