

A Comparative Evaluation of Efficacy of Potassium Oxalate and Diode Laser in Treatment of Dentinal Hypersensitivity

Shubhangi Gupta Law¹, Aditya Law², Manvi Chandra Agarwal³

¹Shubhangi Gupta Law (MDS Periodontics), Senior Lecturer, Department of Periodontics, KSD Jain Dental College, Kolkata.

²Aditya Law (MDS Periodontics), Senior Lecturer, Department of Periodontics, KSD Jain Dental College, Kolkata.

³Manvi Chandra Agarwal (MDS Periodontics, Professor), Department of Periodontics, Institute of Dental Sciences, Bareilly.

Corresponding Author: Shubhangi Gupta Law, MDS Periodontics, Senior Lecturer, Department of Periodontics, KSD Jain Dental College, Kolkata.

Type of Publication: Original Research Paper

Conflicts of Interest: Nil

Abstract

Purpose: Dentinal hypersensitivity (DH) is one of the most common dental problems with no definitive treatment till date. The aim of the present study is to compare the efficacy of new agents like 27% potassium oxalate gel and diode laser in the treatment of DH.

Method: In this in-vivo randomized clinical trial (RCT), 50 patients were selected. Two sites were selected per patient. On one site, 27% potassium oxalate gel was applied for 90 seconds and the other site was irradiated by diode laser (970nm, 0.5W) for 45seconds. Sensitivity was measured immediately upon application, followed by 15 minutes, 30 minutes, 1 week, 2 weeks, and 1 month.

Results: Reduction in DH was seen in both groups equally.

Conclusion: Both the agents are equally effective in reduction of DH.

Keywords: dentinal hypersensitivity, potassium oxalate, diode laser, sensitivity.

Introduction

DH is defined as:

“A short, sharp pain arising from exposed dentin in response to stimuli, typically thermal, evaporative, tactile, osmotic or chemical and which cannot be ascribed to any other dental defect or pathology”¹.

Among patients with gingival recession, its frequency is considerably higher (60%-98%) due to root exposure.^{2, 3, 4} DH can present at any age, with the majority of patients aged between 20 and 40 years.⁴

DH can occur from various sources, such as structural loss by attrition, abrasion, abfraction, and erosion. The role of plaque in the etiology of DH is unknown but it can play an indirect role through its effect on periodontal tissues.^{4,5}

Different modalities of treatment have shown diverse results. The present study is focused upon the comparative evaluation of two modes of treatment, diode laser, and 27% potassium oxalate, for the reduction of DH.

Method

The present study was designed as a randomized controlled trial and a double-blind study for a period of 1 month. The study was approved by the Ethical Committee on Human/Animal subject research,

Kothiwal Dental College and Research Centre, Moradabad (KDCRC/ETH/PERIO/2013/05). The protocol of the study was thoroughly explained to the patient and written consent was obtained.

A total of 50 subjects were selected, belonging to the age group of 30-50 years, with DH to at least two stimuli (tactile, cold, evaporative), a VAS score of 3 or higher, and a VRS score of 2 or higher; from the Department of Periodontics and Oral Implantology, Kothiwal Dental College and Research Centre, Moradabad. Each patient had a minimum of 2 teeth with DH in different quadrants. Any tooth with dentin exposure due to gingival recession or any wasting disease (attrition, abrasion, erosion) was selected.

Patients who had any systemic disease, or were undergoing treatment of hypersensitivity already, or had a history of periodontal surgery on the hypersensitive tooth in the preceding 6 months, or had any clinical evidence of caries or restorations on the hypersensitive tooth; were all excluded from the study.

To assess DH, three types of stimuli were used:

1. Tactile stimulus

A no. 23 dental explorer was drawn 4-5 times across the affected area of each tooth at a constant force (~ 10gm) as measured by the digital balance (Fig. no.1) by the same investigator at every interval (Fig. no. 2).



Fig 1: Measurement of tactile force by digital balance

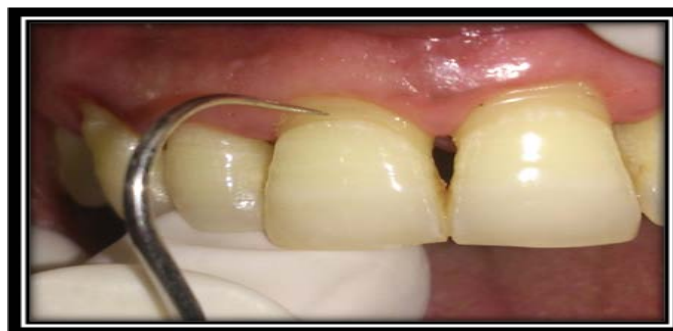

Fig 2: Evaluation of DH using tactile method

2. Evaporative stimulus

The affected tooth was isolated with cotton rolls. The investigator directed a blast of air (pressure maintained at 30 psi) from the same three-way syringe onto the affected tooth for 1 second, keeping the nozzle of the syringe perpendicular and 1cm away (measured using a metal scale) from exposed dentin surface (Fig. no. 3).

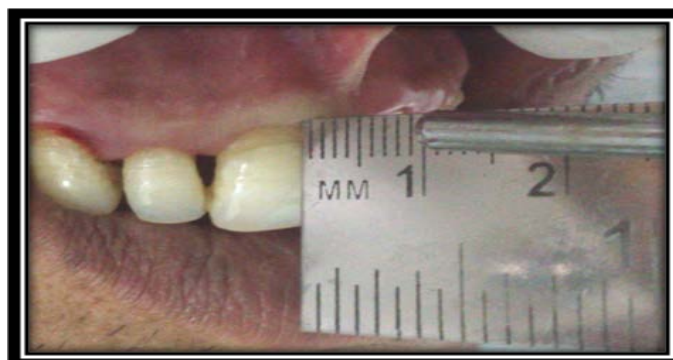

Fig 3: Evaluation of DH using air stimulus

3. Cold stimulus

An ice cube was applied on the affected tooth surface for 10 seconds (Fig. no. 4).

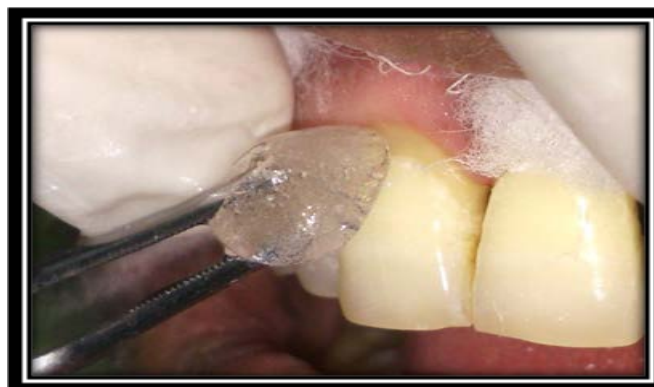

Fig 4- Application of cold stimulus to evaluate DH

An interval of 5 minutes was given between the applications of each stimulus⁶ and the patient's subjective answer was recorded using the VAS⁷ (Fig. No. 5) and VRS⁸ (Table 1).

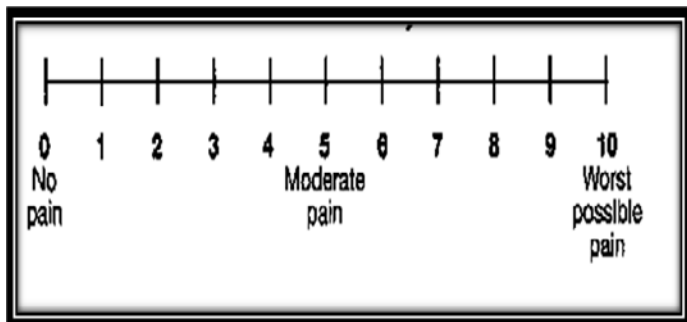


Fig 5- Representation of VAS⁷

Score	Response
0	No discomfort, but patient felt stimulus
1	Slight discomfort, but not painful
2	Painful during application of stimulus
3	Painful during application of stimulus and immediately afterwards

Randomization of the selected site was done using the 'chit-picking method'.

The first hypersensitive tooth from one quadrant was isolated and potassium oxalate gel (27% potassium oxalate, desensitizer, Prime Dental Products, India) was applied on the affected area (supra-gingivally) for 90 seconds using an applicator tip (Fig. No. 6). The gel was then washed off with water.

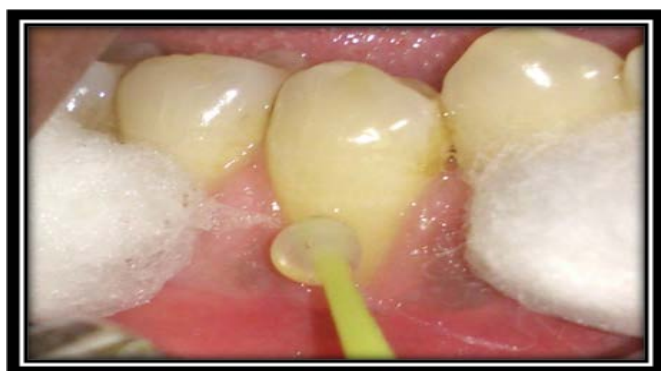

Fig 6- Application of potassium oxalate gel

Another hypersensitive tooth from a different quadrant was subjected to the energy beam of the diode laser (wavelength 970 nm, Fona™, Sirona Dental System, Germany) for 45 seconds (0.5W). It was directed perpendicular to the exposed dentinal surface in non-contact mode, 1mm away from the tooth surface. The distance was measured with the help of a periodontal probe (Figure no. 7).

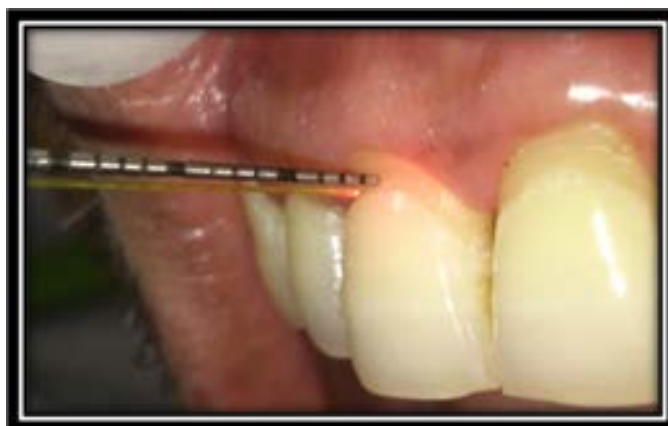

Fig 7- Irradiation of the site by diode laser

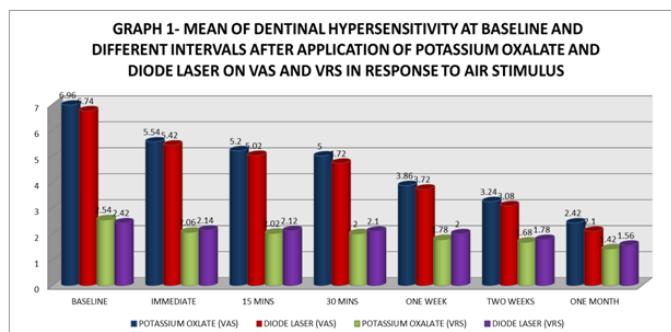
DH was recorded immediately, 15 mins, and 30 mins after the treatment. All three stimuli were used to check for DH. The patients were recalled and further recording was done after 7, 14, and 30 days.

Result

Comparison of DH using different stimuli

Air stimulus

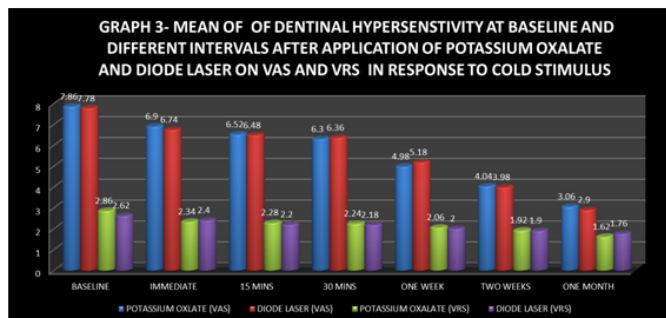
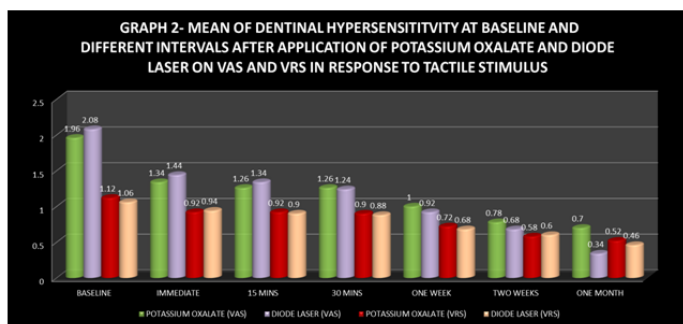
There was a reduction in DH in both groups, on both the scales (Graph no.1)



Tactile stimulus

A reduction in DH was observed in both the groups, on both scales (Graph no 2).

DH decreased in both groups, on both scales (Graph no. 3)



** Statistically significant (p<0.05)

Cold stimulus

Efficacy of Potassium Oxalate

The application of potassium oxalate gel had a good response in the reduction of DH. (Table no.5).

Table No. 2- Efficacy of potassium oxalate in reduction of DH in response to the stimuli

Intervals	VAS						VRS					
	AIR		TACTILE		COLD		AIR		TACTILE		COLD	
	MD±SD	P	MD±SD	p	MD±SD	p	MD±SD	p	MD±SD	p	MD±SD	p
BL- IMM	1.42±1.26	.000*	0.62±1.18	.001*	0.96±1.18	.000*	0.48±0.58	.000*	0.20±0.45	.003*	0.34±0.48	.000*
BL- 15MIN	1.76±1.61	.000*	0.70±1.18	.000*	1.34±1.53	.000*	0.52±0.58	.000*	0.20±0.45	.003*	0.4±0.49	.000*
BL- 30MIN	1.96±1.69	.000*	0.70±1.8	.000*	1.56±1.64	.000*	0.54±0.58	.000*	0.22±0.47	.002*	0.44±0.50	.000*
BL- 1 W	3.1±1.76	.000*	0.96±1.36	.000*	2.88±1.56	.000*	0.76±0.62 5	.000*	0.40±0.67	.000*	0.62±0.53	.000*
BL-2W	3.72±2.04	.000*	1.18±1.51	.000*	3.82±1.47	.000*	0.86±0.64	.000*	0.54±0.86	.000*	0.76±0.56	.000*
BL-1M	4.54±2.06	.000*	1.26±1.59	.000*	4.8±1.8	.000*	1.12±0.69	.000*	0.60±0.90	.000*	1.06±0.74	.000*

* Statistically significant (p<0.05)

Efficacy of Diode laser

The application of diode laser also had a splendid response in the reduction of DH. (Table no. 6)

Table No. 3: Efficacy of diode laser in reduction of DH in response to the stimuli

Intervals	VAS						VRS					
	AIR		TACTILE		COLD		AIR		TACTILE		COLD	
	MD ±SD	P	MD±SD	p	MD±SD	p	MD±SD	p	MD±SD	p	MD±SD	p
BL- IMM	1.32±1.36	.000*	0.64±1.08	.001*	1.04±1.25	.000*	0.28±0.5	.000*	0.12±0.39	.032*	0.22±0.42	.001*
BL- 15MIN	1.72±1.31	.000*	0.74±1.14	.000*	1.3±1.31	.000*	0.3±0.54	.000*	0.16±0.42	.010*	0.42±0.5	.000*
BL- 30MIN	2.02±1.38	.000*	0.84±1.22	.000*	1.42±1.5	.000*	0.32±0.55	.000*	0.18±0.44	.005*	0.44±0.50	.000*
BL- 1 W	3.02±1.71	.000*	1.16±1.58	.000*	2.6±1.49	.000*	0.42±0.58	.000*	0.38±0.67	.000*	0.62±0.53	.000*
BL-2W	3.66±1.75	.000*	1.40±1.98	.000*	3.8±1.47	.000*	0.64±0.6	.000*	0.46±0.76	.000*	0.72±0.5	.000*
BL-1M	4.64±1.98	.000*	1.54±2.06	.000*	4.88±1.91	.000*	0.86±0.64	.000*	0.60±0.83	.000*	0.86±0.54	.000*

* Statistically significant ($p < 0.05$).

Discussion

Clinically, in some subjects the immediate response to the reduction of DH after application of 27% potassium oxalate gel was comparatively better than that of the diode laser, but effect was longer appreciated on sites irradiated with diode laser. Statistically the results were insignificant as not all the subjects reported the same degree of reduction in DH. The immediate relief obtained with potassium oxalate was due to its neural action i.e a high concentration of topically applied potassium oxalate increases the extracellular concentration of potassium around the nerves upto levels sufficient to inactivate nerve terminals.^{11,12} This immediate relief obtained is similar to the findings of Vieira et al.¹³ and Pereira et al.¹⁴ At 15 minutes and 30 minutes interval, the mean difference was observed to be further increased showing a further reduction in DH. This may be due a greater concentration of potassium that was formed and maintained around the nerves since a higher concentration of potassium oxalate was used in the study compared to the other studies. After one week, the degree of hypersensitivity was lower when compared to the reading taken at 30 minutes interval. This can be explained by the large amount of insoluble calcium oxalate crystals which are formed by the reaction of potassium oxalate and calcium present in the dentin and in dentinal fluid. These calcium oxalate crystals are relatively big measuring about 1-2 μ m in diameter, which coincides with the mean diameter of the dentinal tubules (0.9-2.5 μ m), thus effectively occluding the dentinal tubules.¹⁵

The present study also proved Diode laser to be equally effective in the reduction of DH. It has been observed that, in the long term, diode laser acts at a cellular level, increasing the cellular respiration with the production of energy (ATP), thus increasing the production of tertiary

dentin and consequently sealing the dentinal tubules.^{16,17}

With the use of laser during the follow up periods, no detrimental pulpal effects, allergic reactions or clinically detectable complications were observed.^{9,10}

Conclusion

A single, separate use of both the agents are equally effective in decreasing DH (observed till 1 month).

References

1. Gilliam DG, Orchardson R. Advances in the treatment of root dentin sensitivity: mechanisms and treatment principles. *Endodontic Topics* 2006;13:13-33.
2. C.R. Irwin and P. McCusker. Prevalence of dentine hypersensitivity in a general dental population. *J Ir Dent Assoc* 1997; 43(1): 7-9.
3. J. S. Rees and M. Addy. A cross-sectional study of dentine hypersensitivity. *Journal of Clinical Periodontology* 2002; 29(11): 997-1003.
4. M. B. Chabanski, D. G. Gillam, J. S. Bulman and H. N. Newman. The prevalence, distribution and severity of cervical dentine sensitivity (CDS) in a population of patients referred to a specialist Periodontology department. *Journal of Clinical Periodontology* 1996; 23: 989-992.
5. Brannstrom M. Sensitivity of dentin. *Oral Surg* 1966;21: 517-526.
6. Wewers ME, Lowe NK. A critical review of visual analogue scales in the measurement of clinical phenomena. *Res Nurse Health* 1990; 13(4):227-236.
7. Schiff T, Santos MD, Laffi S, et al. Efficacy of a dentifrice containing 5% potassium nitrate and 1500 ppm sodium monofluorophosphate in a precipitated calcium carbonate base on dentinal hypersensitivity. *J Clin Dent* 1998; 9(1):22-5.
8. R.G Landry and R Voyer. The treatment of hypersensitive dentin: A retrospective and comparative

approaches. Journal of the Canadian Dental Association 1990; 56:1035-1041.

9. Silica A et al. Immediate efficacy of diode laser application in the treatment of dentine hypersensitivity in periodontal maintainance: a randomized clinical trial. J Clin Periodontol 2009; 36: 650-660.

10. Hashim N T et al. Effect of clinical application of the diode laser (810nm) in the treatment of dentine hypersensitivity. BMC Research Notes 2014; 7: 1-4.

11. Markowitz K, Kim S. The effects of various ionic solutions on pulpal nerve sensitivity. J Dent Res 1985; 64: 309.

12. Pashley DH, Andringa HJ, Eichmiller F. Effects of ferric and aluminium oxalates on dentin permeability. Amer J Dent 1991; 4(3): 123-126.

13. Vieira et al. Clinical evaluation of 3% Potassium oxalate gel and a GaAlAs laser for the treatment of dentinal hypersensitivity. Photo Med Laser Surg 2009; 25(5): 807-812.

14. Pereira JC, Martineli ACBF, Santiago SL. Treating hypersensitive dentin with three different potassium oxalate based gel formulations: A clinical study. Rev Fac Odontol Bauru 2001; 9:123-130.

15. Garberoglio R, Brannstrom M. Scanning electron microscope investigation of human dentine tubules. Arch oral Biol 1976; 21(6): 355-62.

16. Gerschman JA, Rubin J, Gebart-Eaglemort J. Low-level laser therapy goes dentinal tooth hypersensitivity. Aust Dent J 1994; 39: 353-357.

17. Karu T. Molecular mechanism of the therapeutic effect of low level laser irradiation. Laser Life Sci 1988; 2: 53-74.