

**PRF: From You for You: A Changing Era in Dentistry**

<sup>1</sup>Dr. Vidyasagar Mopagar, HOD Professor, Dept of Pedodontics, Rural Dental College, Loni.

<sup>2</sup>Dr. Chirag Sankhe, Post graduate Student, Rural Dental College, Loni

<sup>3</sup>Dr Asha Nara, Associate Professor, Rural Dental College, Loni

<sup>4</sup>Dr. Sourabh Joshi, Associate Professor, Rural Dental College, Loni.

<sup>5</sup>Dr Meghna Padubidri, Senior Lecturer, Rural Dental College, Loni..

<sup>6</sup>Dr Amit Padmai, Department of Conservative and Endodontics, TKDC Kolhapur.

**Corresponding Author:** Dr. Chirag Sankhe, Post graduate Student, Rural Dental College, Loni

**Type of Publication:** Original Research Paper

**Conflicts of Interest:** Nil

**Abstract**

Tissue regeneration is a thought-provoking area in the field of dentistry. In addition to its role in regular haemostasis, platelets have been proven to be a good source of growth factors. offers an Enhanced healing of hard and soft tissues is offered by autologous concentrate of bloodplatelets with a suspension of growth factors. This has led to the evolutionof platelet concentrates categorized as first-generation plateletconcentrates such as platelet rich plasma (PRP) and secondgeneration such as platelet rich fibrin (PRF).

Platelet Rich Fibrin (PRF) has been shown to have several advantages over traditionally prepared Platelet Rich Plasma (PRP) as it offers a better haemostasis with minimal risks since there isn't any use of anyanticoagulants.

This simplified and cost-effective process has various applications in dentistry such as root coverage periodontal surgical procedures, enhancement of osseointegration of implants, regeneration of pulp tissue in endodontics, paediatric pulp capping procedures, healing of extraction pockets, sinus lift procedures, etc.

**Introduction**

Healing is a complex process, which involves cellular organization, chemical signals, and the extracellular matrix for tissue repair.<sup>1</sup>The understanding of healing process is still incomplete, but it is well known that platelets play an important role in both haemostasis and wound healing processes.<sup>2</sup>

Regenerative potential of platelets was introduced in the 70's, when it was observed that they contain growth factors that are responsible for increase collagen production, cell mitosis, blood vessels growth, recruitment of other cells that migrate to the site of injury, and cell differentiation induction, among others.<sup>3</sup>

PRF was first used by Choukroun et al, which consists of a matrix of autologous fibrin and has several advantages over PRP, including easier preparation and not requiring chemical manipulation of the blood, which makes it strictly an autologous preparation.<sup>4</sup>

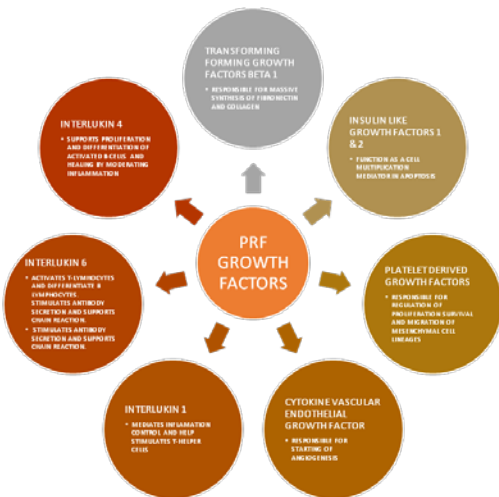
The following review attempts to summarize the relevant literature regarding the various types of stem cell sources that have been identified, focusing on its preparation, the technique of using platelet rich fibrin (PRF), clinical applications in dentistry, its advantages and disadvantages.

### What Is PRF....?

Choukroun’s platelet-rich fibrin (PRF) is a biomaterial with a distinct arrangement and three dimensional frameworks.<sup>456</sup> It is observed to have a packed fibrin complex, containing leukocytes, cytokines and glycoproteins such as thrombospondin <sup>7</sup>.

Leukocytes that are condensed in PRF scaffold hold a necessary position in growth factor release along with immune administration. It also constitutes growth factors, such as transforming growth factor b, platelet derived growth factors, vascular endothelial growth factor, etc. which hold a critical role in the functioning of PRF in regeneration and wound healing <sup>8</sup>.

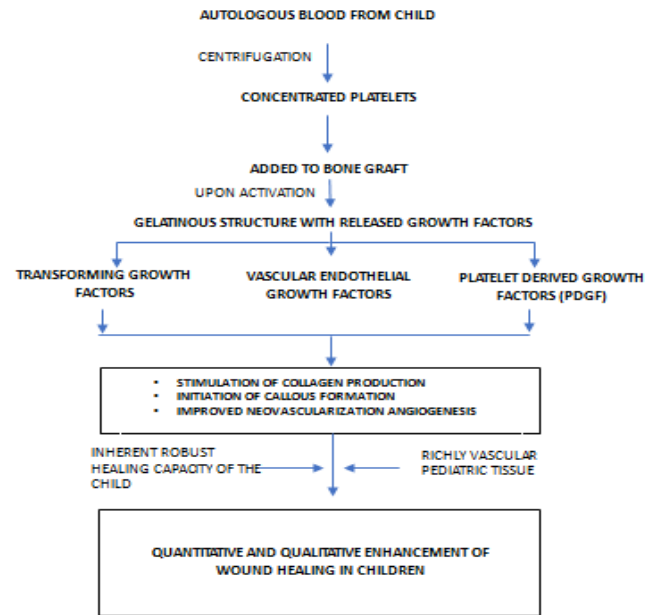
### Growth factors from PRF and their role<sup>9</sup>



### PRF Preparation

The protocol was developed using a simple centrifugation protocol requiring only 1 cycle of 12 minutes at 2700 rpm (750 g). The original objective was to spin at high centrifugation speeds in order to phase separate the layers between the red corpuscle base and the overlying clear liquid containing leukocytes and plasma. As no anticoagulants were utilized, the resultant formulation came with a three-dimensional fibrin scaffold termed PRF.<sup>10</sup>

### Fundamental Mechanism of Action of PRF in Children



### Pulp Capping

Platelet Rich fibrin could be an effective material used for direct pulp capping due to its excellent wound healing, tissue regeneration & osteogenic properties. Many researchers have proven that pulp tissue contains highly proliferative and clonogenic population of progenitor/stem cells which can differentiate into hard tissue forming cells on injury.<sup>11</sup>

Pulp Capping in carious teeth can be unpredictable, therefore case selection can be an important criterion.<sup>12</sup>

Tikku PA in his comparative study randomly allocated 45 patients into three treatment groups (n=15). Group 1 = Direct pulp capping using calcium hydroxide. Group 2 = MTA. Group 3 = MTA along with PRF. Clinical and radiographic evaluation was done every month for 6 months. Teeth were clinically evaluated for any colour change in coronal area of tooth, status of pulp vitality, presence of periodontal inflammation, presence of sinus, swelling and mobility. Radiographic evaluation was done by measuring increase in the radiographic density below the exposure site and data obtained was statistically evaluated.

The combined use of PRF and MTA can be considered as more effective direct pulp capping material than calcium hydroxide and mineral trioxide aggregate used separately.<sup>13</sup>

Bakshi C et al performed direct pulp capping with PRF. After clinical and radiographic examination one case with irreversible pulpitis and other case with chronic pulpitis in young patients were selected. Following caries excavation and haemorrhage control the exposure was covered with PRF followed by placing MTA on top of it. The remaining tooth was sealed with a layer of light cure GIC followed by composite resin restoration.

At 1-day follow-up, patient's spontaneous symptoms had resolved. 6-months follow-up demonstrated pulp vitality, clinical function, as well as the absence of pain/tenderness to percussion/palpation/cold sensitivity tests; periapical radiograph showed normal periodontium.

Bakshi C et al stated that PRF shows promising result in case of irreversible pulpitis and may be a good treatment option in comparison to endodontic treatment<sup>14</sup>

### **Pulpotomy**

The use of formocresol as a pulpotomy agent has major disadvantages like cytotoxicity and mutagenicity.

Platelet Rich fibrin with its low toxic effects and increased tissue regeneration showed excellent clinical results. Hellig et al<sup>15</sup> in 1984, and Waterhouse<sup>16</sup> in 2000 gave the criterion for tooth selection in pulpotomy using Platelet Rich Fibrin. The clinical criteria for selection included absence of excessive tooth mobility, absence of tenderness to percussion, and absence of gross decay and tooth destruction that would preclude its restorability.

A study conducted by Damle et al<sup>17</sup> in 2004 compared PRF and Calcium Hydroxide and found 100% success rate with Platelet Rich Fibrin, in which, fifty- six primary molar were treated by PRF and another 28 by calcium hydroxide.

Another study with Nagasaki et al<sup>18</sup> in 2007 compared PRF vs Hydroxyapatite crystals. In this study, Plasma membrane-associated cation-binding protein 1PCAP1 was associated with the plasma membrane under natural conditions and was released from the membrane at high concentrations of Ca<sup>2+</sup> or Mg<sup>2+</sup> in vitro. These results suggest that the hydrophilic protein PCaP1 binds Ca<sup>2+</sup> and other cations and is stably associated with the plasma membrane, which proved that PRF was much superior to calcium hydroxyapatite crystals.

Keswani D et al showed that PRF could be used as a suitable biological and economic alternative to MTA in pulpotomy procedures of permanent teeth with incomplete root development.<sup>19</sup>

Patidar Surendra et al<sup>20</sup> conducted a study to observe the radiographic and clinical outcome in MTA pulpotomy versus the PRF group. In this study, a total of 50 primary molars in fifty children of both genders age 5–9 years (mean age-6.8 years), follow-up evaluation was done after 1, 3, and 6 months.

At 1 and 3 months there was no clinical finding observed in both groups. After 6 months, 4 primary molars were lost to follow-up and a total of 23 patients in each group were available for clinical and radiological follow-up. The pain was noted in 4.3% of primary teeth in both the groups while mobility was noticed only in MTA group in only 4.34% of teeth whereas 4.34% of teeth in PRF group showed sign of tenderness on percussion. At 6-month follow-up, the clinical assessment showed 92% success rate in both groups. Overall radiographic success rate was 87% for PRF group whereas for MTA group it was 92%. This study showed that PRF held a promising future in the area of pulpotomy.

### **Apexogenesis**

Apexogenesis takes place due to the regenerative properties of the pulpal reserve of cells.

Huang *et al*, in his study concluded that the PRF led to increased proliferation of human Dental Pulp Cells and expression of osteoprotegerin (OPG) and alkaline phosphatase (ALP) activity.<sup>21</sup> Some amounts of human dental pulp cells present in the apical papilla usually remain vital even in case of a large periapical lesion. After the regression of the inflammation and under the influence of Hartwig's Epithelial Root Sheath, these Dental Pulp Cells differentiate into odontoblasts like cells.

6 healthy volunteers were chosen for PRF samples. Human dental pulp cells (DPCs) were derived from healthy individuals undergoing extraction for third molars. Colorimetric assay was used to check cell proliferation. Western blot was used to evaluate the expression of osteoprotegerin (OPG). Alkaline phosphatase (ALP) activity was examined by substrate assay.

This showed that OPG and ALP expression were to be regarded as markers of odontoblastic differentiation.

### **Apexification**

Apexification is a method of inducing apical closure through the formation of mineralized tissue in the apical region of a nonvital tooth with an incompletely formed root (open apex).<sup>22</sup> A wide array of materials have been used for apexification including calcium hydroxide, magnesium oxide, barium hydroxide, zinc oxide, calcium oxide, calcium phosphate collagen gel, tricalcium phosphate and other pastes.

Calcium hydroxide is the most commonly advocated material for apexification, with long history of clinical success<sup>23,24,25</sup>. The disadvantages include prolonged treatment time, need for multiple visits and radiographs, difficulty of the patient's recall management and increase in the risk of root fracture after dressing with calcium hydroxide for extended periods.<sup>26</sup>

An alternative to calcium hydroxide apexification is a one-step apexification technique using mineral trioxide aggregate (MTA) as an artificial barrier.

Platelet rich fibrin (PRF) can be used as a resorbable matrix material against which MTA apical barrier can be placed. PRF membrane has a soft consistency and it inherently contains some amount of moisture, still it serves as a good matrix material for placement of MTA. This is because MTA has a wet sand like consistency and can be placed without pressure application and therefore it does not require a pressure-resistant matrix for application. Moreover, MTA sets in the presence of moisture and does not require a moisture-free environment.

Another advantage of using PRF as a matrix is that it promotes wound healing and repair.<sup>10</sup>

Shivashankar et al reported that revitalization was possible in necrotic immature teeth after thorough disinfection of root canal system using PRF.<sup>27</sup>

Khanduri N and Kurup D have presented a successful case describing single-visit apexification using Biodentine, a new calcium silicate-based material as an apical barrier along with platelet-rich fibrin as internal matrix.<sup>28</sup>

### **Extraction Socket**

Socket preservation using biomaterials has been proposed and autologous platelet concentrates including PRP with growth factors and PRF are employed.<sup>29</sup>

Hauser and Gaydarov 2013<sup>30</sup> reported (0.48%) of alveolar bone loss in extraction sockets with PRF without flap elevation compared with (3.68%) in control group at 8 weeks follow up. The authors also reported that significantly higher bone quality in the PRF group.

A study by Simon et al. showed a mean width socket resorption of 0.57 mm (7.38%) with PRF after 4 months and confirmed a significant advantage in the preservation

of post extraction alveolar ridge dimensions with the use of PRF.

Another study was carried out by Simon and Von Hagen 2000 during morphometric tissue experiment in which they planned a socket preservation surgery. It showed new bone generated in only 3 weeks when the preservation procedure was conducted by using PRF only.<sup>31</sup>

From above studies we can conclude that PRF has been shown to have tissue regenerative and wound healing properties. Thus it can be an effective medium for helping in natural clot formation and initiate rapid healing by increased re-vascularization and reepithelization, it can also help in faster osteogenesis.

### **Facial aesthetics**

The use of PRF has been utilized for a variety of aesthetic procedures in medicine that focuses on improving cosmetic appearance through the treatment of conditions including scars, skin laxity and wrinkles. While various surgical procedures have been utilized, the main aim has been to improve the patient self-esteem by providing better quality of life, psychological well-being, and social function to patients and with the advancements made in PRF therapy, it is now possible to do so in a natural way.<sup>32</sup> PRF (1300 rpm for 8 min) or i-PRF (700 rpm for 3 min) has therefore been utilized in practice during combination therapies to enhance aesthetic outcomes and improve patient wound healing.<sup>33</sup>

When preparing for regeneration with PRF, the treating physician must first look at the skin's anatomy including facial lines, wrinkles, and folds to determine the depth of damage to the skin to evaluate the optimal choice of procedure to obtain desired end goals.

When performing lip augmentation and contouring, i-PRF is utilized in combination with PRF to contour the lips. If scars are present, PRF is implanted underneath the scar in order to use the fibrin matrix to bulk the lost tissues and to

create a micro-environment capable of slowly releasing growth factors over an extended period of time.

The PRF is able to provide more volume, whereas the i-PRF provides more leukocytes and a higher concentration of growth factors per volume.<sup>34</sup>

### **Sinus lift procedures**

Sinus floor elevation procedures are highly effective yet not free of complications. Complications associated with sinus floor elevation include graft resorption, membrane perforation, or sinusitis.

Two studies were undertaken in which PRF was used for sinus lift procedure in which implant survival rate was 100% after a 1 year<sup>35</sup> and 3-year follow-up<sup>36</sup>, regardless of PRF. These two studies combined PRF with deproteinized bovine bone mineral DBBM. In addition, PRF did not change bone formation, soft tissue area, resorption of residual bone grafts, and the augmented bone height. The studies did not report on membrane perforations and sinusitis, precluding any conclusion about its potential benefit in the management of complications.<sup>35,36</sup>

Although in vitro and preclinical data encourage the use of PRF in sinus floor elevation, the clinical evidence gathered so far does not support its use<sup>37</sup>.

Choukroun *et al.*, attempted to evaluate the potential of PRF in combination with freeze-dried bone allograft (FDBA) in sinus floor elevation to enhance bone regeneration. Nine sinus floor augmentations were performed. Out of nine; in six sites, FDBA with PRF (test group), and in three sites FDBA without PRF (control group) was used. After healing period of 4 months, identical histologic maturation was seen in both test and control group, which was for a period of 8 months with equivalent quantities for both protocols.<sup>4</sup>

Aoki *et al.* has reported two cases with histological evaluations of PRF after the sinus augmentation

surgery. They found that the use of PRF as a graft material during sinus floor augmentation induces natural bone regeneration.<sup>38</sup>

Sherifali et al studied the efficacy of platelet-rich fibrin (PRF) on maxillary sinus augmentation. They concluded that addition of PRF to demineralized freeze-dried bone allograft DFDBA accelerates graft maturation and decreases the healing period before implant placement. Conversely, it has no beneficial effect on graft maturation.<sup>39</sup>

M.C. Fernandez et al conducted study on clinical and radiological behaviour after immediate implant placements after sinus lift when PRF and bone grafting was used in atrophic maxilla. They found that the use of PRF is useful because it promotes wound healing, growth and bone maturation, stabilization of the graft, the wound closure and hemostasis.<sup>40</sup>

Mazoret *al.* stated that PRF led to stabilization of regenerated bone in the subsinus cavity up to the tip of implants during a simultaneous sinus lift and implantation procedure. This was recorded in a case series through a radiological and histological evaluation at 6 months from the surgery. Also they advocated that Choukroun's PRF, as an acceptable option.<sup>41</sup>

In summary, inconclusive results are reported on PRF in sinus floor elevation procedures whereby a lack of well-designed studies with appropriate endpoints are needed. Therefore, the effect of PRF on bone regeneration during sinus floor elevation remains questionable.

## Periodontology

### Bone Reconstruction And Root Coverage

Simonpieriet *al.* reported and confirmed the validate usage of PRF membranes in reconstruction protocols along with FDBA, 0.5% metronidazole solution in about 20 patients who were treated using this new technique and followed-up during 1-5 years. No implant or graft loss was seen after

placement of 184 dental implants. PRF membranes protect the surgical site; promote soft tissue healing; and when its fragments mix with graft material, it functions as a "biological connector" between the different elements of graft and acts as a matrix which supports neoangiogenesis, capture of stem cells, and migration of osteoprogenitor cells to the center of graft.<sup>42,43</sup>

PRF plugs can also be used in treating the residual extraction sockets. Use of autologous PRF in extracted socket filling after immediate bone augmentation using titanium membranes applied to the socket walls. Primary closure with adequate bone filling was found safe after 8 weeks or above for implant fixation.

Anilkumaret *al.*, has reported PRF as a potential novel root coverage approach for treating gingival recession in mandibular anterior teeth using combined laterally positioned flap technique and PRF membrane. Combined use of PRF and bone graft with good results has also been reported for combined periodontic-endodontic furcation defect.<sup>44</sup>

Arocaet *al.*, in the 6 month of their randomized clinical trial, concluded that addition of a PRF membrane positioned under the MCAF (modified coronally advanced flap) provided inferior root coverage, but an additional gain in gingival/mucosal thickness at 6 months compared to conventional therapy.<sup>45</sup>

### Periodontal Regeneration

Following the regenerative outcomes with PRP, several authors began to hypothesize whether PRF, natural platelet concentrate without the use of anti-coagulants, could further improve the outcomes observed with PRP.

There are three main added advantages that further support its use. First, PRF contains a fibrin network that facilitates blood clot formation and tissue repair. Secondly, its growth factor release kinetics have been shown to occur more slowly when compared to PRP, and

therefore regeneration may take place over a more extended period of time. Moreover, PRF contains leukocytes and macrophages, known cell types implicated in immunity and host defense.<sup>8</sup>

Since periodontal defects are the result of invading bacterial pathogens, the inclusion of white blood cells contained within PRF is hypothesized to further act as a bacterial resistant matrix capable of fighting bacterial pathogens.

### **Intrabony defect regeneration**

To date, more than 17 randomized clinical trials (RCTs) have investigated the use of PRF for the repair/regeneration of periodontal intrabony defects. The various RCTs have compared the additional use of PRF to open flap debridement OFD versus OFD alone and have further investigated its use with various biomaterials and/or antibiotics.<sup>46</sup>

Two studies comparing defect healing with PRF versus a bone grafting material (DFDBA) found no significant differences between treatment groups.<sup>47</sup>

Three studies found that the use PRF in combination with a bone-grafting material was superior to either PRF alone, or bone-grafting material alone<sup>48</sup>.

It was similarly found that the supplemental use of PRF in combination with a barrier membrane was superior to barrier membrane alone. Probing pocket depth PPD reductions and Clinical attachment level CAL gains at intrabony defects sites were observed.<sup>49</sup>

In a recent study, the additional use of PRF with enamel matrix derivative(EMD) found no differences between the test and control (EMD alone)groups.<sup>50</sup>

### **Implant**

Reduced bone height and width are the most common limitations for implant placement. To overcome these limitations, guided bone regeneration, alveolar ridge preservation, and sinus floor elevation were introduced.

Even though most of these techniques provide predictable outcomes, there is a demand to enhance wound healing and bone regeneration either after dental extraction or during implant placement.

Five studies related to PRF application during implant placement were included. Two RCTs assessed the impact of PRF prior to implant insertion and reported that PRF might enhance implant stability during the early phase of osseointegration.<sup>51,52</sup>

Another study by Boora et al. 2015, showed less marginal bone loss with the use of PRF. However, this data is limited to implants with a follow up of 3 months.

In a study done by Hehn et al., (2016) no effects on bone loss were observed when a PRF membrane was placed over the implant and they found a decrease in mucosa thickness after 3 months in the PRF group.<sup>54</sup>

A study by Angelo et al., (2015) for implant placement combined with horizontal bone augmentation showed that PRF failed to affect insertion torque.<sup>55</sup>

Overall, due to the heterogeneity of the outcome measures, it is difficult to draw a conclusion from PRF during implant placement.

### **PRF and pain**

Two studies by Marenzi et al., (2015); and Temmerman et al., (2016) on patient reported pain outcomes measured using the visual analogue scale concluded that PRF significantly reduced pain sensations after 3 to 5 days. They noted significantly less pain in the PRF group up to the 21st day. Nevertheless, it has to be taken into account that both studies did not state whether the patients were adequately blinded.<sup>56,57</sup>

There are numerous studies assessing PRF effect on pain with mandibular third molar extraction.<sup>58</sup>

### **Advantages of using PRF**

Some advantages are reported in the literature related to the use of PRF, such as the following:

- Its preparation is a simplified and efficient technique, with centrifugation in a single step, free and openly accessible for all clinicians.
- It is obtained by autologous blood sample.
- Minimized blood manipulation.
- It does not require the addition of external thrombin because polymerization is a completely natural process, without any risk of suffering from an immunological reaction.<sup>1059</sup>
- The natural fibrin framework of PRF with growth factors prolongs its activity for a longer period and stimulate tissue regeneration effectively.
- It can be used solely or in combination with bone grafts, depending on the purpose.
- Increases the healing rate of the grafted bone.
- It is an economical and quick option compared with recombinant growth factors when used in conjunction with bone grafts.
- Used as a membrane, it avoids a donor site surgical procedure and results in a reduction in patient discomfort during the early wound-healing period.
- The studies of PRF present it to be more efficient and with less controversies on its final clinical results when compared to PRP.<sup>60</sup>

#### **Disadvantages of using PRF**

PRF may present some disadvantages as follows:

- The final amount available is low because it is autologous blood.<sup>4</sup>
- The success of the PRF protocol depends directly on the handling, mainly, related to blood collection time and its transference for the centrifuge.<sup>10</sup>
- Need of using a glass-coated tube to achieve clot polymerization.<sup>61</sup>
- Possible refusal of treatment by the puncture required for blood collection.

#### **Conclusion**

The present knowledge confirms the therapeutic qualities of PRF as a biomaterials. However, despite the evident regenerative benefits of PRF, substantiation of its clinical applications is still limited. Consequently, there is a constraint for the rationalization of its use. Additional randomized controlled clinical trials are defensible to test the long-term benefits and ultimate outcomes associated with PRF.

#### **Reference**

1. Singer AJ, Clark RAF. Cutaneous Wound Healing [Internet]. Vol. 341, *New England Journal of Medicine*. 1999. p. 738–46. Available from : <http://dx.doi.org/10.1056/nejm199909023411006>
2. Gassling VLW, Açil Y, Springer IN, Hubert N, Wiltfang J. Platelet-rich plasma and platelet-rich fibrin in human cell culture. *Oral Surg Oral Med Oral Pathol Oral RadiolEndod*. 2009 Jul;108(1):48–55.
3. Ross R, Glomset J, Kariya B, Harker L. A platelet-dependent serum factor that stimulates the proliferation of arterial smooth muscle cells in vitro. *Proc Natl Acad Sci U S A*. 1974 Apr;71(4):1207–10.
4. Choukroun J, Diss A, Simonpieri A, Girard M-O, Schoeffler C, Dohan SL, et al. Platelet-rich fibrin (PRF): a second-generation platelet concentrate. Part V: histologic evaluations of PRF effects on bone allograft maturation in sinus lift. *Oral Surg Oral Med Oral Pathol Oral RadiolEndod*. 2006 Mar;101(3):299–303.
5. Choukroun J, Diss A, Simonpieri A, Girard M-O, Schoeffler C, Dohan SL, et al. Platelet-rich fibrin (PRF): a second-generation platelet concentrate. Part IV: clinical effects on tissue healing. *Oral Surg Oral Med Oral Pathol Oral RadiolEndod*. 2006 Mar;101(3):e56–60.



6. Choukroun J, Ghanaati S. Reduction of relative centrifugation force within injectable platelet-rich-fibrin (PRF) concentrates advances patients' own inflammatory cells, platelets and growth factors: the first introduction to the low speed centrifugation concept. *Eur J Trauma Emerg Surg.* 2018 Feb;44(1):87–95.
7. Eshghpour M, Majidi MR, Nejat AH. Platelet-rich fibrin: an autologous fibrin matrix in surgical procedures: a case report and review of literature. *Iran J Otorhinolaryngol.* 2012 Autumn;24(69):197–202.
8. Raja VS, Sunitha Raja V, Munirathnam Naidu E. Platelet-rich fibrin: Evolution of a second-generation platelet concentrate [Internet]. Vol. 19, *Indian Journal of Dental Research.* 2008. p. 42. Available from: <http://dx.doi.org/10.4103/0970-9290.38931>
9. Verma UP, Yadav RK, Dixit M, Gupta A. Platelet-rich Fibrin: A Paradigm in Periodontal Therapy - A Systematic Review. *J Int Soc Prev Community Dent.* 2017 Sep;7(5):227–33.
10. Dohan DM, Choukroun J, Diss A, Dohan SL, Dohan AJJ, Mouhyi J, et al. Platelet-rich fibrin (PRF): a second-generation platelet concentrate. Part I: technological concepts and evolution. *Oral Surg Oral Med Oral Pathol Oral RadiolEndod.* 2006 Mar;101(3):e37–44.
11. Nakashima M, Akamine A. The application of tissue engineering to regeneration of pulp and dentin in endodontics. *J Endod.* 2005 Oct;31(10):711–8.
12. Bashutski JD, Wang H-L. Periodontal and endodontic regeneration. *J Endod.* 2009 Mar;35(3):321–8.
13. dental-congress-2018-posters-abstracts [Internet]. [cited 2019 Apr 6]. Available from: <https://doi.org/10.4172/2247-2452-C5-079>
14. Gupta S, Singh S, Garewal J, Vijay S, Makhija A, Gupta Y. A clinicomorphological study of Schneiderian Papilloma [Internet]. Vol. 3, *Indian Journal of Pathology and Oncology.* 2016. p. 347. Available from:
15. Heilig J, Yates J, Siskin M, McKnight J, Turner J. Calcium hydroxide pulpotomy for primary teeth: a clinical study. *J Am Dent Assoc.* 1984 May;108(5):775–8.
16. Waterhouse PJ, Nunn JH, Whitworth JM, Soames JV. Primary molar pulp therapy--histological evaluation of failure. *Int J Paediatr Dent.* 2000 Dec;10(4):313–21.
17. Kalaskar RR, Damle SG. Comparative evaluation of lyophilized freeze dried platelet derived preparation with calcium hydroxide as pulpotomy agents in primary molars. *J Indian Soc PedodPrev Dent.* 2004 Mar;22(1):24–9.
18. Ide Y, Nagasaki N, Tomioka R, Suito M, Kamiya T, Maeshima M. Molecular properties of a novel, hydrophilic cation-binding protein associated with the plasma membrane. *J Exp Bot.* 2007 Jan 29;58(5):1173–83.
19. Keswani D, Pandey RK, Ansari A, Gupta S. Comparative evaluation of platelet-rich fibrin and mineral trioxide aggregate as pulpotomy agents in permanent teeth with incomplete root development: a randomized controlled trial. *J Endod.* 2014 May;40(5):599–605.
20. Patidar S, Kalra N, Khatri A, Tyagi R. Clinical and radiographic comparison of platelet-rich fibrin and mineral trioxide aggregate as pulpotomy agents in primary molars. *J Indian Soc PedodPrev Dent.* 2017 Oct;35(4):367–73.
21. Huang F-M, Yang S-F, Zhao J-H, Chang Y-C. Platelet-rich fibrin increases proliferation and differentiation of human dental pulp cells. *J Endod.* 2010 Oct;36(10):1628–32.

22. Kumar A, Yadav A, Shetty N. One-step apexification using platelet rich fibrin matrix and mineral trioxide aggregate apical barrier. *Indian J Dent Res.* 2014 Nov;25(6):809–12.
23. Ghose LJ, Baghdady VS, Hikmat YM. Apexification of immature apices of pulpless permanent anterior teeth with calcium hydroxide. *J Endod.* 1987 Jun;13(6):285–90.
24. Kerekes K, Heide S, Jacobsen I. Follow-up examination of endodontic treatment in traumatized juvenile incisors. *J Endod.* 1980 Sep;6(9):744–8.
25. Cvek M. Prognosis of luxated non-vital maxillary incisors treated with calcium hydroxide and filled with gutta-percha. A retrospective clinical study [Internet]. Vol. 8, *Dental Traumatology.* 1992. p. 45–55. Available from: <http://dx.doi.org/10.1111/j.1600-9657.1992.tb00228.x>
26. Andreasen JO, Farik B, Munksgaard EC. Long-term calcium hydroxide as a root canal dressing may increase risk of root fracture. *Dent Traumatol.* 2002 Jun;18(3):134–7.
27. Shivashankar VY, Johns DA, Maroli RK, Sekar M, Chandrasekaran R, Karthikeyan S, et al. Comparison of the Effect of PRP, PRF and Induced Bleeding in the Revascularization of Teeth with Necrotic Pulp and Open Apex: A Triple Blind Randomized Clinical Trial. *J Clin Diagn Res.* 2017 Jun;11(6):ZC34–9.
28. Khanduri N, Kurup D. Single-visit apexification with Biodentine and platelet-rich fibrin [Internet]. Vol. 30, *Endodontology.* 2018. p. 181. Available from: [http://dx.doi.org/10.4103/endo.endo\\_122\\_17](http://dx.doi.org/10.4103/endo.endo_122_17)
29. Rutherford RB, Niekrash CE, Kennedy JE, Charette MF. Platelet-derived and insulin-like growth factors stimulate regeneration of periodontal attachment in monkeys. *J Periodontal Res.* 1992 Jul;27(4 Pt 1):285–90.
30. Hauser F, Gaydarov N, Badoud I, Vazquez L, Bernard J-P, Ammann P. Clinical and histological evaluation of postextraction platelet-rich fibrin socket filling: a prospective randomized controlled study. *Implant Dent.* 2013 Jun;22(3):295–303.
31. Simon BI, Von Hagen S, Deasy MJ, Faldu M, Resnansky D. Changes in alveolar bone height and width following ridge augmentation using bone graft and membranes. *J Periodontol.* 2000 Nov;71(11):1774–91.
32. Nacopoulos C. Use of Platelet Rich Fibrin in Facial Aesthetics and Rejuvenation [Internet]. Platelet Rich Fibrin in Regenerative Dentistry: Biological Background and Clinical Indications. 2017. p. 215–35. Available from: <http://dx.doi.org/10.1002/9781119406792.ch13>
33. Abd El Raouf M, Wang X, Miusi S, Chai J, Mohamed AbdEl-Aal AB, Nefissa Helmy MM, et al. Injectable-platelet rich fibrin using the low speed centrifugation concept improves cartilage regeneration when compared to platelet-rich plasma. *Platelets.* 2019;30(2):213–21.
34. Miron RJ, Choukroun J. Platelet Rich Fibrin in Regenerative Dentistry: Biological Background and Clinical Indications. John Wiley & Sons; 2017. 288 p.
35. Nizam N, Eren G, Akcalı A, Donos N. Maxillary sinus augmentation with leukocyte and platelet-rich fibrin and deproteinized bovine bone mineral: A split-mouth histological and histomorphometric study. *Clin Oral Implants Res.* 2018 Jan;29(1):67–75.
36. Tatullo M, Marrelli M, Cassetta M, Pacifici A, Stefanelli LV, Scacco S, et al. Platelet Rich Fibrin (P.R.F.) in reconstructive surgery of atrophied maxillary bones: clinical and histological evaluations. *Int J Med Sci.* 2012 Nov 7;9(10):872–80.

37. Miron RJ, Zucchelli G, Pikos MA, Salama M, Lee S, Guillemette V, et al. Use of platelet-rich fibrin in regenerative dentistry: a systematic review. *Clin Oral Investig*. 2017 Jul;21(6):1913–27.
38. Aoki N, Kanayama T, Maeda M, Horii K, Miyamoto H, Wada K, et al. Sinus Augmentation by Platelet-Rich Fibrin Alone: A Report of Two Cases with Histological Examinations. *Case Rep Dent*. 2016 Oct 3;2016:2654645.
39. Ali S, Bakry SA, Abd-Elhakam H. Platelet-Rich Fibrin in Maxillary Sinus Augmentation: A Systematic Review. *J Oral Implantol*. 2015 Dec;41(6):746–53.
40. Fernández MC, Dellan A, Requena D, Ramirez H, Castro JL, Cáribas A, et al. Use of alloplastic and xenograft bone filling with platelet rich fibrin in sinus lift, procedures and immediate dental implant placement [Internet]. Vol. 40, *International Journal of Oral and Maxillofacial Surgery*. 2011. p. 1141. Available from: <http://dx.doi.org/10.1016/j.ijom.2011.07.390>
41. Mazor Z, Horowitz RA, Del Corso M, Prasad HS, Rohrer MD, Dohan Ehrenfest DM. Sinus floor augmentation with simultaneous implant placement using Choukroun's platelet-rich fibrin as the sole grafting material: a radiologic and histologic study at 6 months. *J Periodontol*. 2009 Dec;80(12):2056–64.
42. Del Corso M, Vervelle A, Simonpieri A, Jimbo R, Inchingolo F, Sammartino G, et al. Current knowledge and perspectives for the use of platelet-rich plasma (PRP) and platelet-rich fibrin (PRF) in oral and maxillofacial surgery part 1: Periodontal and dentoalveolar surgery. *Curr Pharm Biotechnol*. 2012 Jun;13(7):1207–30.
43. Simonpieri A, Del Corso M, Vervelle A, Jimbo R, Inchingolo F, Sammartino G, et al. Current knowledge and perspectives for the use of platelet-rich plasma (PRP) and platelet-rich fibrin (PRF) in oral and maxillofacial surgery part 2: Bone graft, implant and reconstructive surgery. *Curr Pharm Biotechnol*. 2012 Jun;13(7):1231–56.
44. Anilkumar K, Geetha A, Umasudhakar, Ramakrishnan T, Vijayalakshmi R, Pameela E. Platelet-rich-fibrin: A novel root coverage approach. *J Indian Soc Periodontol*. 2009 Jan;13(1):50–4.
45. Aroca S, Keglevich T, Barbieri B, Gera I, Etienne D. Clinical evaluation of a modified coronally advanced flap alone or in combination with a platelet-rich fibrin membrane for the treatment of adjacent multiple gingival recessions: a 6-month study. *J Periodontol*. 2009 Feb;80(2):244–52.
46. Najeeb S, Khurshid Z, Agwan MAS, Ansari SA, Zafar MS, Matinlinna JP. Regenerative Potential of Platelet Rich Fibrin (PRF) for Curing Intrabony Periodontal Defects: A Systematic Review of Clinical Studies. *Tissue Eng Regen Med*. 2017 Dec;14(6):735–42.
47. Shah M, Patel J, Dave D, Shah S. Comparative evaluation of platelet-rich fibrin with demineralized freeze-dried bone allograft in periodontal infrabony defects: A randomized controlled clinical study. *J Indian Soc Periodontol*. 2015 Jan;19(1):56–60.
48. Findik Y, Kökdere N, Baykul T. The use of platelet-rich fibrin (PRF) and PRF-mixed particulated autogenous bone graft in the treatment of bone defects: An experimental and histomorphometrical study [Internet]. Vol. 12, *Dental Research Journal*. 2015. p. 418. Available from: <http://dx.doi.org/10.4103/1735-3327.166188>
49. Elgendy EA, Abo Shady TE. Clinical and radiographic evaluation of nanocrystalline hydroxyapatite with or without platelet-rich fibrin membrane in the treatment of periodontal intrabony

- defects. *J Indian Soc Periodontol.* 2015 Jan;19(1):61–5.
50. Gupta SJ, Jhingran R, Gupta V, Bains VK, Madan R, Rizvi I. Efficacy of platelet-rich fibrin vs. enamel matrix derivative in the treatment of periodontal intrabony defects: a clinical and cone beam computed tomography study. *J Int Acad Periodontol.* 2014 Jul;16(3):86–96.
51. Öncü E, Alaaddinoğlu EE. The effect of platelet-rich fibrin on implant stability. *Int J Oral Maxillofac Implants.* 2015 May;30(3):578–82.
52. Tabrizi R, Arabion H, Karagah T. Does platelet-rich fibrin increase the stability of implants in the posterior of the maxilla? A split-mouth randomized clinical trial. *Int J Oral Maxillofac Surg.* 2018 May;47(5):672–5.
53. Boora P, Rathee M, Bhorla M. Effect of Platelet Rich Fibrin (PRF) on Peri-implant Soft Tissue and Crestal Bone in One-Stage Implant Placement: A Randomized Controlled Trial. *J Clin Diagn Res.* 2015 Apr;9(4):ZC18–21.
54. Hehn J, Schwenk T, Striegel M, Schlee M. The effect of PRF (platelet-rich fibrin) inserted with a split-flap technique on soft tissue thickening and initial marginal bone loss around implants: results of a randomized, controlled clinical trial. *Int J Implant Dent.* 2016 Dec;2(1):13.
55. Angelo T, Marcel W, Andreas K, Izabela S. Biomechanical Stability of Dental Implants in Augmented Maxillary Sites: Results of a Randomized Clinical Study with Four Different Biomaterials and PRF and a Biological View on Guided Bone Regeneration. *Biomed Res Int.* 2015 Apr 12;2015:850340.
56. Marenzi G, Riccitiello F, Tia M, di Lauro A, Sammartino G. Influence of Leukocyte- and Platelet-Rich Fibrin (L-PRF) in the Healing of Simple Postextraction Sockets: A Split-Mouth Study. *Biomed Res Int.* 2015 Jul 26;2015:369273.
57. Temmerman A, Vandessel J, Castro A, Jacobs R, Teughels W, Pinto N, et al. The use of leucocyte and platelet-rich fibrin in socket management and ridge preservation: a split-mouth, randomized, controlled clinical trial. *J Clin Periodontol.* 2016 Nov;43(11):990–9.
58. Al-Hamed FS, Tawfik MA-M, Abdelfadil E, Al-Saleh MAQ. Efficacy of Platelet-Rich Fibrin After Mandibular Third Molar Extraction: A Systematic Review and Meta-Analysis [Internet]. Vol. 75, *Journal of Oral and Maxillofacial Surgery.* 2017. p. 1124–35. Available from: <http://dx.doi.org/10.1016/j.joms.2017.01.022>
59. Kang Y-H, Jeon SH, Park J-Y, Chung J-H, Choung Y-H, Choung H-W, et al. Platelet-rich fibrin is a Bioscaffold and reservoir of growth factors for tissue regeneration. *Tissue Eng Part A.* 2011 Feb;17(3-4):349–59.
60. Jankovic S, Aleksic Z, Klokkevold P, Lekovic V, Dimitrijevic B, Kenney EB, et al. Use of platelet-rich fibrin membrane following treatment of gingival recession: a randomized clinical trial. *Int J Periodontics Restorative Dent.* 2012 Apr;32(2):e41–50.
61. Dohan DM, Del Corso M, Charrier J-B. Cytotoxicity analyses of Choukroun’s platelet-rich fibrin (PRF) on a wide range of human cells: The answer to a commercial controversy [Internet]. Vol. 103, *Oral Surgery, Oral Medicine, Oral Pathology, Oral Radiology, and Endodontology.* 2007. p. 587–93.