

Implant Supported Mandibular Overdenture in Pre-existing Complete Denture Wearer-**Acceptance, Function and Stability**

¹Dr. Navjot Kaur, MDS, Consultant (Oral & Maxillofacial Surgeon), Miri Piri Institute of Medical Sciences & Research, Shahabad (M), Kurukshetra, Haryana, India.

²Dr. Fahad Ahmad, MDS, Registrar Surgeon, Department of Oral & Maxillofacial Surgery, Al-Jahra Specialty Dental Center & Hospital, MOH, Kuwait.

³Dr. SPS Sooch, MDS, Associate Professor, Department of Oral & Maxillofacial surgery, Punjab Govt. Dental College & Hospital, Amritsar, India

Corresponding Author: Dr. Fahad Ahmad

Address: Punjab Govt. Dental College & Hospital, Amritsar, India- 143001

Type of Publication: Original Research Paper

Conflicts of Interest: Nil

Abstract

Objective: This prospective study was done to assess the overall acceptance, improvement in masticatory performance and stability of implant supported overdenture among the patient who were complete denture wearer and had impaired function and stability of mandibular complete denture.

Material & Method: Eight complete denture wearer patients who had compromised function and stability of mandibular denture were included in the study. One-piece titanium implants were placed at canine-premolar regions of mandible, one implant on each side. Ball part of the implant was kept above the crest. Lower denture was modified and immediate loading was done after 48 hours. Acceptance, improvement in masticatory efficiency and stability of mandibular complete denture were recorded on 100 mm Visual Analogue Scale (VAS) on 2nd day, 7th day, after 6 weeks and after 3 months.

Result and Observation: Present study showed a better acceptance by the patients as 95 score was recorded on VAS scale and mean change from baseline was 60.00 ±

10.00, t' value was 16.97 and 'p' value was found <0.001 after 3 months. In masticatory function mean change from baseline was 51.63 ± 8.62, t' value recorded 16.94 and 'p' value was found <0.001. Similarly, improvement in stability was also found significant. Few minor post-surgical complications were encountered; however; no major complication noted.

Conclusion: In conclusion, Implant supported mandibular overdenture not only improves the stability & function but also increases the overall acceptance of this newly evolved prosthesis in compare to conventional complete denture. It can be a considered as a better alternative to the conventional removable complete denture.

Keywords: Edentulous mandible; Complete denture; Overdenture; One-piece Implant; Ball attachment

Introduction

Tooth loss is a serious life event. Although dental science has advanced and the rate of edentulism among the elderly is continually decreasing, edentulism is considered a major health problem, affecting millions of individuals throughout the world. It not only affects self-confidence,

but also has a dramatic impact on the quality of life. In denture wearers, quality of life is measured by socio-dental indicators. Locker defined these indicators as: measures of the extent to which dental and oral disorders disrupt normal social role functioning and bring about major changes in behavior¹. Therefore quality of life affects denture wearers with regard to patient satisfaction, nutrition and psycho-social aspects of life². When teeth are removed, “Mother Nature” assumes there is no need for the bone that supports the teeth. Over time the bone slowly, but progressively diminishes, the upper and lower jaw bones resorb.

For decades the best solutions for the replacement of missing teeth were bridges, removable partial or full dentures³. Out of maxillary and mandibular complete dentures, more than 50% of conventional mandibular complete dentures have problems with retention and stability, and mandibular denture produces significantly more problems than maxillary dentures, primarily because of poor prosthesis retention. Implant-supported or retained dentures have been increasingly accepted as an alternative to conventional dentures for oral rehabilitation of edentulous patients².

A good option to preserve the alveolar bone loss is the use of overdentures. An overdenture is defined as a prosthesis that covers and is partially supported by natural teeth, tooth roots, and/or dental implants². Overdenture may be tooth supported or implant supported overdentures. In tooth supported overdentures, retention of teeth or tooth roots in the alveolar bone can improve bone maintenance around and between these structures. However, tooth borne overdentures have a number of disadvantages e.g. caries of abutment teeth or periodontal breakdown etc³.

Dental implants are being increasingly used as suitable prosthodontic substitutes for natural teeth⁴. For general

application in the edentulous mandible, a treatment concept utilising two or four implants to support a mandibular overdenture has been proposed. Although various studies conclude that treatment concepts with either two or four implants result in a good treatment outcome regarding prosthodontic rehabilitation of the patient with problems in their mandibular dentures, the two implant overdenture is a preferred and cost effective treatment option in the edentulous mandible for older adults⁵.

In the recent past, surgical intervention in the form of implants, improved the masticatory efficiency, and stability of lower denture in patients with complete dentures. **MacEntee MI et al**⁵ conducted a clinical trial of patient satisfaction and prosthodontic needs with ball and bar attachments for implant retained complete overdenture. They found that receiving new dentures with implant supports, improved satisfaction “within subject” that was prompt, durable, substantial and statistically significant^{5,6}.

The present study was undertaken to assess overall acceptance, improvement in masticatory performance and stability of mandibular denture following the provision of implant-retained mandibular overdenture.

Material & Method

Eight patients with completely edentulous jaws bearing upper and lower complete dentures but having impaired masticatory functions and stability of lower denture particularly, reporting to the Department of Oral and Maxillofacial Surgery at Punjab Government Dental College and Hospital, Amritsar were included in the study. This Prospective study was duly approved by institutional ethical committee.

The patients were selected irrespective of sex, social status, caste and creed.

Inclusion criteria were

- Patients with completely edentulous jaws wearing complete dentures.
- Residual bone height in the area between two mental foramina of mandible was sufficient
- Patients who were having good oral hygiene and well informed patients, who gave their consent for implant surgery.

Patients with poor oral hygiene, chronic smoker, with severe maxillomandibular discrepancy or immunocompromised status were excluded from the study. Preoperatively, a thorough clinical and radiological examinations (Orthopantomogram & Dentascan) were performed. (Fig.1)

Leader one piece non-submerged implants with ball attachments were used. Those were one-piece titanium implants with 3.2 mm diameter and 10 mm length. Under strict aseptic technique, surgical placements of two implants were done in mandibular canine-premolar regions, one in each side under local anesthesia with antibiotic prophylaxis⁷. The implant was placed such that the ball (2.5 mm in diameter) remained above the crestal bone. (Fig.2)

After 48 hours of surgery, denture modification process was carried out by following steps:

- Space was created in the lower denture base to accommodate attachments by properly marking the sites with articulating paper corresponding to implants. (Fig.3)
- Nylon caps (receptacles) were placed on the ball part of the implants. (Fig.4)
- The denture was accurately positioned on the mandibular ridge and the Nylon caps were luted within the mandibular denture with autopolymerizing acrylic resin⁸.

- Upper denture was inserted into patient's mouth and patient was instructed to close dentures in centric occlusion till luting was furnished.
- After autopolymerizing resin was set, extra resin was ground off. (Fig.5)

During follow-up period, patients' ratings of overall acceptance, improvement in masticatory efficiency and stability of mandibular complete denture were recorded on 100 mm Visual Analogue Scale (VAS) on 2nd day, 7th day, after 6 weeks and after 3 months. The VAS was anchored at each end as "completely dissatisfied" and "completely satisfied".

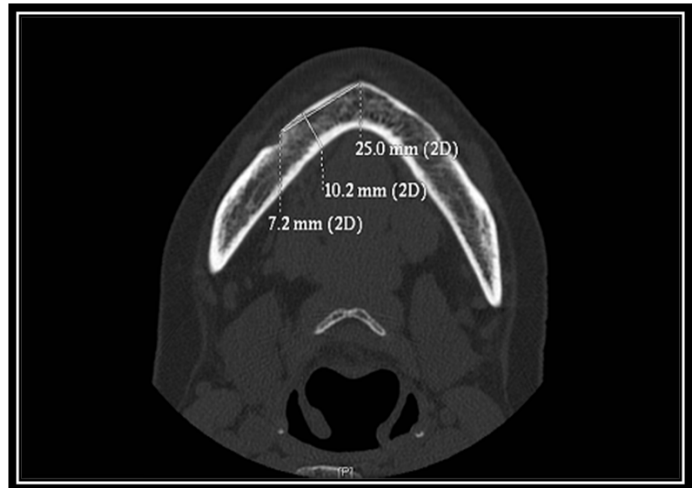


Fig.1: 2-D view (Dentascan)

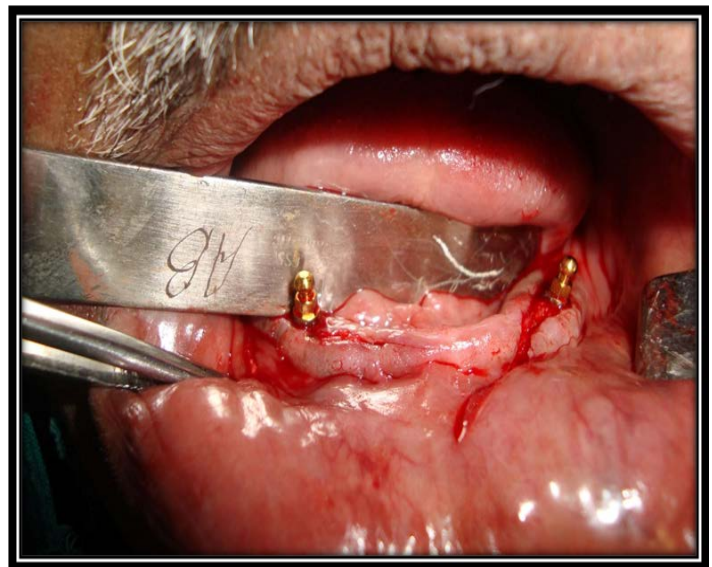


Fig.2: Implants in position

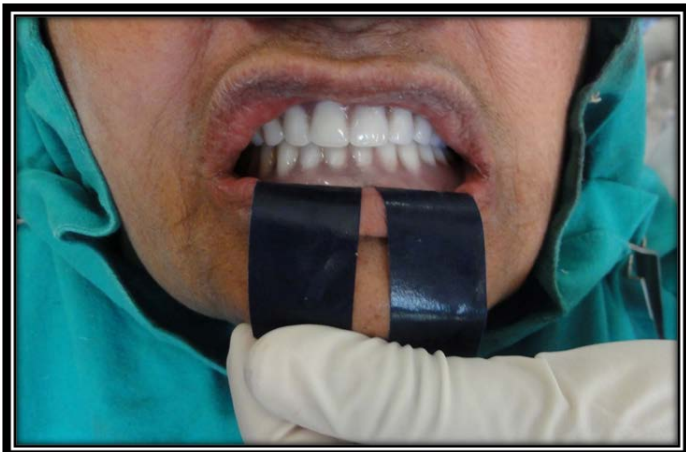

Fig.3: Articulating Paper in Position over Implants

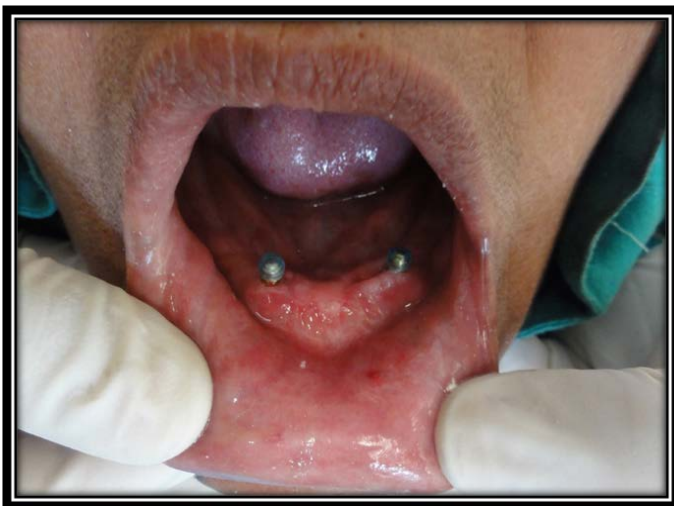

Fig.4: Nylon Caps Placed Over Ball Part of Implants

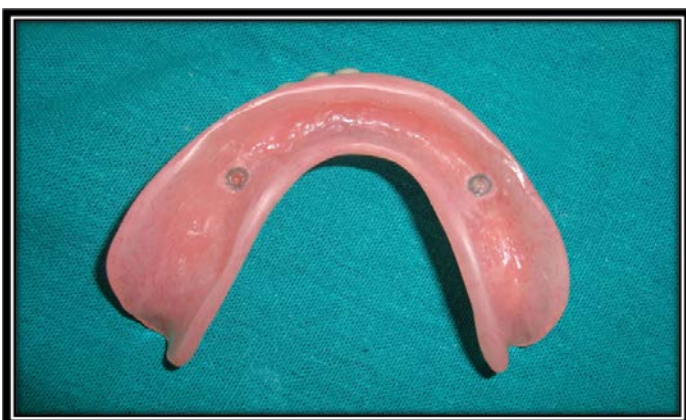

Fig. 5: Nylon Caps acrylated in Mandibular complete Denture

Result and Observation

In the present study male to female ratio was 1:1. Over all acceptance was recorded in all the 8 patients around 80 on 2nd post-operative day; however; score was increased to 95

on VAS scale after 3 months of surgery. Furthermore, on 2nd day mean change from baseline (Conventional Denture) was 49.38 ± 8.2 . 't' value was 17.00 and 'p' value was found <0.001 . However, after 3 months, mean change from baseline was 60.00 ± 10.00 , t' value 16.97 and 'p' value found <0.001 , which was highly significant. (Table –I)

Similarly, masticatory efficiency was recorded 79-80 on VAS scale on 2nd day. However, it also increased to 87-95 in 3 months post- operatively. Statistical analysis on masticatory efficiency after 3 months showed mean change from baseline 51.63 ± 8.62 , 't' value recorded 16.94 and 'p' value found <0.001 , which was significant as well. (Table –II)

Third parameter, stability was also assessed on VAS scale and found 75-87 on second post-operative day, which was increased to 87-95 after 3 months. In addition, statistical analysis of stability was also found significant. (Table – III)

Follow up was done for two years; no major complication like peri-implantitis, loosening of denture was noted. However, marginal bone loss of were noted around three implants. In addition, minor surgical complications like mild swelling and pain were noted in the immediate post-surgical period in all the patients. Further, two patients showed ecchymosis as well that resolved within a week.

Table –I: Overall Acceptance

Time	N	Mean \pm SD	Mean Change from Baseline	't' value	p value
Baseline	8	33.13 \pm 8.43	-	-	-
Day 2	8	82.50 \pm 2.67	49.38 \pm 8.21	17.00	$<0.001^*$
Day 7	8	86.25 \pm 3.54	53.13 \pm 9.23	16.27	$<0.001^*$
Week 6	8	91.25 \pm 2.31	58.13 \pm 8.43	19.51	$<0.001^*$
Month 3	8	93.13 \pm 2.59	60.00 \pm 10.00	16.97	$<0.001^*$

Table –II: Masticatory Efficiency

Time	N	Mean ± SD	Mean Change from Baseline	't' value	p value
Baseline	8	38.75 ± 7.74	-	-	-
Day 2	8	83.13 ± 3.18	44.38 ± 9.96	12.61	<0.001*
Day 7	8	86.25 ± 2.66	47.50 ± 9.26	14.51	<0.001*
Week 6	8	88.88 ± 2.36	50.13 ± 8.81	16.10	<0.001*
Month 3	8	90.38 ± 2.33	51.63 ± 8.62	16.94	<0.001*

Table –III: Stability

Time	N	Mean ± SD	Mean Change from Baseline	't' value	p value
Baseline	8	39.25 ± 5.80	-	-	-
Day 2	8	80.63 ± 3.86	41.38 ± 7.86	14.90	<0.001*
Day 7	8	84.50 ± 4.11	45.25 ± 6.92	18.49	<0.001*
Week 6	8	87.63 ± 3.34	48.38 ± 5.68	24.09	<0.001*
Month 3	8	90.00 ± 3.30	50.75 ± 7.05	20.37	<0.001*

* p < 0.001; Highly Significant

Discussion

The present study was conducted in eight patients with completely edentulous jaws bearing upper and lower complete dentures but having compromised function and stability of lower denture particularly. The aim of the study was to assess the acceptance, improvement in masticatory performance and stability of mandibular denture following the provision of implant-retained mandibular overdenture.

Edentulous patients often experience problems with their mandibular complete dentures. Lack of stability and retention of their mandibular denture, together with a decreased chewing ability are the main complaints of these patients⁹. Doundoulakis JH et al¹⁰ described implant-

supported overdenture as an alternative to the complete mandibular denture and found that implants placed in the anterior mandible (anterior to the mental foramen) have a success rate better than 95%. Additionally, they observed that implant supported overdentures in the mandible provide predictable results with improved stability, retention, function and patient satisfaction compared with conventional dentures.

MacEntee MI et al⁴ did a clinical trial of patient satisfaction and prosthodontic needs with ball and bar attachments for implant retained complete overdenture. They found significant improvement in satisfaction amongst patients after receiving new dentures with mandibular implant supports, regardless of the attachment mechanism, and with or without a reinforcing framework. Moreover, Walton JN et al¹¹ observed that there were no significant differences between mandibular IODs retained by either titanium caps on two 2.25-mm ball abutments or 2 metal clips on a round gold bar in the number of appointments or overall time required to fabricate the dentures, the number of adjustments needed after prosthesis placement, or overall patient satisfaction with their new dentures. In another study, Sadowsky SJ¹² reviewed and elucidated that the solitary ball attachments appear to be less costly, less technique sensitive, and more accommodating of tapered arches.

Van Steenberghe et al (1987)¹³ were among the first authors to propose placement of only 2 implants in the edentulous mandible and reported 98% success rate, with up to 52 months of observation. Similarly, Mericske-Stern et al (1994)¹⁴ reported 97% implant survival with 2 implants (splinted or solitary), irrespective of keratinized tissue or duration of edentulism. However, Jemt et al (1996)¹⁵ reported 100% cumulative success rate for overdentures supported by 2 implants with the mean marginal bone loss of 0.5 mm during a 5-year period.

Implant loading time is considered to influence the treatment outcomes as well. According to conventional protocol, for two weeks after surgery the patients are not allowed to wear their mandibular dentures and the healing time of at least 3 months is required before connection of the overdenture to the implants¹⁶. Traditionally one or two stage approach can be employed. However, number of experimental studies have shown that implant loading up to 3 months can produce equally satisfactory results in edentulous anterior mandible^{17, 18, 19}. Increased bone-to-implant contact at earlier healing times with newly designed implant surfaces were reported. Immediate (up to 2 days after surgery) and early (up to 3 months after surgery) loading protocols were proposed¹⁷. Due to reduced overall treatment time & discomfort, high patient acceptance and better function they are gaining wider acceptance. Consequently, implant manufacturers extensively market one-piece implants for mandibular implant supported overdentures. Moreover, the one-stage procedure offers distinct advantages for elderly patients because of reduced surgical procedures and treatment cost²⁰.

The results of our study revealed marked improvement in masticatory efficiency, stability and overall acceptance of mandibular complete denture. The student 't' test was used for comparing the values at different time intervals. The results showed that overall acceptance, improvement in masticatory efficiency and stability of mandibular complete denture was highly significant ($p \text{ value} \leq 0.001$). The findings of the present study are in concurrence with the study of **Mac Entee MI et al (2005)**⁴ who did a clinical trial of patient satisfaction and prosthodontic needs with ball and bar attachments for implant retained complete overdenture and found improved satisfaction "within subject" was durable, substantial and statistically significant. Furthermore, Walton JN et al¹¹ also found

remarkable patients satisfaction with the improvement in function, comfort, and appearance with implants retained overdenture compared to their original conventional dentures.

Conclusion

In conclusion, present study showed better stability and improved masticatory performance with implant supported mandibular overdenture. In addition, overall acceptance rate of implant supported overdenture was proved to be better than conventional removable denture. However before any definite conclusion can be drawn, a large number of samples and longer period of observations are required to evaluate long term improvement in masticatory efficiency and stability of implant retained mandibular overdenture.

Acknowledgment

The authors are very grateful and would like to thank Dr. Gagandeep Singh for providing technical support for the present study.

References

1. Locker D, Allen F. What do measures of 'oral health-related quality of life' measure? *Community Dent Oral Epidemiol.* 2007; 35: 401–411.
2. Saran RH. Comparative Analysis of Implant Supported dentures with Complete Mandibular Denture. *Archives of Dental Sciences.* 2010; 1(1):12-16.
3. Winkler S. *Essentials of Complete Denture Prosthodontics* 2nd edition, 2009.
4. Misch CE. *Contemporary implant dentistry* 3rd edition, 2008, pp.293-311.
5. MacEntee MI, Walton JN, Glick N. A clinical trial of patient satisfaction and prosthodontic needs with ball and bar attachments for implant-retained complete overdentures: Three-year results. *J Prosthet Dent.* 2005; 93: 28-37.

6. Wismeijer D, Wass M.A.J.V, Vermeeren J.I.J.F, Mulder J, Kalk W. Patient satisfaction with implant supported mandibular overdentures. A comparison of three treatment strategies with ITI-implants. *Int. J. Oral Maxillofac. Surg.* 1997; 26: 263-267.
7. Hossein K, Dahlin C, Bengt A. Influence of Different Prophylactic Antibiotic Regimens on Implant Survival Rate: A Retrospective Clinical Study. *Clinical Implant Dentistry and Related Research* 2005; 7(1): 32-35.
8. Rutkunas V, Mizutani H, Puriene A. Conventional and early loading of two implant supported mandibular overdentures. A systematic review. *Stomatologija, Baltic Dental and Maxillofacial Journal* 2008; 10, 51-61.
9. Visser A, Raghoobar GM, Meijer HJA, Batenburg RHK, Vissink A. Mandibular overdentures supported by two or four endosseous implants A 5-year prospective study. *Clin Oral Impl Res* 2005; 16: 19-25.
10. Doundoulakis JH, Eckert SE, Lindquist CC, Jeffcoat MK. The implant-supported overdenture as an alternative to the complete mandibular denture. *JADA* 2003; 134: 1455-1458.
11. Walton JN, MacEntee MI, Glick N. One-year prosthetic outcomes with implant overdentures: a randomized clinical trial. *Int J oral maxillofac implants* 2002; 17: 391-398.
12. Sadowsky SJ. Mandibular implant-retained overdentures: A literature review. *J Prosthet Dent* 2001; 86(5): 468-473.
13. Van Steenberghe D, Quirynen M, Calberson L, Demanet M. A prospective evaluation of the fate of 697 consecutive intra-oral fixtures and modern Branemark in the rehabilitation of edentulism. *Journal of Head and Neck Pathology.*1987; 6: 53-58.
14. Mericske-Stern RD, Taylor TD, Belser U. Management of the edentulous patient. *Clinical Oral Implants Research.*2000; 11: 108-125.
15. Jemt T, Chai J, Harnett J, Heath R, Hutton J, Johns R, et al. A 5-year prospective multicenter follow-up report on overdentures supported by osseointegrated implants. *Int J Oral Maxillofac Implants* 1996;11:291–298.
16. Tawse-Smith A, Payne AGT, Kumara R, Thomson WM. Early loading of unsplinted implants supporting mandibular overdentures using a one-stage operative procedure with two different implant systems: a 2-year report. *Clinical Implant Dentistry and Related Research* 2002; 4(1): 33-42.
17. Payne AGT, Tawse-Smith A, Perio C, Thomson WM, Kumara R. Early functional loading of unsplinted roughened surface implants with mandibular overdentures 2 weeks after surgery. *Clinical Implant Dentistry and Related Research* 2003; 5(3): 143-153.
18. Becker W, Becker BE, Huffstetler S. Early functional loading at 5 days for Branemark implants placed into edentulous mandibles: A prospective, open-ended, longitudinal study. *J Periodontol* 2003; 74, 695-702.
19. Chee W, Jivraj S. Efficiency of Immediately Loaded Mandibular Full-Arch Implant Restorations. *Clinical Implant Dentistry and Related Research* 2003 5(1): 52-56.
20. Klemetti E, Chegade A, Takanashi Y, Feine JS, Two-Implant Mandibular Overdentures: Simple to Fabricate and Easy to Wear. *J Can Dent Assoc*, 2003; 69(1): 29-33.