

Clinicopathological Study of Peripheral Ossifying Fibroma in a Kashmiri Population

Fayiza Yaqoob Khan¹, Mubashir Mushtaq²

¹Department of Periodontics and Oral Implantology, Government Dental College and Hospital Srinagar, Kashmir, India

²Department of Conservative Dentistry and Endodontics, Government Dental College and Hospital Srinagar, Kashmir, India

Corresponding Author: Fayiza Yaqoob Khan, Department Of Periodontics And Oral Implantology, Government Dental College And Hospital Srinagar, Kashmir, India.

Type of Publication: Original Research Paper

Conflicts of Interest: Nil

Abstract

Peripheral cement ossifying fibromas are reactive rather than of neoplastic nature, the pathogenesis being uncertain. The lesion is seen mostly in adolescents and young adults, with the highest prevalence in 10-19 year age group and affecting females more than males (two to four times more), maxilla affected more than mandible. The present clinicopathological study investigated 150 cases of peripheral ossifying fibroma in a Kashmiri population.

Keywords: Peripheral cementifying fibroma, peripheral ossifying fibroma, pyogenic granuloma

Introduction

The peripheral ossifying fibroma (POF) makes about 3.1% of all oral tumors [1] and for 9.6% of all gingival lesions. [2] This lesion was first described in 1872 by Menzel. [3] The literature reports a great incidence in infants and in young adults, mainly in the age group of 10 to 19 years, [4] mainly affecting females (two to four times more), [5] suggesting some hormonal influences as well. [1] The pathogenesis of this tumor is uncertain; however, the pluripotent cells of the periodontal ligament have the apparent ability to transform or metaplastically change into osteoblasts, cementoblasts or fibroblasts, in

response to irritants such as calculus, bacterial plaque, orthodontic appliances, ill-adapted crowns, and irregular restorations, and are therefore, capable of producing a unique inflammatory hyperplasia, the peripheral ossifying fibroma. [1,6-10] The cells of the periosteum or periodontal ligament also synthesize the mineralized product of this entity. The POF, representing a reactive benign lesion of the connective tissue, is not the soft tissue counterpart of the central ossifying fibroma, which represents an osteogenic neoplasm. [11] The central type of ossifying fibroma arises from the endosteum or the periodontal ligament (PDL) adjacent to the root apex and expands from the medullary cavity of the bone. On the other hand, the peripheral type shows a contiguous relationship with the PDL, occurring solely on the soft tissues overlying the alveolar process. Clinically POF presents as a solitary, slow-growing, and well-demarcated nodular mass that exhibits a smooth surface, usually with normal-colored mucosa. It has a sessile or pedunculated base and is generally of a hard consistency. [12] Such lesions are generally smaller than 1.5 cm in diameter, [13] although there have been reports of some large 4 cm lesions as well. [14] About 60% of such lesions occur in the maxilla and more than 50% of all cases affect the

region of the incisors and canines; more precisely in the interdental papilla.[4,13-15] In the vast majority of cases, there is no apparent underlying bone involvement visible on the roentgenogram. However, on rare occasions, there does appear to be superficial erosion of the bone. A possibility of tooth migration due to the presence of a peripheral cemento-ossifying fibroma has been reported.[16] The lesions must be surgically excised and microscopically examined for confirmation of diagnosis. The extraction of the adjacent teeth is seldom necessary. However, the lesions do occur with some frequency, and in fact, repeated recurrences are not uncommon. Clinical differential diagnosis for such gingival growths includes fibroma, peripheral giant cell granuloma, pyogenic granuloma, peripheral odontogenic fibroma, and peripheral ossifying fibroma.[17]

Materials and Methods

The study was conducted jointly in the departments of periodontics and conservative dentistry and endodontics, government Dental college srinagar. Detailed clinical and histological information of 150 surgically removed POFs formed the basis of the study. The criteria of patients for inclusion in the study were:

- a) Age group 10-19 years
- b) Presence of at least one clinical lesion in the mouth
- c) Kashmiri origin patients

150 lesions of POF diagnosed clinically and histologically were evaluated for their biological considerations.

Clinical manifestation of the lesions

Majority of the POF lesions included in the study were slow-growing, painless, soft tissue masses. The lesions usually started as small papules. According to the patients, the lesions had been present for approximately two months before diagnosis. As reported by the patients, the lumps were interfering with bite making them uncomfortable. Occasionally, bleeding occurred on tooth

brushing. The lesions initially occurred on one side of the mouth and in a subsequent course of time involved both sides. Both the maxillary and mandibular gingivae were affected and the growths appeared as nodular masses, with erythematous and ulcerated surfaces. The growths were sessile and firm in consistency measuring anywhere between 5 mm and 3 cm in diameter. The lesions appeared reddish-pink in color and were slightly pedunculated, with what appeared to be a broad-based attachment. The lesions were not fluctuant, nor did they blanch with pressure, but had a rubbery consistency. The lesions were tender to firm pressure, but not to light palpation.

Radiographic examination

Panoramic radiographs were obtained [Figure 3]. The radiographs did not reveal any abnormality and there was no finding pertaining to the multiple exophytic lesions.

Biochemical investigations

The laboratory tests performed included, a complete blood hemogram and lipid and thyroid profiles. All the test results were within normal limits except for the total leukocyte count, which was slightly more than normal in some cases (12800/mm³ of blood).

Histopathological examination

On histopathological examination, upon low power magnification (4x), the lesional tissues exhibited a keratinized stratified squamous epithelium (gingiva), overlying a fibrous connective tissue stroma exhibiting dense interlacing bundles of collagen and numerous ossifications [Figure 4]. High power magnification (40x) showed pink homogenous calcified tissue (ossification), with a presence of osteocytes entrapped in the lacunae [Figure 5]. The histology for all the lesions was the same. The picture is consistent with the clinical diagnosis of POF.

Results and Statistical Analysis

The POF was found more frequently in females(70%), (Table 1).76% of the POF lesions were found in the Maxillary gingiva and 24% of the lesions were found in the mandibular gingiva, (Table 2) . Majority of the lesions were seen in the canine/premolar region(70%).

Table 1

Total lesions	POF	Females		Males	
		No	%	No	%
150		105	70	45	30

Table 2

Total lesions	POF	Maxillary gingival\		Mandibular gingival	
		No	%	No	%
150		114	76	36	24

Discussion

Intraoral ossifying fibromas have been described in literature since the late 1940s. Many names have been given to similar lesions, such as, epulis, peripheral fibromas with calcification, peripheral ossifying fibromas, calcifying fibroblastic granuloma, peripheral cementifying fibroma, peripheral fibroma with cementogenesis, and peripheral cemento-ossifying fibroma.[3,6,18-21] The varied nomenclature used for fibroblastic gingival lesions indicates that there is much controversy surrounding the classification of these lesions.[6,22] The main etiological factors of POF are trauma and chronic irritation, particularly from the subgingival plaque and calculus.[3,5,8,23] Eversole and Rovin[3] stated that the constant irritation present during exfoliation of the deciduous teeth and eruption of the permanent teeth may also result in an increased incidence of reactive lesions, which originate from the periodontal ligament. This hypothesis is based on the fact that POFs arise exclusively on the gingiva, the subsequent proximity of the gingiva to the periodontal ligament, and the inverse correlation between age distribution of patients presenting with POF

and the number of missing teeth with associated periodontal ligament.[1,23] Despite reports of POF in children with deciduous or mixed dentition, little data is available regarding the specific occurrence of this lesion, with involvement of the deciduous dentition. The literature also reflects the association of natal teeth with the peripheral ossifying fibroma.[24] Defective odontogenesis and/or retarded eruption of teeth have also been found to be associated with similar histological features in the dental follicles.[25] Ossifying fibromas may be clinically and radiographically impossible to separate from cementifying fibromas.[26] Much of the research study has been carried out to distinguish ossifying fibromas from cementifying fibromas, by using immunohistochemical analysis for keratin sulfate and chondroitin-4 sulfate, in which the cementifying fibromas show significant immunoreactivity for keratin sulfate and the ossifying fibromas show intensive immunostaining for chondroitin-4 sulfate.[27] Such lesions may be present for a number of months to years before excision, depending on the degree of ulceration, discomfort, and interference with function.[4,18]The present study evaluated the occurrence of POF in a Kashmiri population, further studies are needed to evaluate the condition in the current population using contemporary gene analysis techniques.

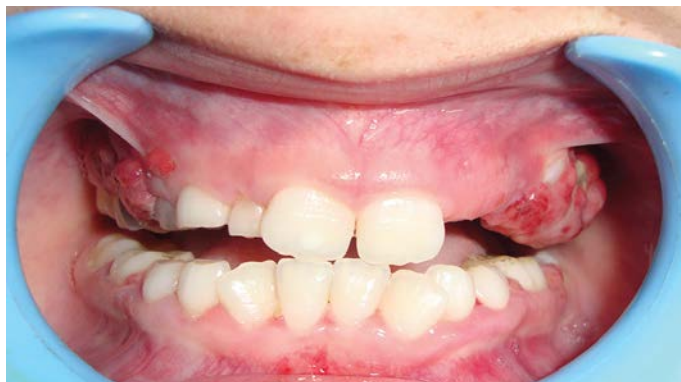

Figure 1: Multiple oral lesions of peripheral ossifying fibroma in both the maxilla as well as the mandible

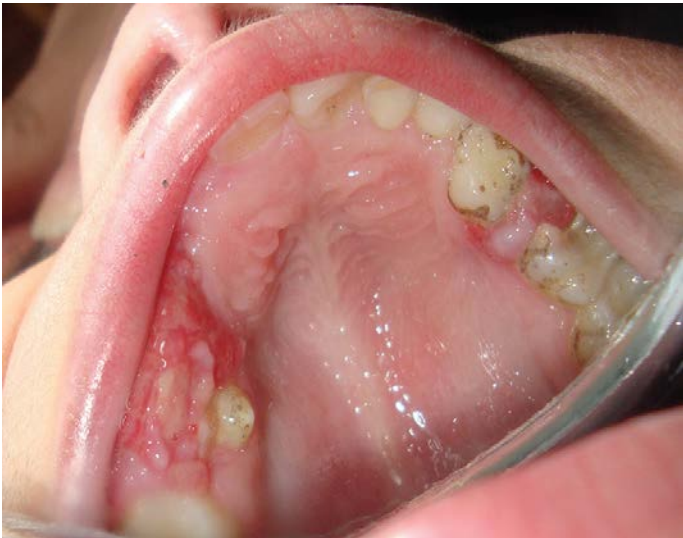

Figure 2: Occlusal clinical view of the lesions showing their expansile nature

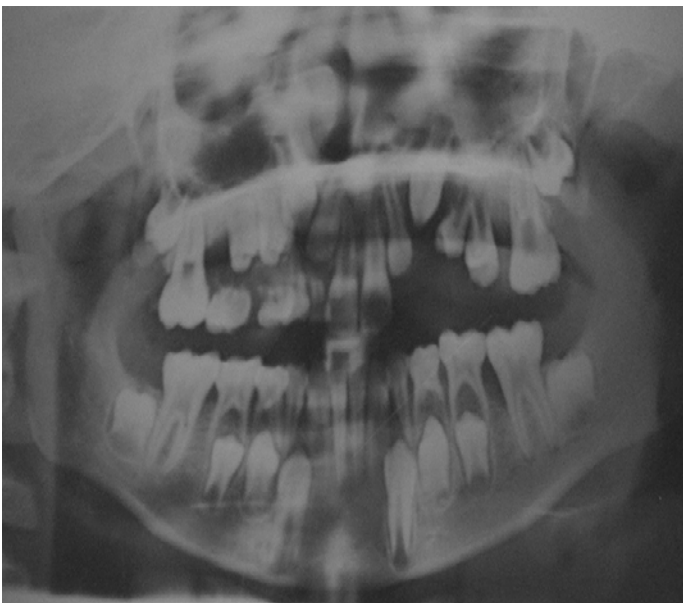

Figure 3: Orthopantomogram of a patient showing mixed stage of dentition, without any abnormality pertaining to the multiple exophytic lesions

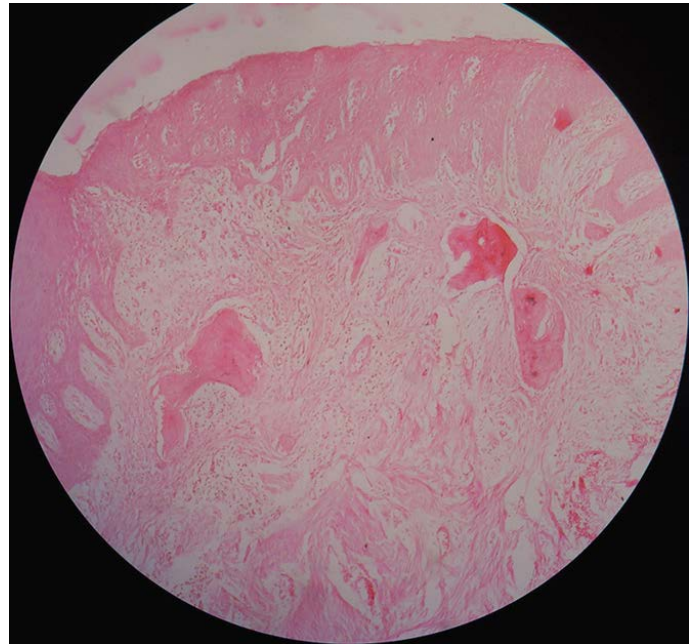


Figure 4: Histopathological examination of the lesional tissue at $\times 4$ magnification.

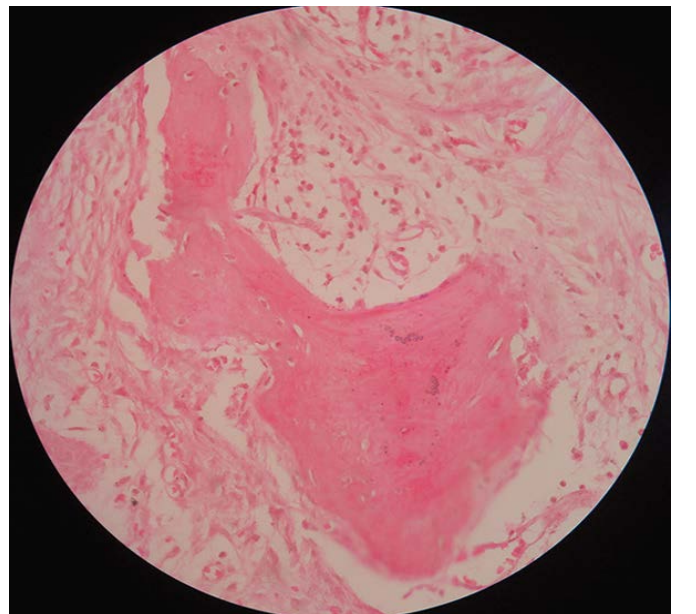


Figure 5: Histopathological examination of the lesional tissue at $\times 40$ magnification

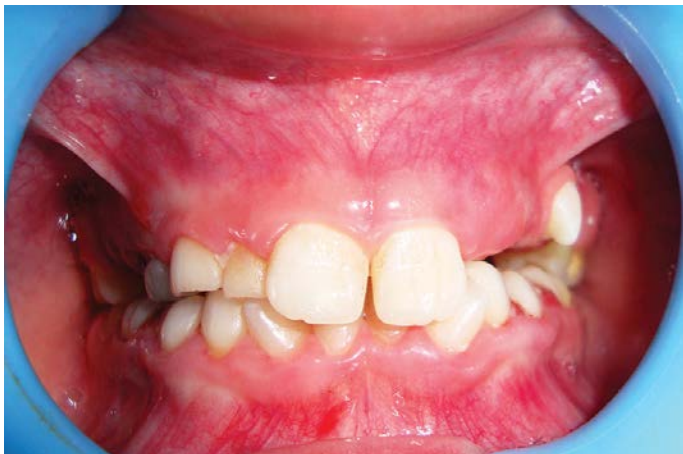

Figure 6: Post treatment photograph

Conclusion

A peripheral cement-ossifying fibroma is a slowly progressing lesion, the growth of which is generally limited. Many cases will progress for long periods before patients seek treatment, because of the lack of symptoms associated with the lesion. Treatment consists of surgical excision, including the periosteum and scaling of the adjacent teeth. Close postoperative follow-up is required because of the growth potential of incompletely removed lesions and an 8 - 20% recurrence rate.

References

1. Kenney JN, Kaugars GE, Abbey LM. Comparison between the peripheral ossifying fibroma and peripheral odontogenic fibroma. *J Oral Maxillofac Surg* 1989;47:378-82.
2. Walters JD, Will JK, Hatfield RD, Cacchillo DA, Raabe DA. Excision and repair of the peripheral ossifying fibroma: A report of 3 cases. *J Periodontol* 2001;72:939-44.
3. Eversole LR, Sabers WR, Rovein S. Fibromy dysplasia: A nosology problem in the diagnosis of fibro-osseous lesion of the jaw. *J Oral Pathol* 1972;1:189-220.

4. Neville BW, Damm DD, Allen CM, Bouquot JE. *Oral and Maxillofacial Pathology*. Philadelphia: W.B. Saunders; 1995.
5. Buchner A, Hansen LS. The histomorphologic spectrum of peripheral ossifying fibroma. *Oral Surg Oral Med Oral Pathol* 1987;63:452-61.
6. Kumar SK, Ram S, Jorgensen MG, Shuler CF, Sedghizadeh PP. Multicentric peripheral ossifying fibroma. *J Oral Sci* 2006;48:239-43.
7. Eversole LR, Rovin S. Reactive lesions of the gingival. *J Oral Pathol* 1972;1:30-8.
8. Mesquita RA, Orsini SC, Sousa M, de Araújo NS. Proliferative activity in peripheral ossifying fibroma and ossifying fibroma. *J Oral Pathol Med* 1998;27:64-7.
9. Carrera Grañó I, Berini Aytés L, Escoda CG. Peripheral ossifying fibroma: Report of a case and review of the literature. *Med Oral* 2001;6:135-41.
10. Orkin DA, Aimadas VD. Ossifying fibrous epulis. *Oral Surg Oral Med Oral Pathol* 1984;57:147-8.
11. Neville BW, Damm DD, Allen CM, Bouquot JE. *Oral and Maxillofacial Pathology*. 2nd ed. New Delhi: Elsevier; 2005. p. 563-4.
12. Baumgartner JC, Stanley HR, Salomone JL. Peripheral ossifying fibroma. *J Endod* 1991;17:182-5.
13. Kfir Y, Buchner A, Hansen LS. Reactive lesions of the gingival: A clinicopathologic study of 741 cases. *J Periodontol* 1980;51:655-61.
14. Kendrick F, Waggoner WF. Managing a peripheral ossifying fibroma. *ASDC J Dent Child* 1996;63:135-8.
15. Kohli K, Christian A, Howell R. Peripheral ossifying fibroma associated with a neonatal tooth: Case report. *Pediatr Dent* 1998;20:428-9.

16. Delbem AC, Cunha RF, Silva JZ, Soubhia AM. Peripheral cementoossifying fibroma in child. a follow-up of 4 years. Report of a case. *Eur J Dent* 2008;2:134-7.
17. Rajendran R. Benign and malignant tumors of oral cavity. In: Shafer WG, Hine MK, Levy BM, Editors. *Shafer's Textbook of Oral Pathology*. 5th ed. Philadelphia, PA: W.B. Saunders Co; 2006. p. 113-308.
18. Bhaskar SN, Jacoway JR. Peripheral fibroma and peripheral fibroma with calcification: Report of 376 cases. *J Am Dent Assoc* 1966;73:1312-20.
19. Gardner DG. The peripheral odontogenic fibroma: An attempt at clarification. *Oral Surg Oral Med Oral Pathol* 1982;54:40-8.
20. Lee KW. The fibrous epulis and related lesions. Granuloma pyogenicum, 'Pregnancy tumour', fibro-epithelial polyp and calcifying fibroblastic granuloma. A clinico-pathological study. *Periodontics* 1968;6:277-92.
20. Feller L, Buskin A, Raubenheimer EJ. Cemento-ossifying fibroma: Case report and review of the literature. *J Int Acad Periodontol* 2004;6:131-5.
21. Zain RB, Fei YJ. Fibrous lesions of the gingiva: A histopathologic analysis of 204 cases. *Oral Surg Oral Med Oral Pathol* 1990;70:466-70.
22. Cuisa ZE, Brannon RB. Peripheral ossifying fibroma: A clinical evaluation of 134 pediatric cases. *Pediatr Dent* 2001;23:245-8.
23. Singh S, Subbba Reddy VV, Dhananjaya G, Patil R. Reactive fibrous hyperplasia associated with a natal tooth: A case report. *J Indian Soc Pedod Prev Dent* 2004;22:183-6.
24. Lukinmaa PL, Hietanen J, Anttinen J, Ahonen P. Contiguous enlarged dental follicles with histologic features resembling the WHO type of odontogenic fibroma. *Oral Surg Oral Med Oral Pathol* 1990;70:313-7.
25. Martin-Granizo R, Sanchez-Cuellar A, Falahat F. Cemento-ossifying fibroma of the upper gingivae. *Otolaryngol Head Neck Surg* 2000;122:775.
26. Endo Y, Uzawa K, Mochida Y, Nakatsuru M, Shiiba M, Yokoe H, et al. Differential distribution of glycosaminoglycans in human cementifying fibroma and fibro-osseous lesions. *Oral Dis* 2003;9:73-6.