

Can a Wisdom tooth replace a decayed molar...?

¹Dr. Dileep.S.K., MDS, Senior Lecturer, Dept. of Conservative Dentistry & Endodontics, S.V.S.Institute of Dental Sciences, Mahabubnagar, Telangana, India

²Dr Edulapalli Keerthi, PG Resident, Dept of Prosthodontics, S.V.S.Institute of Dental Sciences, Mahabubnagar, Telangana, India.

³Dr Gayathri Divya Sugavasi, PG Resident, Dept of Orthodontics, S.V.S.Institute of Dental Sciences, Mahabubnagar, Telangana, India.

⁴Major (Dr) Lakinepally Abishek, MDS, Army Dental Corps, Dept. of Conservative Dentistry & Endodontics

Corresponding Author: Dr Edulapalli Keerthi, PG Resident, Dept of Prosthodontics, S.V.S.Institute of Dental Sciences, Mahabubnagar, Telangana, India.

Type of Publication: Case Report

Conflicts of Interest: Nil

Abstract

Auto transplantation provides the possibility to function like a natural tooth rather than prosthesis or an osseointegrated implant to replace a missing tooth. The indications for auto transplantation are wide, but careful patient selection coupled with an appropriate technique is a prerequisite for a good functional and esthetic outcome. This Case report presents successful auto transplantation of a mature maxillary right third molar (18) to replace a decayed maxillary right second molar (17). After extraction of maxillary second and third molars, the third molar was re implanted into the extraction socket of second molar. Root canal therapy was done for the transplanted molar after 4 weeks. Patient was reviewed after 4 weeks, 6 months and one year clinically and radiographically which revealed satisfactory outcome with no signs or symptoms suggestive of pathology.

Keywords – auto transplantation, third molars, extraction.

Introduction

Tooth transplantation is a possible treatment option for the replacement of extracted permanent tooth that is

malformed or involved with carious destruction or traumatic injury. Although today dental implant is mostly desirable treatment method in case of lost teeth (because of its predictable and long-term results), it cannot be applied to all patients due to young age or socio-economic reasons; therefore, tooth auto-transplantation could be considered as an alternative.

Case Report

A 38-year-old male patient reported to dental clinic with chief complaint of food accumulation and pain in upper right back teeth region of jaw. Patient was apparently all right 3 months back when he noticed food accumulation in upper right side. Initially there was food accumulation but gradually turned to pain which aggravated on having hot foods. Patient gave history of undergoing root canal treatment in 17. No significant medical or familial history as elicited by patient. Clinical and radiographic examination (Fig 1) revealed caries on the distal aspect of 16 involving pulp, 17 was incompletely obturated, 18 was sound without any decay and infection. International

Normalised Ratio (INR) was done for checking any bleeding disorders.

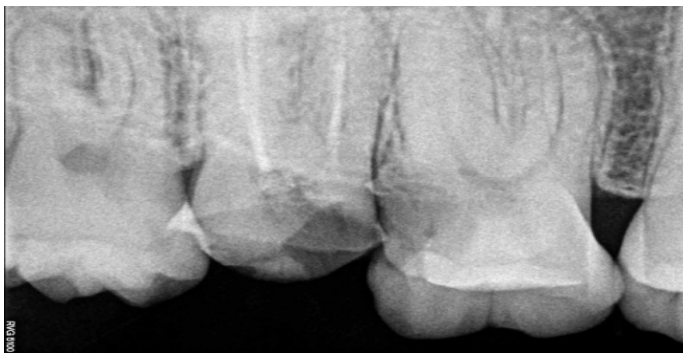

Fig-1- Pre-operative RVG

After explaining the risks and benefits of the procedure to the patient, an informed consent was taken. Patient was prescribed antibiotic coverage one hour before surgery to prevent infection. Taking into consideration socio economic status of the patient, 17 was planned for extraction and root canal treatment for 16. The mesiodistal dimensions of 17 and 18 were suitable for transplantation. Teeth 17 and 18 were extracted atraumatically (Fig 2) without damaging the

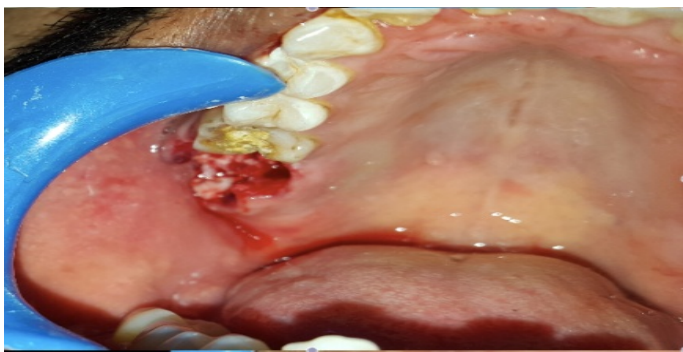

Fig-2- Extraction of tooth 17,18

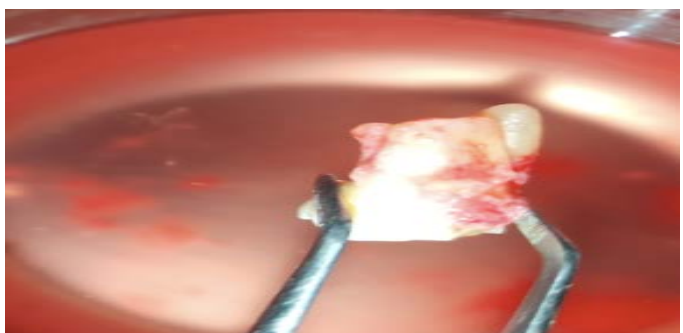

Fig-3- Extracted third molar

Non-rigid intra radicular occlusal splinting with malleable orthodontic wire was done from 15 to 18 (Fig 4,5) to stabilize the transplanted tooth. Tooth was occlusally relieved to fasten healing and prevent trauma to periodontium during healing phase. Patient was instructed to perform daily mouth rinsing with 0.12% Chlorhexidine gluconate.

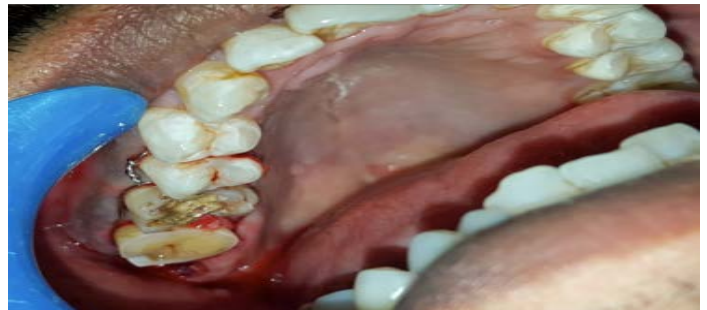

Fig-4- Intra-oral image showing autotransplantation and splinting

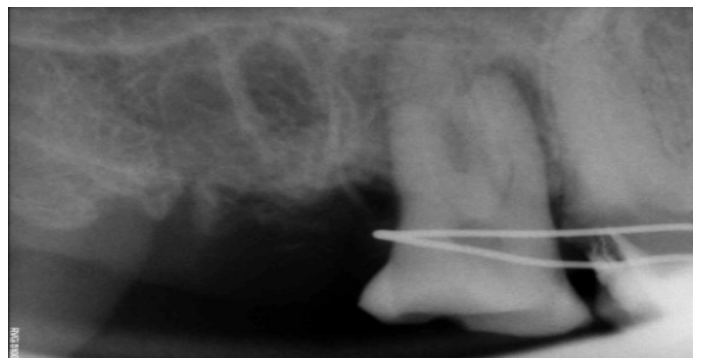

Fig-5- Immediate autotransplantation

Clinical examination after 4 weeks revealed absence of mobility, without any tenderness to percussion or signs of loss of attachment and masticatory ability was normal, splint was removed (Fig 6,7). The root canal treatment for 18 was initiated 4 weeks after transplantation.

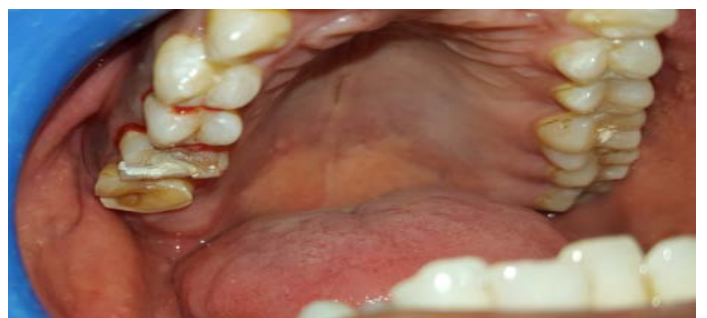

Fig-6 - 1 month post operative photograph

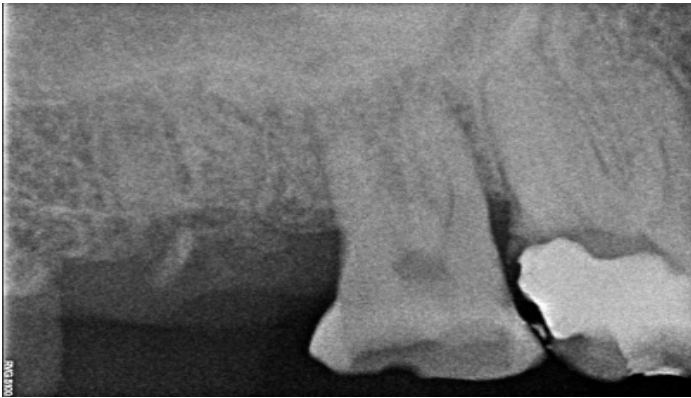


Fig-7- 1 month post operative radiograph

At the 1-year follow-up, radiographic examination revealed healing of the transplanted site (Fig 8) without any signs of root resorption and revealed normal periodontal attachment.

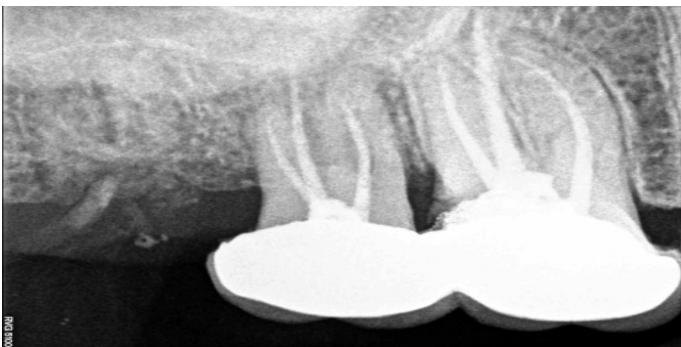

Fig-8- 1 year follow up radiograph

Discussion

Dental auto-transplantation is defined as movement of tooth from one position to another in the same person.[1,2] Autogenic transplantation of teeth was described for first time in the dental literature by the Swedish dental surgeon Vidman in 1915.[3] Patient selection is very important in dental auto-transplantation for treatment prognosis.

They must have a suitable recipient site, free from inflammation with adequate bone support and width of attached gingiva .[4] The donor tooth should be in good health, and without any anatomical variations to make extraction atraumatic, and must be of limited value in the dentition .[5,6] A transplanted third molar maintains

natural space, alveolar bone volume, and morphology through proprioceptive stimulation.[7,8]

Auto transplantation possesses many advantages in terms of function, cost, time, esthetics, and ease with which complications can be managed.[9] For fully developed donor teeth, root canal treatment should be initiated 4 weeks after transplantation. The time gap of 4 weeks is chosen to minimize trauma to PDL in the initial reattachment-healing phase, but further delay will increase the chance of complication of inflammatory resorption secondary to pulpal infection.[10]

And the answer to the title, Yes a wisdom tooth can replace a decayed molar; considering the donor and the recipient tooth criteria.

Conclusion

Patient selection is very significant for the auto transplantation success. Auto transplantation provides the possibility to function like a natural tooth. Dental transplantation has advantages like bone induction and reestablishment of normal alveolar process.

References

1. Hale ML. Autogenous transplants. Br J Oral Surg 1965;3:109–13.
2. Northway WM, Konigsberg S. Autogenic tooth transplantation. The “state of the art” Am J Orthod 1980;77:146–62.
3. Tsukiboshi M. Autogenous tooth transplantation: A reevaluation. Int J Periodontics Restorative Dent 1993;13:120-49.
4. Kugelberg R, Tegsjö U, Malmgren O. Autotransplantation of 45 teeth to the upper incisor region in adolescents. Swed Dent J 1994;18:165–72.
5. Marques-Ferreira M, Rabaça-Botelho MF, Carvalho L, Oliveiros B, Palmeirão-Carrilho EV. Autogenous tooth transplantation: Evaluation of pulp tissue

regeneration. *Med Oral Patol Oral Cir Bucal*

2011;16:984–9

6. Pabbati Ravi kumar, Mandava Jyothi .

Autotransplantation of Mandibular Third Molar: A Case Report. *Case Reports in Dentistry* 2012; 629180: 5.

7. Hernandez SL, Cuestas Carnero R. Autogenic tooth transplantation: a report of ten cases. *J Oral Maxillofac Surg* 1988; 46(12):1051–5.

8. Sven Kvint, Rune Lindsten, Autotransplantation of Teeth in 215 Patients A Follow-up Study. *Angle Orthodontist* 2010; 80(3).

9. Farheen Ustad. Autotransplantation of teeth: A Review *Am. J Med Dent Sci* 2013;1(1): 25-30.

10. Andreasen JO, Paulsen HU, Yu Z, Bayer T, Schwartz O. A long-term study of 370 autotransplanted premolars. Part II. Tooth survival and pulp healing subsequent to transplanta- tion. *Eur J Orthod* 1990;12:14–24.