

Analysis of Factors Associated With Cracked Tooth – A Review¹Dr.Riddhi Thakarshibhai Hirani, ²Dr.Renu Batra, ³Dr. Sonali Kapoor**Corresponding Author:** Dr.Riddhi Hirani , 3rd Year Postgraduate, Department of Conservative dentistry, Endodontics & Aesthetic, Manubhai Patel Dental College, Hopsital & Oral Research Institute, Vadodara.**Type of Publication:** Review Paper**Conflicts of Interest:** Nil**Abstract**

Cracked tooth syndrome (CTS) is a common occurrence in modern general practice. This article reviews the forces placed on the human dentition and the effect restorative dentistry has on the strength of tooth structure. The study reports on the incidence of CTS in a general practice, finding a far higher incidence in teeth which have had the marginal ridge restored than those which have not. To provide an overview of the clinical features, diagnosis, classification and management of cracked teeth which may be a diagnostic challenge in clinical practice

Keywords: Cracked tooth syndrome, factor affecting cracked teeth, Management.

The term ‘cuspal fracture odontalgia’ was first used by Gibbs in 1954, to describe a condition which is better now known as ‘cracked tooth syndrome’ or ‘cracked cusp syndrome’. The latter concept was coined by Cameron in 1964 who proceeded to define the condition as ‘an incomplete fracture of a vital posterior tooth that involves the dentine and occasionally extends to the pulp’ The term ‘incomplete fracture of posterior teeth’ is often used interchangeably with that of cracked tooth syndrome, while the terms ‘green-stick fracture’ or split tooth syndrome’ have also been used synonymously.⁽¹⁾ Cracked teeth are the third most common cause of tooth loss after caries and periodontal disease ^(2,3)

Cracked tooth is a very intriguing problem in dentistry. A Cracked tooth is indicative of a crack-line propagating from the occlusal surface of the tooth apically without separation of the two fragments and distinct type of longitudinal fracture which may extend though either or both the marginal ridges and proximal surfaces ⁽⁴⁾. Many morphologic, physical and iatrogenic factor predispose posterior teeth to an incomplete fracture. It can act as a pathway for bacteria that may induce pulpal and /or periapical inflammation or disease. These are usually incomplete fractures found in the crown of posterior teeth extending from an internal line angle at the floor of a restoration and often involving a marginal ridge with the fracture extending in a mesiodistal direction (Goel *et al.*, 1992) ⁽¹⁾

Incidence

The condition presents mainly in patients aged between 30 to 50 years, women being more affected than men. ⁽⁵⁾ Most commonly tooth with crack is mandibular molar followed by maxillary premolar, maxillary molar, mandibular premolar. Mandibular first molars are the first permanent teeth to erupt in to the dental arch, hence they are more prone to dental caries and subsequent restorative intervention, so they are more prone to fracture. The disto-lingual cusp of mandibular molars is the most susceptible cusp for fracture (Khera *et al.*, 1990). Nonfunctional cusps may be more capable of fracture than functional cusps. ⁽⁶⁾

This observation is based on the cusp's dimension- functional cusps are significantly larger in a bucco-lingual dimension and are covered with a thicker layer of enamel. The functional cusps are supported on the inner and outer inclines by the opposing tooth on the other hand non functional cusps may be more susceptible to fracture from lateral excursive occlusal forces originate to the lack of support from the outer incline. ⁽¹⁾

Classification

Table 1.1 ⁽⁷⁾: American Association of Endodontists classification of cracked

Several authors have proposed classifications which are generally based on either the type or location of the crack, the direction and extent of the crack, and /or the risk of symptoms and /or pathological processes. The American Association of Endodontists , in a document titled “Cracking the Cracked Tooth Code” identified five types of cracks in teeth and are briefly described in Table (1.1) . ⁽⁷⁾

Classification	Originate	Direction	Symptoms	Pulp status	Prognosis
Craze Line	Crown	Variable	None	Vital	Excellent
Fractured cusp	Crown	M-D and/or F-L	Mild and generally,only to biting and cold	Usally vital	Good
Cracked tooth	Crown±Root	M-D often central	Acute pain on biting occasionally sharp pain to cold	Variable	Questionable:Dependent on depth and extent of the crack
Split tooth	Crown± Root	M-D	Marked pain on chewing	Often root filled	Poor unless crack terminates just subgingivally
Vertical root fracture	Root	F-L	Mimics periodontal disease	Mainly root filled	Poor :Root resection in multi-rooted teeth

Craze lines are found in the majority of adult teeth and only involve enamel. In posterior teeth, craze lines are normally visible crossing marginal ridges and /or extending along buccal and lingual surfaces. Long verical craze lines are often found in anterior teeth (figure A). ^(3,7) As they only affect the enamel, they cause no pain and are of no concern beyond the aesthetic.on the examination of teeth for cracks,it is observed that most adult teeth have craze lines. ⁽⁸⁾

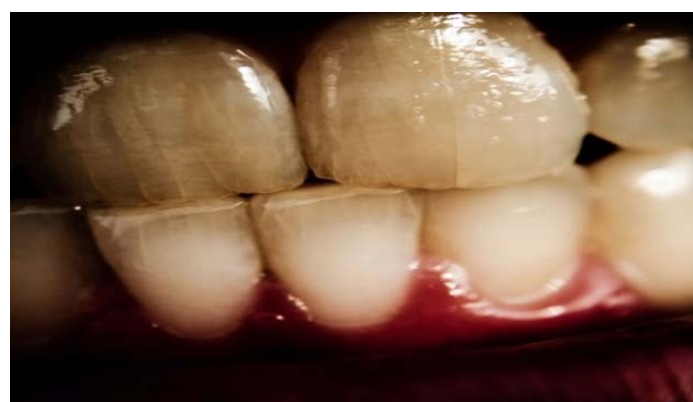

Figure 1: Craze line

Fracture cusps usually due to insufficient cusp support when the marginal ridge is weakened by an intra-coronal restorataion .The crack often extends in mesio-distal and bucco-lingual directions commonly involving one or both

marginal ridges as well as a buccal or lingual groove and terminates in the cervical region either parallel to the gingival margin or slightly subgingival.(figure 1.2).^(3,7,8)

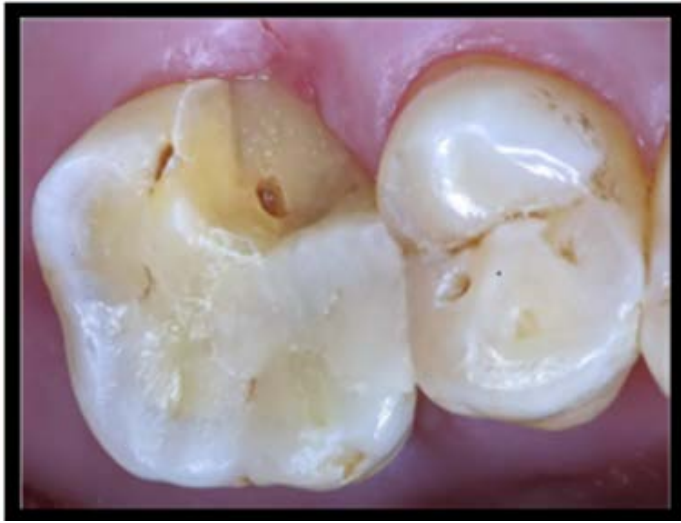

Figure 2: fracture cusps

Cracked Tooth in which crack extending from the occlusal surface of the tooth apically without separation of the two segments. It is generally located centrally in a mesio-distal direction and may involve one or both marginal ridges.^(3,7,8)

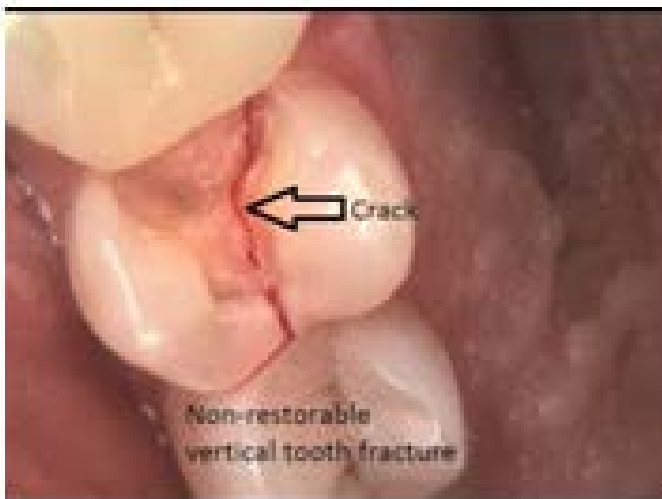


Figure 3: crack teeth

A **split tooth** in which crack extending from both marginal ridges usually in a mesio-distal direction splitting the tooth completely into two separate segments. The crack is generally located centrally in the

tooth this entity is the result of crack propagation of a cracked tooth.^(3,7,8)

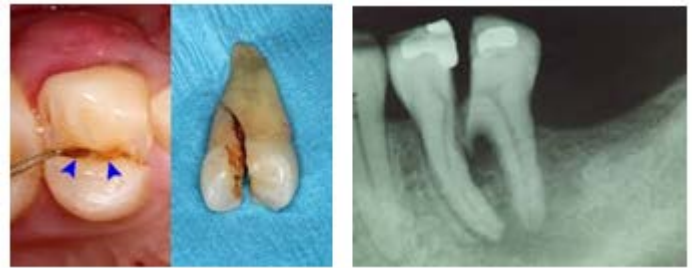

Figure 4: Split tooth

Vertical root fracture commence in the root generally in a bucco-lingual direction .The crack is generally complete though may be incomplete and involve only one surface .The crack may involve either the entire root or only a portion of the root.^(3,7,8)

Proposed classification for cracked teeth

According to Pruden⁽⁷⁾

- A. Crack line
 - 1. No separation of parts, no pain symptoms
 - 2. No apparent separation, but tooth sensitive to percussion- or patient has persistent, vague pain not definitely related to the tooth
- B. Fractured cusp
 - 1. No pain or pulp involvement
 - 2. Possible pulp involvement
- C. Fractured crown
 - 1. No pulpal involvement
 - 2. Pulp involved
- D. Fractured root tip

According to Williams

Category 1 – Incomplete vertical fracture through enamel in to dentin but not into pulp

Category 2 - Incomplete crown fracture involving the pulp

Category 3- Incomplete vertical fracture crossing the pulp

Category 4- Fracture divides the tooth completely

According to Clark et al

Type 1 crack - Little or no risk underlying pathology

Type 2 crack - Moderate risk of underlying pathology

Type 3 crack - High risk underlying pathology

Biomechanics of Cracked Tooth

A cracked tooth is primarily described as one with cracks that originate in the mesio-distal plane of the crown and progress toward the root. Previous investigations have suggested that the strength of a tooth is directly related to the amount of remaining coronal tooth structure. Hence preservation of the coronal tooth structure has been recognized to be crucial for the successful management of endodontically treated teeth. still, endodontic procedures have been shown to reduce the relative tooth stiffness by only 5%. This was less than that of an occlusal cavity preparation, which reduced the relative stiffness by 20%. The largest losses in stiffness were related to the loss of marginal ridge integrity, and mesio-occlusodistal (MOD) cavity preparation, which resulted in a 63% loss of relative stiffness.^(9,10)

However, the access cavity preparation by itself compromises the flexural integrity provided by the roof of the pulp chamber, which results in greater cuspal flexure during function. An increased cuspal flexure of the posterior teeth would ensue from greater loss of coronal dentin. Following access cavity preparation, the buccal and lingual walls of the posterior teeth are suggested to behave as a cantilever beam, flexing the cusps in a bucco-lingual direction. The repeated flexure of cusps (fatigue) associated with loading and unloading of the tooth (chewing cycles) results in mesio-distal crack that propagates from the crown to the root aspect of the tooth (cracked tooth)⁽⁹⁾

Factors Responsible For a Cracked Tooth

There are various predisposing and etiological factors responsible for a cracked tooth. The most common causes

in non-vital teeth are the over-zealous canal preparation, excessive force during canal obturation or post reinforcement of endodontically treated teeth. Meistel Lommel and Gerstein found that lateral condensation of root canal obturation was responsible for root split in 84.38% of cases.

Vital teeth presenting with cracked tooth Syndrome is found with increasing frequency in posterior teeth. Mandibular first and second molars, maxillary premolars and second molars are the most frequently involved teeth. Though the most common cause of a cracked tooth is trauma resulting from masticatory accidents like sudden impact of biting on a hard object such as a stone or a bone –piece in the food, there are several predisposing factors. Cohen and Silvestri have summarized the various causes of cracks in vital teeth. Radical preparation leading to weakening of cusps with very high speed rotary cutting instruments available and busy practice, the operating dentist may sometimes do over cutting, resulting in permanent and irreversible loss of hard dental tissues and making the tooth vulnerable to future fracture. There are two primary factors predisposing teeth to Cracks. first is. Natural predisposing factors such as the steep cusp fossa of maxillary premolars and the lingual inclination of the lingual cusps of mandibular molars second Iatrogenic factors which induced by any intervention in the dentition At the coronal level, i.e. thoughtless tooth substance removal during cavity preparation (insufficiently addressing the final structural strength and the design of the coronal restoration) stress development induced by factors related to the restorative procedure, and oral (para) function stress development in the root caused by the use of rotary root canal instruments, obturation procedure or post placement.

Delayed expansion of amalgam though preventable, manipulative errors can cause excessive delayed

expansion and if the remaining tooth structure was already weakened either due to caries or excessive cutting the tooth can crack⁽³⁾

Excessive stresses in composite resin restoration if in a large restoration ,incremental techniques is not used ,the bulk filling causes excessive polymerization shrinkage which is towards the cavity margins resulting in cracking of the tooth.

Deep carving in final restoration it can alter cusp/ fossa relation and can contribute towards fracture of a non-functional cusp like buccal cusp of maxillary and lingual cusp of mandibular posterior teeth.

Trauma from occlusion centric deflecting contacts on inclines of vulnerable cusps can cause its fracture. The wedging effect of cusp-fossa relationship can cause fracture of non-functional cusp since they are unsupported on one side.

Torque on abutment teeth terminal partial denture with precision or semi-precision attachments or abutment of an excessively long span bridge receive harmful torque forces and may result in a cracked tooth.

Cracked teeth may occur in patient without damaging parafunctional habits and who do not display heavy musculature .if these teeth are restored ,the restoration may be class I or a deep class II restorations are more likely to be cusp fractures and their effects are not as devastating.

Thermal stresses are also thought to be a cause of fractures, although the evidence of this is inconclusive. ^(1,3)

Micro cracks Caused By Rotary Instrument

Dentinal crack formation is complex, which is related not only to the design of the instrument but also to its instrument's kinematics. Specific torque limit, close to the limit of elasticity, be set for each instrument size and type. Low torque can cause fewer cracks & High torque can cause more cracks . ⁽¹¹⁾ However, mechanical instrumentation with large taper files may remove excessive dentin, exert more stress on the canal wall, and generate cracks on the dentin and the apical surface, which could lead to vertical root fractures^(12,13). During instrumentation, the contact between instruments and dentin creates many momentary stress concentrations in dentin that may cause dentinal cracks⁽¹⁴⁾

Ultrasonic and Dentinal Cracks

The problem of root-end cracking as a result of ultrasonic apical cavity preparation was first noted by Saunders et al. They found dentin cracks in 21% of roots after root-end cavity preparation by ultrasonic instrument tips and high-speed burs. ⁽¹⁵⁾

Classification	Factors	Examples
Restorative procedures	Inadequate design features Stress concentration	Over-preparation of cavities (excessive tooth removal) Deep cusp-fossa relationship Insufficient cuspal protection in inlay/onlay design Pin placement (friction lock or self-threading dentin pins) Non-incremental application of composite resins (tensile stress on cavity walls) Pressure exerted during the seating of tightly fitting cast restorations Physical forces during placement of restoration, e.g., amalgam or soft gold inlays (historical)
Occlusal factors	Masticatory trauma Trauma from occlusion Functional forces Parafunctional habits	Sudden and excessive cutting force on a piece of hard object (bone) Eccentric contacts and interferences (especially mandibular second molars) Large untreated carious lesions Cyclic forces Bruxism and bruxomania
Developmental factors	Incomplete fusion of areas of calcifications Thermal cycling Foreign body Dental instruments	Occurrence of cracked tooth syndrome in unrestored tooth or teeth with minor restorations Enamel cracks Lingual barbells High speed rotary instruments associated crazing and cracking

Mechanism of Pain

The character, duration and the stimuli of pain has important implications for both diagnosis and treatment. An understanding of the mechanism of pain will often aid in assessment of the extent and direction of the crack.

Luebke suggested the following terms to diagnose pain from a cracked tooth⁽¹⁶⁾

1. Dentin pain - A brief, sharp twinge.
2. Pulpal pain - The deep, demanding, radiating pain precipitated by thermal shock to an inflamed pulp. The pain at times may be spontaneous.
3. Periodontal pain - The aggravating throbbing of a sore tooth The pain associated with an incomplete fracture of a cusp is generally accepted to be due to the rapid movement of dentin fluid in the dentin tubules according to the “Hydrodynamic theory of dentin sensitivity” as proposed and investigated by Brännström^(16,17) Thermal changes, air, evaporation, osmotic stimuli such as sucrose, and increases in hydrostatic pressure caused by cuspal flexure as a result of occlusal forces can all act as stimuli for the rapid movement of dentin fluid. This movement stimulates A-delta nerve fibers in the vicinity of the odontoblastic processes and the pulp-dentin border, resulting in a sharp pain of short duration indicative of a vital tooth. Rebound pain, indicative of a vital tooth, is similarly explained when the pressure is released from the cusp as the tooth is free of the occlusion^(6,16,17) When bacterial toxins have infiltrated the pulp, “hyperalgesia” can result. With this condition A-delta fibers are stimulated producing a sharp pain of short duration at what appears as a lower threshold than normal. The pain is due to the rapid movement of dentin fluid and probably a result of slight pulpal inflammation. During inflammation, the stimulation threshold of the A-delta fibers is lowered^(16,17)

A second type of pulpal pain is produced by the stimulation of C-fibers as a response to inflammation, heat and mechanical deformation. A dull, poorly localized ache is often the result. Alternatively, the pain can be a dull, aching pain with a continuous throbbing nature, or arise spontaneously and last for minutes or hours.^[6,7] The C-

fibers are activated by inflammatory mediators as a result of pulpal inflammation or prolonged application of heat.⁽¹⁷⁾

Diagnosis of crack teeth

The diagnosis of a cracked tooth is often a perplexing problem. The signs and symptoms are so varied that the condition is termed as “cracked tooth syndrome”

The steps to identify a crack or fracture include

1. Tactile Examination

Scratch the surface of the tooth with the tip of a sharp explorer; the tip may catch in a crack. Palpate the gingiva around the tooth, checking for possible evidence of an underlying dehiscence or fenestration.^(3,6)



Figure 5: Tactile examination

2. Periapical Tests

Percussion is usually beneficial in determining whether a crack is present that initiates from the crown. Especially helpful is the use of angular percussion (as opposed to direct vertical percussion), which may cause separation of the crack line and stimulation of periodontal ligament fibers or fluid movement in the dentinal tubules. Palpation, while a very helpful test for other situations, is usually not beneficial in determining the existence of a crack.^(3,6)

3. Bite Tests

Use a rubber wheel, wood stick, Tooth slooth or other instrument to focus biting pressures on specific cusps to reproduce the patient's complaint (specially designed instruments are commercially available). Place the

instrument on each cusp or fossa and have the patient bite down with moderate pressure and release. Explain to the patient that they will “bite slightly, squeeze tightly, open quickly.”

Watch the patient's facial expression for response to pain upon biting pressure or release. If the patient has a painful response, ask if the pain is the same as he or she has been experiencing. Pain during biting or chewing is considered a classic symptom and may be the only conclusive evidence early in the crack's development. The absence of pain during biting, however, does not rule out the possibility of a crack.⁽¹⁸⁾

Other commercially available tools are “**Fractfinder**” and “**Tooth Slooth II**”. Ehrman et al. have advocated the use of this method as one with a higher level of sensitivity than that associated with the use of wood sticks. This helps in accurate identification of the involved cusp. The Fractfinder or Tooth slooth can be used on each individual cusp and the patient is asked to bite, thus allowing the placement of selective pressure on one cusp. If there is pain on biting or release of biting pressure, it is indicative that the cusp is cracked.^(3,6,18)

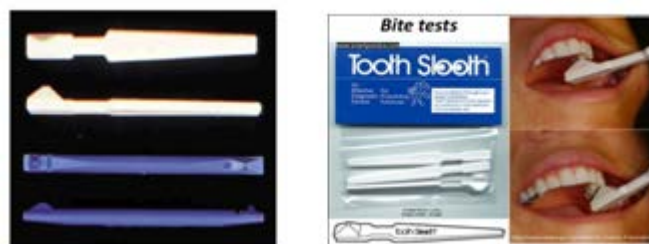

Figure 6: Tooth slooth

4. Vitality Testing

Vitality tests are usually positive. However, sometimes the affected teeth may display hypersensitivity to cold stimuli due to the presence of pulpal inflammation. Establishing pulp vitality determines the pulpal diagnosis, but has little bearing on crack detection. However, a crack that extends

to the pulp may allow bacterial contamination, which probably affects the pulp status.⁽³⁾

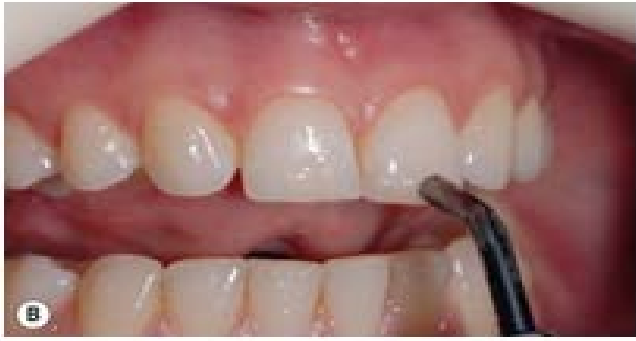

Figure 7: vitality Test

5. Periodontal Probing

Periodontal probing is important and may disclose the approximate depth and severity of the fracture. The authors advocate for eight, rather than just six, recordings of probing depths to include the mesial and distal surfaces when obtainable. Removal of interproximal restorations is helpful because it allows improved access for placement of the periodontal probe. However, subgingival fractures often do not create a probing defect. Therefore the absence of deep probing does not preclude a cracked tooth. The presence of deep probing is serious and indicates a more adverse prognosis. Thorough probing in small increments around the entire circumference of the tooth may reveal a narrow, isolated periodontal probing defect, which is characteristic of a crack. If the probe extends 8mm, then the crack extends at least 8mm. The narrow pocket that forms along a crack will restrict side-to-side motion of the probe, making it easy to differentiate from the broad-based defect characteristic of a periodontal disease pocket. Interproximal probing should be performed, especially if the crack runs in a mesiodistal direction. Interproximal restorations that are removed allow greater access to perform probing in these difficult areas.⁽¹⁹⁾

6. Dye Test

Cracks may be disclosed through staining. A dye, such as Gentian Violet or methylene blue stains can be applied to the external tooth surface, in the cavity after restoration removal or on a surgically exposed root which highlight fracture lines. The disadvantage of this technique is that it takes at least 2–5 days to be effective and may require placement of a provisional restoration. Placing a provisional restoration undermines the structural integrity of the tooth and further propagates the crack. An additional disadvantage is that a definitive esthetic restoration cannot be obtained.⁽²⁰⁾

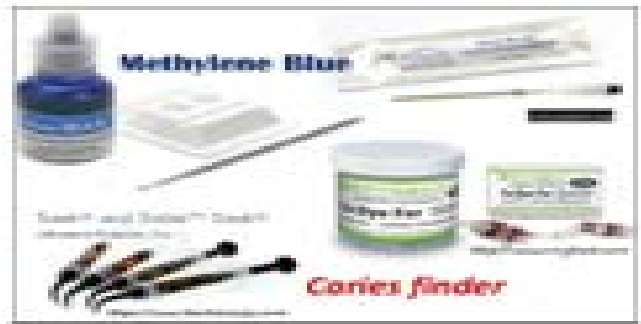

Figure 8: Dye

7. Wedging Forces

Wedging forces are used diagnostically to determine if the tooth segments are separable. Application of wedging forces is used to make this determination, but only after the patient is informed of the potential for hearing cracking noises or feeling pain. Any restorations are removed and an instrument (the flat end of a Glick Instrument or Black Spoon) is placed in the cavity with moderate pressure exerted on opposing walls to try to separate the segments. Movement of a tooth segment usually indicates significantly decreased prognosis unless determined to be a shallow cuspal fracture above the gingival attachment. Clinicians and patients may be hesitant to perform wedging of the segments for fear of splitting the tooth iatrogenically or causing pain. However, if controlled force exacerbates the crack,

certainly the tooth is predisposed to a later split anyway; the patient is best served to know this expeditiously.⁽¹⁹⁾

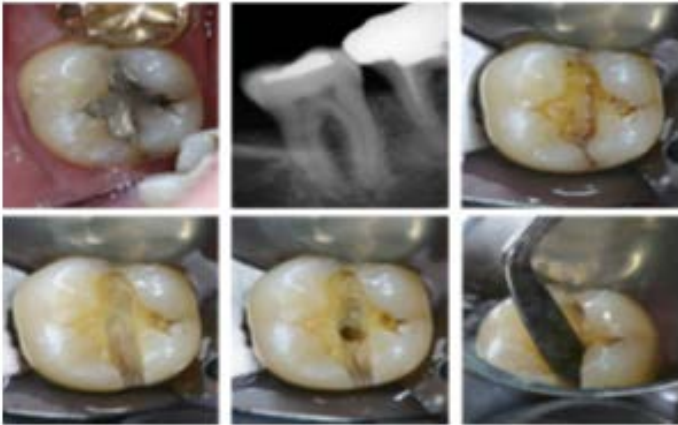

Figure 9: Wedging technique

8. Transillumination

In transillumination, a fiberoptic transilluminator or other similar light source (i.e., fiber-optic handpiece without water or a curing light) is applied directly to the tooth surface. All other light sources are eliminated, the tooth is viewed in a mirror and the light beam is positioned perpendicular to the plane of the suspected crack. A crack will block the light. Structurally sound teeth, including those with craze lines, will transmit the light throughout the tooth structure. A crack that penetrates into the dentin of the tooth will cause a disruption in the light transmission under these circumstances. Transillumination is probably the most common modality for traditional crack diagnosis. There are two drawbacks to using transillumination without magnification. First, transillumination dramatizes all cracks to the point that craze lines appear as structural cracks. Second, subtle color changes are rendered invisible. Transillumination with a fiber-optic light and use of magnification will aid in visualization of a crack.⁽⁵⁾

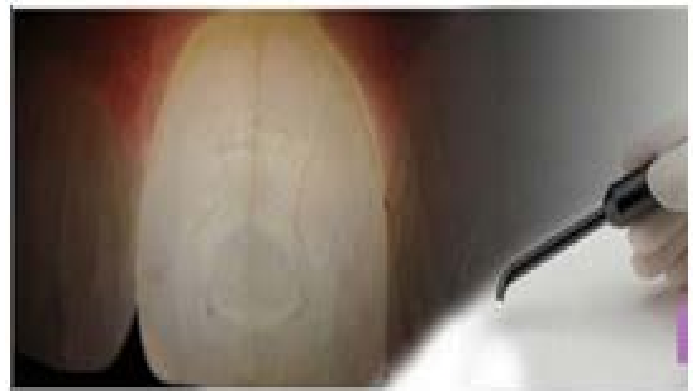

Figure 10: Transillumination

9. Infrared Thermography (Vibro IR):

This method is used for the detection of crack defects. Because when the crack is small, frictional heat is more easily produced. Thus dentinal microcracks in teeth can easily be detected on thermography. Moreover, the infrared rays used in this method would be harmless compared with x-rays. It can detect microcracks as wide as 4 to 35.5 μm that are difficult to identify with commonly used detection methods. When the crack is narrow, the area of contact between the crack surface increases. This makes it easy to generate frictional heat between the surfaces.⁽²¹⁾

10. Cone Beam Computed Tomography (CBCT)

CBCT acquires tooth images from all directions and reconstructs 3-dimensional information regarding teeth; therefore, it can be used to diagnose root fractures because it can confirm the depth and structure of fractures. However, it is impossible to confirm the microstructure of teeth due to the low resolution and the patients' need to be treated with a medical examination based on the doctor's opinion after the initial diagnosis. In general, for techniques that use radiation, the treatment process cannot be measured in real time.⁽²²⁾

11. Micro CT

Current methods for the diagnosis of cracks that may compromise teeth are all based on optical assessment, with or without the aid of surgical loupes, microscopes, dyes and/or transillumination. Optical methods suffer

from an inherent inability to assess the severity of cracks, particularly sub-surface dentinal cracks. Moreover, dentinal cracks are generally not able to be detected in plain radiographs. Micro-CT is useful for non-invasive, three-dimensional (3-D) imaging of the internal structure of mineralized tissues, due to relative differences in x-ray attenuation. BaSO₄ is precipitated within damaged tissue, cracks and vasculature, as verified by backscattered electron imaging and energy dispersive spectroscopy. Moreover, precipitated BaSO₄ enhanced the intensity of voxels in micro-CT due to the higher x-ray attenuation of BaSO₄ relative to bone tissue. The micro-CT scanner was unable to detect microcracks or fatigue cracks without the use of the contrast agent. Therefore, contrast enhanced micro-CT is expected to find increased use in the study of mineralized tissue mechanics, complementing or replacing methods of damage/ crack detection that are inherently destructive, 2-D and tedious⁽²³⁾

12. Optical coherence tomography images (OCT)

OCT has become a powerful tool in clinical and biological fields with applications involving various technologies. Some techniques measure blood flow using the optical Doppler phenomenon and observe specific material structures using the second harmonics of a measured signal to obtain border information in images with polarization OCT. Among these various derivatives, swept-source OCT (SS-OCT) is recognized as a next-generation medical imaging diagnostic technology. Studies have shown that SS-OCT has a high degree of sensitivity and specificity in detecting caries and cracks, especially when a light source with a near-infrared wavelength of 1,310 nm is used for tooth cross-section detection, because transmittance in hard tissues increases with the wavelength of the light source.^(10,11,12) OCT provides superior resolution (approximately 10 µm/pixel) in comparison with CBCT or intraoral X-ray imaging,

without a risk of radioactivity exposure. The OCT equipment is smaller than the existing radiation equipment. If a handheld probe is developed in the future, it might be possible to perform a procedure and monitor it simultaneously, improving the reliability of the treatment. Using a wavelength of 1,310 nm, OCT can acquire tomographic information from the tooth surface to the boundary between the enamel and dentin and filter out clinically.^(23,24)

13. Quantitative Light –induced Fluorescence Technology (QLF)

It is a diagnostic tool using autofluorescence of the tooth elicited during irradiation by light in the visible region (405nm). In this method teeth are dried using a cotton pellet to remove moisture and then photographed by the QLF-D device and analysed using proprietary software. The camera is positioned vertically above the teeth. A maximum fluorescence loss is automatically calculated.⁽³⁾

14. Surgical Assessment

Surgical exploration allows for visual examination of the root surface for the appearance of a crack and should only be used if the crack is highly suspected and cannot be confirmed by all other possible diagnostic means. Cracks present in a buccolingual orientation are easier to detect during surgery than those that are present in a mesiodistal orientation, since visualization is impeded by adjacent teeth. Performing diagnostic surgery, however, can help early detection of untreatable situations, sparing the need for endodontic or restorative treatment on an ultimately hopeless case. A consultation with an endodontist or periodontist may be advisable prior to surgical assessment. Whenever surgery is performed to detect a crack, the patient should be fully informed that it is an exploratory diagnostic procedure.⁽³⁾

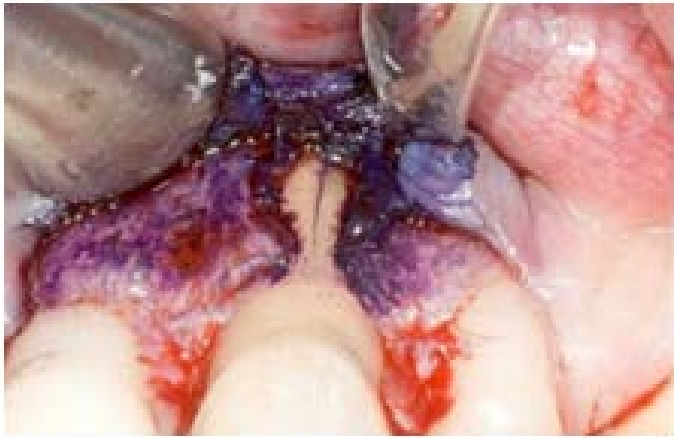

Figure 11: Surgical Assesment

Management

Coronal fracture

Management of cracked teeth should involve recognition of predisposing factors, recognition of signs and symptoms and the provision of adequate restorations that protect the tooth from fracture. Early detection is most important in the management of incomplete fracture so as to limit the propagation of the crack, subsequent microleakage and involvement of the pulpal and periodontal tissues. The treatment requirement of a cracked tooth is dependent on the position and extent of the fracture. An assessment of the stimuli, character and duration of the pain is also an influential guide for treatment. (7,25)

Cracks that enter the pulp indicate the require root canal treatment though Bader *et al*² reported that the majority of tooth fractures do not due to either pulp or tooth loss and can be managed successfully in a single visit using direct restorative materials. A multi-disciplinary approach involving endodontic, periodontic, orthodontic, prosthodontic and surgical intervention may be required. (7)

In the absence of irreversible pulpitis, many techniques have been described to bind or remove the fracture so as to prevent flexure of the cusp, crack propagation and bacterial microleakage. Definitive treatment has included

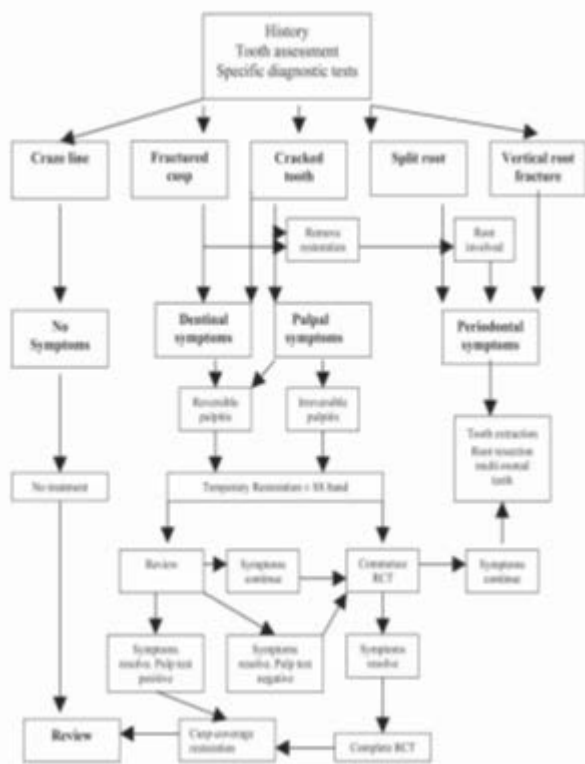pin retained amalgams, bonded amalgams, bonded composites, cusp overlay restorations, and full coverage crowns.⁽²⁶⁾

Gutmann & Rakusin suggested that treatments consist of an initial investigative and sedative stage followed by definitive treatment and restoration. Initial treatment involves the removal of all existing restorations to fully assess the extent of the fracture. Transillumination is a useful guide. In the initial diagnostic phase, the use of copper or stainless steel bands, stainless steel crowns, and acrylic resin crowns have been advocated. Placement of a sedative temporary restoration is not advised as this approach does not stabilize the fracture leaving the tooth susceptible for further extension of the crack. (7)

GICs may have a role to play in the management of cases of CTS as base materials under extensive direct composite resin fillings thereby reducing the volume of resin required and the associated levels of polymerisation shrinkage.⁽¹⁸⁾

Teeth restored with cuspal amalgam overlays had fracture energies, measured as the force required to fracture, equal to that of an intact tooth whereas gold crowns increased the fracture energy by more than three-fold. Clark & Caughman have categorized the prognosis of cracked teeth as excellent, good, poor and hopeless.⁽⁵⁾

Ceramic onlays (conventional/CAD-CAM) can be given in cases of CTS in which tooth preparation to receive the above form of restoration essentially involves the reduction of the weakened cup by 2.0 mm, followed by the placement of a chamfer/ rounded shoulder of 2 mm in width applied just beneath the prepared occlusal surface. Porcelain bonded partial coverage onlays offer a more conservative alternative to full coverage restorations for the management of CTS, with high aesthetic value. However, their application is time consuming (even with single visit restorations) and costly.



Adapted from Abbott[®]

Conclusion

The main problem for treatment of cracked tooth syndrome is the detection and identification of CTS. Every practitioner should be aware of the existence of CTS, and the condition must always be considered when a patient complains of pain or discomfort on chewing or biting.

References

1. Dr. Mini K. John, Dr. Mridula Parameshwaran, Dr. Vidhya S., Dr. Sreeja, S., Dr. Kiran and Dr. Sudheer Prabhu. cracked tooth syndrome- a review. international Journal of Recent Advances in Multidisciplinary Research Vol. 02, Issue 03, pp.0294-0297, March, 2015
2. Matthew D. Landrigan et al. Detection of dentinal cracks using contrast enhanced micro-computed tomography. Journal of the mechanical Behavior of Biomedical material 2010 (223-227)

3. Shamimul Hasan, Kuldeep Singh1, Naseer Salati. Cracked tooth syndrome: Overview of literature. International Journal of Applied and Basic Medical Research, Sep-Dec 2015, Vol 5, Issue 3
4. Christopher D. Lynch, Robert J. McConnell . The Cracked Tooth Syndrome. Journal of the Canadian Dental Association September 2002, Vol. 68, No. 8
5. Shamimul H, kuldeep S ,Naseer S.Cracked tooth syndrome: overview of literature. International journal of Applied and Basic medical Research ,sep-Dec 2015,vol 5 ,issue 3.
6. Cohen’s pathways of the pulp .Chapter-21 Cracks and fracture
7. William Kahler, Mscdent, Dclindent, Fracds. The cracked tooth conundrum: Terminology, classification, diagnosis, and management. Am J Dent 2008;21:275-282
8. Angambakkam R pradeepkumar , Arunajatesan sabbiya. Cracks and Fractures in teeth . journal of operative Dentistry and Endodontics ,January-june 2017 ;2(1): 25-30
9. Anil Kishen. Biomechanics of fractures in endodontically treated teeth. Endodontic Topics 2015, 33, 3–13
10. Tonami K, Takahashi H. Effects of aging on tensile fatigue strength of bovine dentin. Dent Mater J 1997: 16: 156–169.
11. Dane A, Capar ID, Arslan H, Akcay M, Uysal B. Effect of different torque settings on crack formation in root dentin. J Endod 2016; 42 (2): 304 – 306.
12. A: Metzger Z, Teperovich E, Zary R et al: The self-adjusting file (SAF). Part 1: respecting the root canal anatomy : a new concept of endodontic files & its implementation. J Endod 2010; 36: 679

13. B: Solomonov M. Eight months of clinical experience with the self-adjusting file system. *J Endod* 2011; 37:881
14. A Adl, MS Shams, M Majd. The effect of using RC Prep during root canal preparation on the incidence of dentinal defects. *J Endod* 2015; 41(3): 376 – 379.
15. Aydemir S, Cimilli H, Hazar Yoruç AB, Kartal N. Evaluation of two different root-end cavity preparation techniques: A scanning electron microscope study. *Eur J Dent* 2013;7:186-90
16. Jyväsjärvi E, Kniffki KD, Mengel MKC. Functional characteristics of afferent C fibres from tooth pulp and periodontal ligament. In: Hammann W, Iggo A. *Progress in brain research*. London: Elsevier, 1988;74:237-245
17. Brännström M. *Dentin and pulp in restorative dentistry*. London: Wolfe Medical Publications Ltd., 1982;47-63.
18. S. Benerji et al . Cracked tooth syndrome part 1 : aetiology and diagnosis. *British dental journal* volume 208 No. 10 may 2010
19. Eric M. Rivera & Richard E. Walton , *Longitudinal Tooth Cracks And Fractures: An Update And Review*. *Endodontic Topics* 2015, 33, 14–42
20. Sebeena Mathew, Boopathi Thangavel, Chalakuzhiyil Abraham Mathew, Sivakumar Kailasam, Karthick Kumaravadivel, Arjun Das, *Diagnosis Of Cracked Tooth Syndrome Journal Of Pharmacy And Bioallied Sciences Vol 4 August 2012 Supplement 2 - Part 2*
21. Manami Matsushita Tokugawa et al .Detection of dentinal microcracks using infrared thermography .*JOE –vol 39,Number 1, January 2013*
22. Landrigan M et al. Detection of dentinal cracks using contrast-enhanced micro-computed tomography. *J Mech Behav Biomed Mater* 2010; 3: 223 – 227.
23. Jun-Min Kim, Se-Ryong Kang, Won-Jin Yi1 . Automatic detection of tooth cracks in optical coherence tomography images. *J Periodontal Implant Sci*. 2017 Feb;47(1):41-50 .
24. himada Y, Sadr A, Sumi Y, Tagami J. Application of Optical Coherence Tomography (OCT) for Diagnosis of Caries, Cracks, and Defects of Restorations. *Curr Oral Health Rep* 2015; 2: 73–80.
25. Caryl E. Cameron. The cracked tooth syndrome: additional findings. *JADA*, Vol. 93, November 1976
26. Silvestri AR , Singh I . Treatment rationale of fractured posterior teeth .*J Am Dent Asso* 1978 ;97 :806-810