

Evaluation of Radix Entomolaris in a Kashmiri Population Using Digital RadiographyMubashir Mushtaq¹, Fayiza Yaqoob Khan²¹Department of Conservative Dentistry and Endodontics, Government Dental College and Hospital Srinagar, Kashmir, India²Department of Periodontics and Oral Implantology, Government Dental College and Hospital Srinagar, Kashmir, India**Corresponding Author:** Mubashir Mushtaq, Department of Conservative Dentistry and Endodontics, Government Dental College and Hospital Srinagar, Kashmir, India.**Type of Publication:** Original Research Paper**Conflicts of Interest:** Nil**Abstract**

Most mandibular first molars have two roots. The presence of third root in the permanent mandibular first molar is the major variant, a supernumerary root which can be found either distolingually (Radix Entomolaris) Or Distobuccally (Radix Paramolaris), both of which are rare anatomical macrostructures. Endodontic and periodontal treatment of these molars may be challenging compared with two rooted molars owing to the unusual coronal & root canal morphology and a need to modify the access cavity. There is not much data regarding the prevalence of radix entomolaris in a kashmiri population. The aim of this retrospective study was therefore to evaluate the frequency of this variant in a kashmiri population.

Key words: Radix Entomolaris, Mandibular first molar. Kashmiri population**Abbreviations:** RE- Radix Entomolaris.**Introduction**

The basic goal of root canal treatment is meticulous cleansing of the entire pulp cavity and its complete obturation with an inert filling material. Endodontic therapy requires a thorough knowledge of root canal morphology to adequately shape and clean the canal

system. Proper care and attention should be directed in identifying and negotiating extra roots and canals.

Mandibular first molar can display several anatomical variations. The majority of Caucasian Permanent mandibular first molars usually have 2 roots placed mesially and distally and 3 root canals (1,2), but variations in the number of roots and in canal morphology are not uncommon (3). The additional third root (a supernumerary root) in those permanent mandibular first molar variants that have 3 roots is typically distributed distolingually. This additional root was first described in the literature by Carabelli (4), is called the radix entomolaris [RE] (5). This extra root is typically smaller than the distobuccal root & is usually curved, requiring special attention during cleaning and shaping procedures (6).

There have been several morphometric analyses of extracted permanent mandibular first molars that were based on micro-computed tomography (micro-CT) (7-9), but it is impossible to compare the results of these studies related to gender and the bilateral occurrence of such permanent three-rooted mandibular first molars. The recent introduction of cone-beam computed tomography (CBCT) potentially provides dentistry with a practical tool for non-invasive and 3-dimensional (3D) reconstruction

imaging for use in endodontic applications and morphologic analyses (10, 11-13). The application of CBCT can determine the exact position of the distolingual root of the permanent mandibular first molars.

There has not yet been any studies/case reports of this morphological variant in Kashmiri population which has a majority of non-mongoloid Caucasian population. Because of the lack of research on this macrostructure in Kashmiri population thorough knowledge of its occurrence and location are important. The aim of this retrospective study was therefore to evaluate the frequency of radix entomolaris in a kashmiri population diagnosed by routine digital radiography.

Material and methods

The study was conducted jointly in the departments of conservative dentistry and endodontics and Periodontics. A total of 700 patients (360 males and 340 females) were included in the study. The criteria for inclusion in the study were:

- Age >18 years
- Presence of atleast one mandibular molar in the mouth.
- Kashmiri origin patients

Thirteen hundred and eighty mandibular first molars were evaluated using full mouth digital radiographs(Schick technologies, NY, USA) using mesial angulation of 20- 30 degree. The digital radiographs were evaluated by atleast two observers. The criteria for radix entomolaris was clear visualization of an extra root(figs 1,2,3,4).

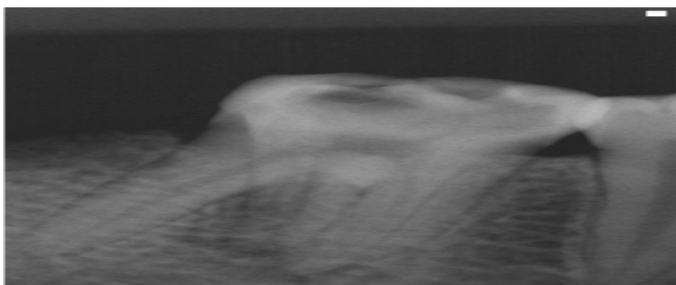


Figure 1

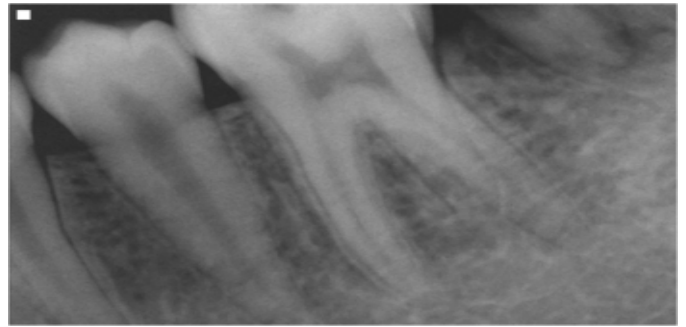


Figure 2

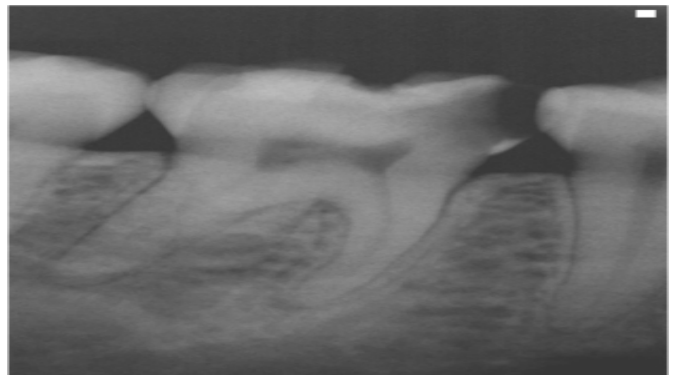


Figure 3

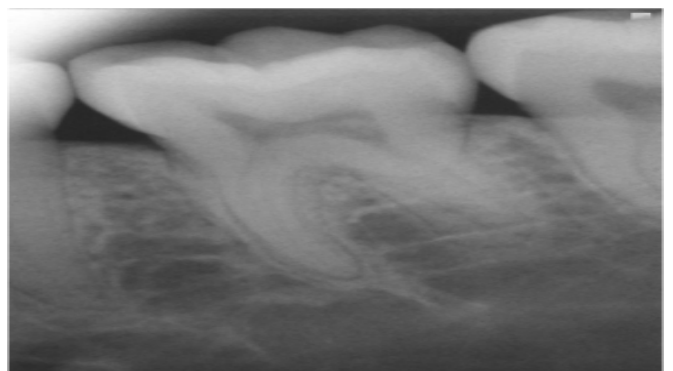


Figure 4

The data was subjected to statistical analysis using SPSS software(SPSS Chicago IL, Version 12.0)

Results

Seven hundred subjects comprising 340 males and 360 females were included in this retrospective study. A total of 1380 mandibular first molars of this study sample were evaluated. Nineteen subjects were found to have RE with the prevalence being 2.20%, the number of bilaterally occurring REs were not significantly higher than unilateral Res(table 1). The prevalence of RE in all first

mandibular molars was 1.81%,(table 2) the females had a higher prevalence than males.

Table 1

	Total number of subjects	Total subjects with RE	
Females	340	12	2.68
Males	360	7	1.84
Total	700	19	2.20
χ^2	0.651	0.007	0.439
p	0.431	0.941	0.518

Table 2

	Number of teeth		
Female	680	15	2.10
Male	700	12	1.89
Total	1380	27	1.81

Discussion

The presence of a third root (RE) in mandibular first molar is associated with certain ethnic groups. The maximum frequency of RE in African population is 3 % (7). While in Eurasian and Indian populations the frequency is less than 5 % (8).In populations with mongoloid traits (such as the Chinese, Eskimos and American Indians) reports have noted that the RE occurs with a frequency that ranges from 5% to more than 30% (8-14). In Caucasians, the RE is not very common and occurs with a frequency of 3.4 to 4.2% (15, 16), and is considered to be unusual or dysmorphic root morphology. This study reported prevalence of 2.20% OF RE in akashmiri population.The mechanism of formation of RE is still unclear. In dysmorphic, supernumerary roots, its formation could be related to external factors during odontogenesis, or to penetrance of an atavistic gene or polygenic system (atavism is the reappearance of a trait after several generations of absence).In eumorphic roots, racial genetic

factors influence the more profound expression of a particular gene that results in the more pronounced phenotypic manifestation (13,17). Curzon suggested that the “three rooted molar” trait has a high degree of genetic penetrance as its dominance was reflected in the fact that the prevalence of the trait was similar in both pure Eskimos and Eskimos/Caucasian mixes (18).

An RE can be found on the first, second and third mandibular molar, occurring least frequently on the second molar (19). Some studies report a bilateral occurrence of the RE from 50 to 67% (12,20).

Radix Entomolaris may present the clinician with a lot of difficulties during endodontic treatment. An accurate diagnosis of these extra roots can avoid a lot of procedural errors or a missed canal during root canal treatment. RE is mostly situated in the same bucco-lingual plane as the distobuccal root; a superimposition of both roots can appear on the preoperative radiograph, resulting in an inaccurate diagnosis. To reveal the RE, a second radiograph should be taken from a more mesial/distal angle [30 degree]. This way an accurate diagnosis can be made in the majority of cases.

The presence of RE has a lot of clinical implications when an access cavity preparation is done. The root canal orifice of RE is situated disto to mesiolingually from the main canal or canals in the distal root. An extension of the triangular opening cavity to the (disto) lingual side results in a more rectangular or trapezoidal outline form (21). A thorough inspection of the pulp chamber floor and wall, especially in the distolingual region should be done to search for the root canal orifice of RE. Sophisticated visual aids such as magnification loupes, intra oral camera or dental operating microscope can be valuable tool for finding these extra root canal orifices.

The calcification which is often situated above the orifice of an RE, has to be removed for a better view and access

to the RE. However, to avoid procedural errors in the coronal third of a severe curved root care should be taken not to remove excessive amount of dentin on the lingual side of the cavity and orifice of the RE (21). The use of flexible nickel-titanium rotary files allows a more centred preparation shape with restricted enlargement of the coronal third and orifice relocation. Nevertheless, unexpected complications such as instrument separation do occur, & are more likely to happen in an RE with severe curvatures or narrow root canals. Therefore, after relocation and enlargement of the orifice of the RE, initial root canal exploration with small files (size 10 or less) together with radiological length and curvature determination and the creation of a glide path before preparation are step-by- step actions that should be taken to avoid procedural errors.

Conclusion

Clinicians should have a thorough knowledge of the several anatomical variations seen in case of mandibular first molars. An accurate diagnosis of a Radix Entomolaris before root canal treatment is important to facilitate the endodontic procedure, and to avoid missed canals. Preoperative periapical radiographs, exposed at two different horizontal angles (mesial/distal) are required to identify these additional roots. A thorough knowledge about the anatomy and location of this additional root and its root canal orifice will result in a modified access cavity preparation with a distolingual extension. There should be proper understanding about the morphological variations seen in case of mandibular first molars and an adapted clinical approach to avoid/overcome procedural errors during endodontic treatment.

References

1. Barker BC, Parson KC, Mills PR, Williams GL. Anatomy of root canals. III. Permanent mandibular molars. *Aust Dent J* 1974;19:403–13.

2. Vertucci FJ. Root canal anatomy of the human permanent teeth. *Oral Surg Oral Med Oral Pathol* 1984;58:589–99.
3. Vertucci FJ. Root canal morphology and its relationship to endodontic procedures. *Endod Topics* 2005;10:3-29.
4. Carabelli G. *Systematisches Handbuch der Zahnheilkunde*, 2nd ed. Vienna: Braumullerund Seidel, 1844:114.
5. Bolk L. Bemerkungen über Wurzelvariationen am menschlichen unteren Molaren. *Zeitung für Morphologie und Anthropologie* 1915;17:605–10.
6. Vertucci FJ, Haddix JE, Britto LR. Tooth morphology and access cavity preparation. In: Cohen S, Hargreaves KM, eds. *Pathways of the pulp*. 9th ed. St Louis: CV Mosby;2006:149-232
7. Sperber GH, Moreau JL. Study of the number of roots and canals in Senegalese first permanent mandibular molars. *Int Endod J* 1998;31:112-6.
8. Tratman EK. Three rooted lower molars in man and their racial distribution. *Br Dent J* 1938;64:264-74.
9. Pedersen PO. The East Greenland Eskimo dentition. Numerical variations and anatomy. A contribution to comparative ethnic odontography. *Copenhagen: Meddeleser om Gronland* 1949;104:140-4.
10. Turner GG 2nd. Three-rooted mandibular first permanent molars and the question of Am Indian origins. *Am J Phys Anthropol* 1971;34:229-41.
11. Curzon MEJ, Curzon AJ. Three-rooted mandibular molars in the Keewatin Eskimo. *J Can Dent Assoc* 1971;37:71-2.
12. Yew SC, Chan K. A retrospective study of endodontically treated mandibular first molars in a Chinese population. *J Endod* 1993;19:471-3.

13. Reichart PA, Metah D. Three-rooted permanent mandibular first molars in the Thai. *Community Dent Oral Epidemiol* 1981;9:191-2.
14. Walker T, Quakenbush LE. Three rooted lower first permanent molars in Hong Kong Chinese. *Br Dent J* 1985;159:298-9.
15. Curzon ME. Three rooted mandibular molars in English Caucasians. *J Dent Res* 1973;52:181.
16. Ferraz JA, Pecora JD. Three rooted mandibular molars in patients of Mongolian, Caucasian and Negro origin. *Braz Dent J* 1993;3:113-7.
17. Rebeiro FC, Consolaro A. Importancia clinica y antropologica de la raiz distolingual en los molars inferiors permanents. *Endodoncia* 1997;15:72-8.
18. Curzon ME. Miscegenation and the prevalence of three-rooted mandibular first molars in the Baffin Eskimo. *Community Dent Oral Epidemiol* 1974;2:130-1.
19. Visser JB. Beitrag zur Kenntnis der menschlichen Zahnwurzelformen. Hilversum:Rotting 1948;49-72.
20. Steelman R. Incidence of an accessory distal root on mandibular first permanent molars in Hispaniv children. *J Dent Child* 1986;53:122-3.
21. Calberson FL, De Moor RJ, Deroose CA. The Radix Entomolaris and Paramolaris: clinical approach in endodontics. *J Endod* 2007;33(1):58-63.