

Corticotomy and Orthodontics: A Review

¹Dr. Shubhangi Mani, ²Dr. Nilesh Mote, ³Dr. Amit Mani, ⁴Dr. N. G. Toshniwal, ⁵Dr. Devdatta Wankhade

¹Professor, Department of Orthodontics and Dentofacial Orthopedics, Rural Dental College, Loni, Maharashtra, India.

²Professor, Department of Orthodontics and Dentofacial Orthopedics, Rural Dental College, Loni, Maharashtra, India.

³Professor and Head of the Department, Department of Periodontology and Implantology, Rural Dental College, Loni, Maharashtra, India.

⁴Professor and Head of the Department, Department of Orthodontics and Dentofacial Orthopedics, Rural Dental College, Loni, Maharashtra, India.

⁵PG Student, Department of Orthodontics and Dentofacial Orthopedics, Rural Dental College, Loni, Maharashtra, India.

Corresponding Author: Dr. Devdatta Wankhade , PG Student, Department of Orthodontics and Dentofacial Orthopedics, Rural Dental College, Loni, Maharashtra, India.

Type of Publication: Review Paper

Conflicts of Interest: Nil

Abstract

Corticotomy is found to be effective in accelerated orthodontic treatment. The most important factor in the success of this technique is proper case selection and careful surgical and orthodontic treatment. Corticotomy facilitated orthodontics is advocated for comprehensive fixed orthodontic appliances in conjunction with full thickness flaps and labial and lingual corticotomies around teeth to be moved. It is an established and efficient orthodontic technique that has recently been studied in a number of publications. It has gradually gained popularity as an adjunct treatment option for the orthodontic treatment of adults. It involves selective alveolar decortication in the form of decortication lines and dots performed around the teeth that are to be moved. Bone graft should be applied directly over the bone cuts and the flap sutured in place. Tooth movement should be initiated two weeks after the surgery, and every two weeks thereafter by activation of the orthodontic appliance. Orthodontic treatment time with this technique will be

reduced to one-third the time of conventional orthodontics. Though corticotomy facilitated orthodontics is a promising procedure only few cases are reported in the literature. Controlled clinical and histological studies are needed to understand the biology of tooth movement with this procedure, the effect on teeth and bone, post-retention stability, measuring the volume of mature bone formation, and determining the status of the periodontium and roots after treatment. This technique has several advantages, including faster tooth movement, shorter treatment time, safer expansion of constricted arches, enhanced post-orthodontic treatment stability and extended envelope of tooth movement. The aim of this article is to present a comprehensive review of the literature, clinical techniques, indications, contraindications, complications and side effects.

Keywords: Corticotomy, decortication, review, orthodontic treatment.

Introduction

An increasing number of adult patients are seeking orthodontic treatment.¹ It is noticed that there are several psychological, biological and clinical differences between the orthodontic treatment of adults and adolescents.

Dental arch crowding is one of the most common form of malocclusion. Two conventional methods to resolve dental arch crowding through orthodontics are extraction and non-extraction. Extraction as a remedy for dental arch crowding is usually reserved for moderate to severe conditions. Nonextraction therapy is usually used to resolve mild to moderate crowding and usually results in proclination of the incisors.

One of the main disadvantages of orthodontic treatment is time. Most of conventional orthodontic treatments require more than one year to complete. Unfortunately many potential orthodontic patients jeopardize their dental health and decline treatment, due to this long treatment times.

Adults have more specific objectives and concerns related to facial and dental aesthetics, the type of orthodontic appliance and the duration of treatment. Growth is an almost insignificant factor in adults compared to children, and there is increasing chance that hyalinization will occur during treatment.² In addition, cell mobilization and conversion of collagen fibers is much slower in adults than in children. Finally, adult patients are more prone to periodontal complications since their teeth are confined in non-flexible alveolar bone.² These considerations make orthodontic treatment of adults different and challenging as well as necessitate special concepts and procedures, such as the use of invisible appliances, shorter periods of treatment, the use of lighter forces and more precise tooth movements.

The evidence of the success of corticotomy as an adjunct to orthodontic treatment has not been well documented,

and few published reports are available. The aim of this article is to present a comprehensive review of the literature, including the contemporary clinical techniques, indications, contraindications, complications and side effects.

The development of corticotomy-assisted orthodontic treatment (CAOT) opened doors and offered solutions to many limitations in the orthodontic treatment of adults. This method claims to have several advantages. These include a reduced treatment time, enhanced expansion, differential tooth movement, increased traction of impacted teeth and, finally, more post-orthodontic stability.

Historical Background

Corticotomy facilitated orthodontics has been employed in various forms over the past to speed up orthodontic treatments. It was firstly introduced in 1959 by Kole as a mean for rapid tooth movement. He believed that the main resistance to tooth movement was the cortical plates of bone and by disrupting its continuity, orthodontics could be completed in much less time than normally expected. Kole's procedure involves the reflection of full thickness flaps to expose buccal and lingual alveolar bone, followed by interdental cuts through the cortical bone and barely penetrating the medullary bone (corticotomy style). The subapical horizontal cuts were connected interdentally, penetrating the full thickness of the alveolus. He suggested that since the blocks of bone was being moved rather than the individual teeth, the root resorption would not occur and retention time will be minimized. Because of the invasive nature of Kole's technique, it was not difficult to understand why it was never widely accepted.

Duker (1975) used Kole's basic technique on beagle dogs to investigate how rapid tooth movement with corticotomy affects the vitality of the teeth and the marginal periodontium. The health of the periodontium were

preserved by avoiding the marginal crest bone during corticotomy cuts. It was concluded that neither the pulp nor the periodontium was damaged following orthodontic tooth movement after corticotomy surgery (Duker, 1975). The results helped to substantiate the belief regarding the health of crestal bone in relation to the corticotomy cuts. Design of the subsequent techniques has taken this into consideration; the interdental cuts are always left at least 2 mm short of the alveolar crestal bone level.³

Frost found a direct correlation between the severity of bone corticotomy and/or osteotomy and the intensity of the healing response, leading to accelerated bone turnover at the surgical site. This was designated “Regional Acceleratory Phenomenon” (RAP). RAP was explained as a temporary stage of localized soft and hard-tissue remodeling that resulted in rebuilding of the injured sites to a normal state through recruitment of osteoclasts and osteoblasts *via* local intercellular mediator mechanisms involving precursors, supporting cells, blood capillaries and lymph.⁴ This accelerated remodeling is influenced by bone density and the hyalinization of the periodontal ligament (PDL).⁴⁻⁸

Contemporary Clinical Techniques

A more recent surgical orthodontic therapy was introduced by Wilcko et al. which included the innovative strategy of combining corticotomy surgery with alveolar grafting in a technique referred to as Accelerated Osteogenic Orthodontics (AOO) and more recently to as Periodontally Accelerated Osteogenic Orthodontics (PAOO). This technique advocated for comprehensive fixed orthodontic appliances in conjunction with full thickness flaps and labial and lingual corticotomies around teeth to be moved. Bone graft consisting of demineralized freeze-dried bone and bovine bone with clindamycin was applied directly over the bone cuts and the flap was sutured in place. Tooth movement was initiated two weeks

after the surgery, and every two weeks thereafter by activation of the orthodontic appliance. Wilcko et al. reported that this technique will reduce treatment time to one-third the time of conventional orthodontics. Alveolar augmentation of labial and lingual cortical plates were used in an effort to enhance and strengthen the periodontium, reasoning that the addition of bone to alveolar housing of the teeth, using modern bone grafting techniques, ensures root coverage as the dental arch expanded. They advocated using the PAOO for treatment of moderate to severely crowded Class I and Class II. Several reports indicated that this technique is safe, effective, extremely predictable, associated with less root resorption and reduced treatment time, and can reduce the need for orthognathic surgery in certain situations.^{9,10,11,12}

Corticotomy Facilitated Orthodontics V/S Conventional Orthodontic Treatment

Corticotomy surgery initiates and potentiates normal healing process (Regional Acceleratory Phenomena). Regional Acceleratory Phenomena (RAP) is a local response to a noxious stimulus. It describes a process by which tissue forms faster than the normal regional regeneration process. By enhancing the various healing stages, this phenomenon makes healing occur 2–10 times faster than normal physiologic healing. The RAP begins within a few days of injury, typically peaks at 1–2 months, usually lasts 4 months in bone and may take 6 to more than 24 months to subside.^{9,10}

A recent histological study showed that selective alveolar decortication induced increased turnover of alveolar spongiosa. The surgery results in a substantial increase in alveolar demineralization, a transient and reversible condition. This will results in osteopenia (temporary decrease in bone mineral density). The osteopenia enables rapid tooth movement because teeth are supported by and moved through trabecular bone. As long as tooth

movement continues, the RAP is prolonged. When RAP dissipates, the osteopenia disappears and the radiographic image of normal spongiosa reappears. When orthodontic tooth movement is completed, an environment is created that favors alveolar re-mineralization.

Technique Of Periodontally Accelerated Osteogenic Orthodontics^{12,13}

Orthodontic appliances are better to be placed one week prior to the surgery. Standard brackets, archwires, and normal orthodontic force level can be used after proper case selection. Surgery can be done in a normal clinical setting with or without sedation. Clinic preparation should follow the same protocol used for any oral surgical procedures. After administration of local anesthesia, crevicular incision is made buccally and lingually extending at least two to three teeth beyond the area to be treated. Full thickness (mucoperiosteal) flap is reflected on both buccal and lingual aspects beyond the apices of the teeth if possible (**Fig. 1a and b**). Care should be exercised not to damage any of the neurovascular bundles exiting the bone and not to disturb muscle attachments. Any interdental papillary tissue remaining interproximally should be left in place. After flap reflection, selective decortications can be performed on both buccal and lingual sides. Vertical corticotomy cuts are made between the roots using a diamond round bur (size 2) stopping just short of the alveolar crest (about 3 mm). These cuts are connected beyond the apices of the teeth (when possible) with a scalloped horizontal cuts. Cortical perforation can be made at selective areas to increase blood supply to the graft material (**Fig. 2**). Care should be taken not to injure the anterior loop of the inferior alveolar nerve that could extend several millimeters mesial to the mental foramen and be positioned just beneath the buccal cortical plate.

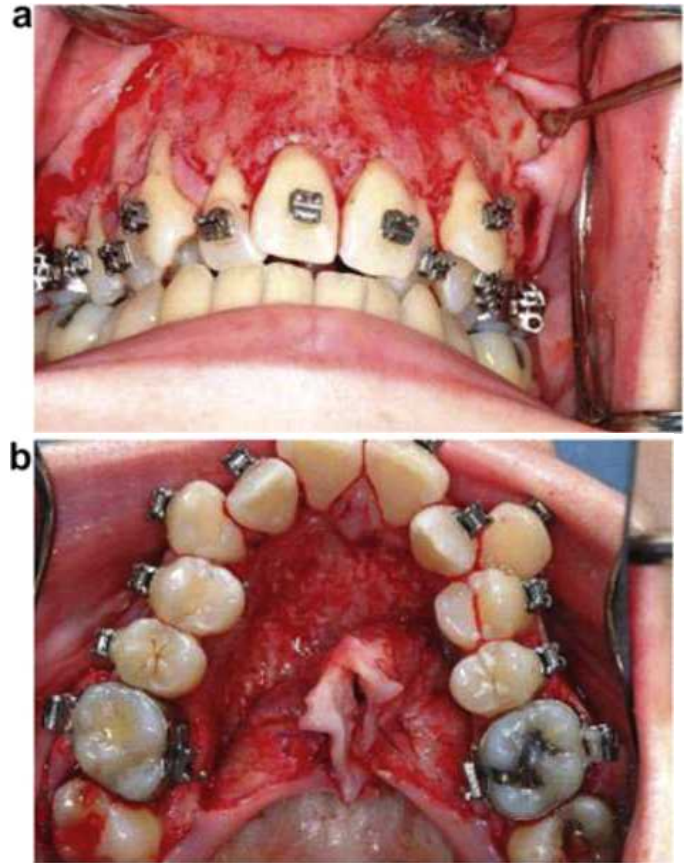


Figure 1: (a, b) Full thickness flap is reflected on both buccal and lingual aspects beyond the apices of the teeth.

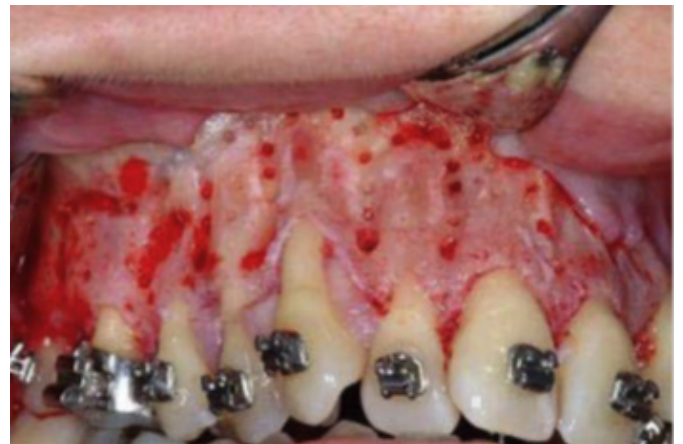

Figure 2: Vertical corticotomy cuts are made between the roots stopping just short of alveolar crest. The cuts are connected beyond the apices of the teeth with scalloped horizontal cuts and cortical perforations are made at selective areas.

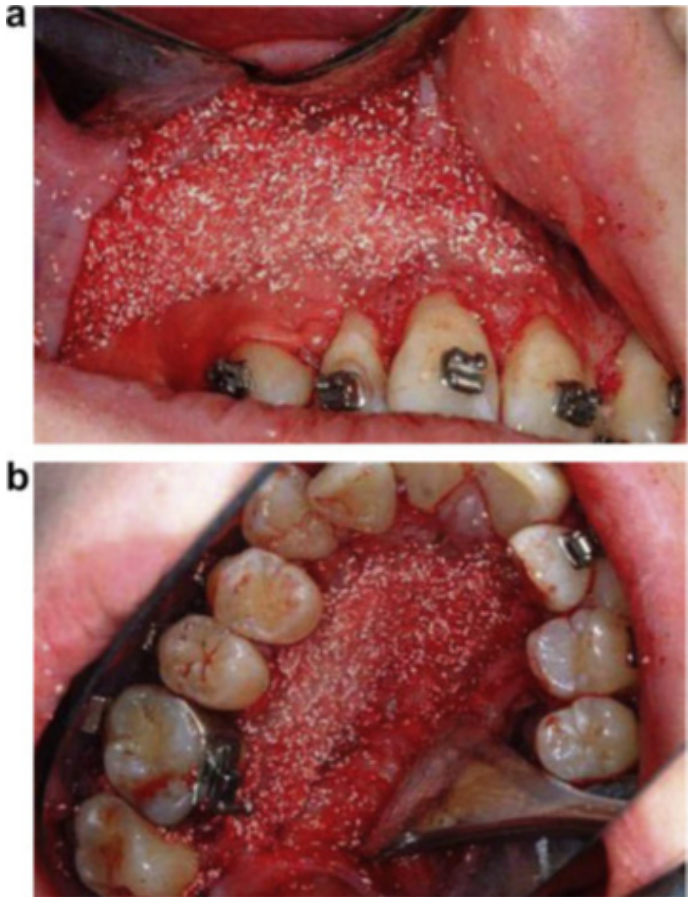


Figure 3 (a, b) Bone graft materials are placed over the decorticated areas.

Bone graft materials [Autograft, mix of Autograft + Allograft, Allograft + Xenograft, or Xenograft + Alloplast] are then placed over the decorticated areas (**Fig. 3a and b**). Antibiotics can be mixed with bone graft. Wilcko et al. recommended the use of mix of demineralized freeze-dried bone and bovine bone with clindamycin. Care should be taken not to place an excessive amount of bone graft which might interfere with flap placement. If there is any recession in the teeth, it can be treated at the same time with connective tissue graft or acellular dermal matrix allograft (AlloDerm) (**Fig. 4**).

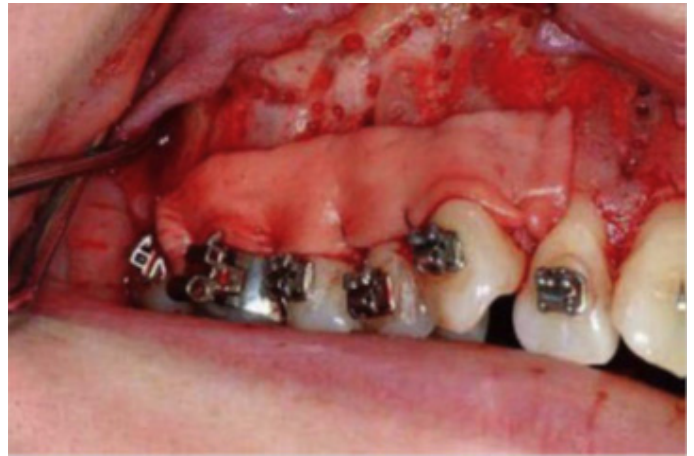

Figure 4 Soft tissue graft (acellular dermal matrix allograft in this case) can be used simultaneously with corticotomy to treat recession.

The mucoperiosteal flap is then sutured with interrupted 4-0 suture being careful to preserve the interdental papillae. Postsurgical instructions are the same as any standard oral surgical procedures. Antibiotics, analgesics, and antiseptic mouthwash should be given to the patient. The sutures are removed after two weeks.

Two weeks post-surgery, accelerated orthodontic treatment can be resumed. The intervals for orthodontic adjustments averaged two weeks, ranging from 1 to 3 weeks. During orthodontic treatment, the patient should be in 3 months recall visits to the periodontist to assess the oral hygiene and assure good periodontal health.

Indications And Clinical Applications

Several clinical applications for PAOO have been reported. Corticotomy was used to facilitate orthodontic tooth movement and to overcome some shortcomings of conventional orthodontic treatment, such as the long required duration, limited envelope of tooth movement and difficulty of producing movements in certain directions. These applications include the following:

1. Resolve Crowding and Shorten Treatment Time

Corticotomy and osteotomy were used in orthodontics primarily to resolve crowding in a shorter period of time. It has been shown that corticotomy is efficient in reducing the treatment time to as little as one-fourth the time usually required for conventional orthodontics⁹. Wilcko published a report about two adult patients with severe crowding who were treated *via* AOO in just 6.5 months⁹. A reduced chance of root resorption, less oral hygiene-related enamel decalcification and better patient cooperation and acceptance are possible advantages when lengthy orthodontic treatment is avoided.^{9,14}

2. Accelerate Canine Retraction after Premolar Extraction

Canine retraction after premolar extraction is a lengthy step during the extraction stage of orthodontic treatment. Canine retraction was accelerated by corticotomy in two animal studies. Both studies demonstrated faster canine retraction when compared to conventional orthodontic retraction of the canines.^{15,16}

3. Enhance Post-Orthodontic Stability

Stability after orthodontic treatment may not always be achievable. Little has shown that 10 years after orthodontic treatment, only 30% of patients had satisfactory alignment of the mandibular incisors. Stability was reported as one of the advantages of corticotomy-assisted orthodontics. Corticotomy-facilitated orthodontic treatment was found to result in better retention compared to conventional orthodontic treatment. The improved stability was attributed to the increased turnover of tissues adjacent to the surgical site.^{17,18}

4. Facilitate Eruption of Impacted Teeth

Surgical traction of impacted teeth, especially the canines, is a frustrating and lengthy procedure. A study by Fischer showed that under the same periodontal conditions, the corticotomy-assisted approach produced faster tooth

movement during traction of palatally impacted canines compared to conventional canine traction methods at the end of either treatment.¹⁹

5. Facilitate Slow Orthodontic Expansion

A limited number of successful techniques is available for the treatment of maxillary arch constriction; these include surgically-assisted rapid palatal expansion (SARPE) and slow palatal expansion. These techniques are aggressive in nature and less accepted by patients. The presence of non-growing alveolar bone that confines the teeth in the predetermined space available in the alveolus limits transverse tooth movement.¹⁹⁻²¹

6. Molar Intrusion and Open Bite Correction

PAOO has also been used in the treatment of severe anterior open bite in conjunction with skeletal anchorage. Moon *et al.* achieved sufficient maxillary molar intrusion (3.0 mm intrusion in two months) using corticotomy combined with a skeletal anchorage system with no root resorption and with no patient compliance required. Olivieria *et al.* also reported 4 mm of molar intrusion in 2.5 months using corticotomy in one patient and 3 to 4 mm in 4 months in another patient. Hawang and Lee demonstrated intrusion of supra-erupted molars using corticotomy, full-time use of magnetic appliances and night-time use of a vertical-pull chin-cup.²²⁻²⁵

7. Manipulation of Anchorage

PAOO was used in the treatment of bimaxillary protrusion as an adjunct to manipulate skeletal anchorage without any adverse side effects in only one-third of the regular treatment time.²⁶

PAOO was also used to achieve molar distalization. After performing segmental corticotomy around the molars, the anchorage value and resistance of the molars to distal movement were effectively reduced without the use of any extra anterior anchorage devices.^{26,27}

Contraindications And Limitations

Patients with active periodontal disease or gingival recession are not good candidates for PAOO. In addition, PAOO should not be considered as an alternative for surgically assisted palatal expansion in the treatment of severe posterior cross-bite. CAOT also should not be used in cases where bimaxillary protrusion is accompanied with a gummy smile, which might benefit more from segmental osteotomy.²⁸

Complications And Side Effects

Although PAOO may be considered a less-invasive procedure than osteotomy-assisted orthodontics or surgically assisted rapid expansion, there have still been several reports regarding adverse effects to the periodontium after corticotomy, ranging from no problems to slight interdental bone loss and loss of attached gingiva, to periodontal defects observed in some cases with short interdental distance. Subcutaneous hematomas of the face and the neck have been reported after intensive corticotomies. In addition, some post-operative swelling and pain is expected for several days.²⁶

No effect on the vitality of the pulps of the teeth in the area of corticotomy was reported. Long-term research on pulpal vitality after rapid movement has not been evaluated in the literature. In an animal study, Liou *et al.* demonstrated normal pulp vitality after rapid tooth movement at a rate of 1.2 mm per week. However, pulp vitality deserves additional investigation.

It is generally accepted that some root resorption is expected with any orthodontic tooth movement. An association between increased root resorption and duration of the applied force was reported. The reduced treatment duration of PAOO may reduce the risk of root resorption. Ren *et al.* reported rapid tooth movement after corticotomy in beagles without any associated root resorption or irreversible pulp injury. Moon *et al.* reported

safe and sufficient maxillary molar intrusion (3.0 mm intrusion in two months) using corticotomy combined with a skeletal anchorage system with no root resorption. Long-term effect of PAOO on root resorption requires further study.^{18,29}

Advantages

- Reduced treatment time: this technique will reduce treatment time to one-third the time of conventional orthodontics.¹²
- Less root resorption due to decreased resistance of cortical bone.^{12,13}
- More bone support due to the addition of bone graft.¹³
- History of relapse reported to be very low.¹²
- Less need for extra-oral appliances and headgear.¹²
- The technique has its roots in orthodontic research and treatments.^{11,12}
- In the ten years since PAOO was first applied, the patients' outcomes were good.^{11,12}
- It can be used to expedite the rate of movement of individual teeth or dental segments, i.e. canine (Fig. 5) and incisor retraction.

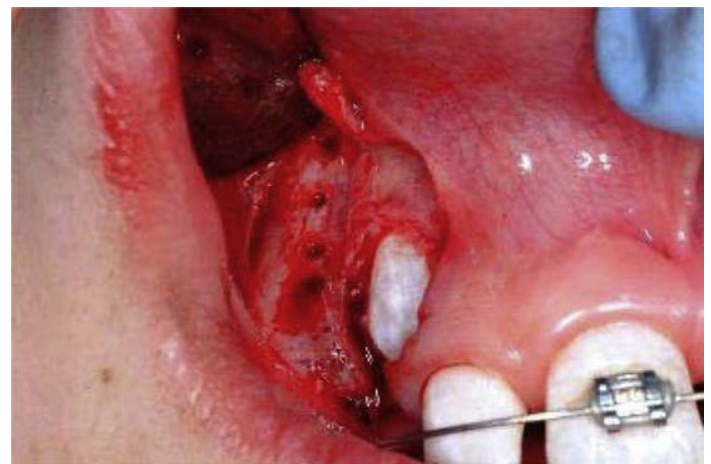

Figure 5: Corticotomy can be used to expedite the movement of individual teeth (impacted canine in this case).

Disadvantages

- Extra-surgical cost.

- Mildly invasive surgical procedure, and like all surgeries, it has its risks. Post-surgical crestal bone loss and recession may occur.
- Some pain and swelling is expected, and the possibility of infection.
- Not applicable to all cases, proper case selection is necessary to attain a good result. Maxillary and mandibular arch decrowding with normal skeletal relationship and incisors retraction are the main indications.

Conclusion

PAOO is relatively new procedure; only few cases were reported in the literature. Controlled clinical and histological studies are needed to understand the biology of tooth movement with this procedure, the effect on teeth and bone, post-retention stability, measuring the volume of mature bone formation, and determining the status of the periodontium and roots after treatment. PAOO is promising procedure; it may be a solid part of the future of orthodontic treatment. This procedure enhances and accelerates tooth movement if followed by a short period of orthodontic appliance treatment. PAOO effects and mechanism were confirmed by recent well designed histological studies. However, further randomized testing in humans is still needed to confirm the claimed advantages of this technique and to evaluate the long term effects.

References

1. Mathews DP, Kokich VG. Managing treatment for the orthodontic patient with periodontal problems. *Semin Orthod* [Internet]. 1997;3(1):21–38.
2. Ong MMA, Wang H-L. Periodontic and orthodontic treatment in adults. *Am J Orthod Dentofacial Orthop* [Internet]. 2002;122(4):420–8.
3. Düker J. Experimental animal research into segmental alveolar movement after corticotomy. *J Maxillofac Surg* [Internet]. 1975 Jun;3(2):81–4.
4. Yaffe A, Fine N, Binderman I. Regional accelerated phenomenon in the mandible following mucoperiosteal flap surgery. *J Periodontol* [Internet]. 1994 Jan;65(1):79–83.
5. Verna C. The rate and the type of orthodontic tooth movement is influenced by bone turnover in a rat model. *Eur J Orthod* [Internet]. 2000;22(4):343–52.
6. Verna C, Melsen B. Tissue reaction to orthodontic tooth movement in different bone turnover conditions. *Orthod Craniofac Res* [Internet]. 2003;6(3):155–63.
7. Goldie RS, King GJ. Root resorption and tooth movement in orthodontically treated, calcium-deficient, and lactating rats. *Am J Orthod* [Internet]. 1984 May;85(5):424–30.
8. Böhl M von, von Böhl M, Maltha JC, Den Hoff JWV, Kuijpers-Jagtman AM. Focal hyalinization during experimental tooth movement in beagle dogs. *Am J Orthod Dentofacial Orthop* [Internet]. 2004;125(5):615–23.
9. Wilcko MT, Thomas Wilcko M, Wilcko WM, Pulver JJ, Bissada NF, Bouquot JE. Accelerated Osteogenic Orthodontics Technique: A 1-Stage Surgically Facilitated Rapid Orthodontic Technique With Alveolar Augmentation. *J Oral Maxillofac Surg* [Internet]. 2009;67(10):2149–59.
10. Ferguson DJ, Thomas Wilcko M, Wilcko WM, Makki L. Scope of treatment with periodontally accelerated osteogenic orthodontics therapy. *Semin Orthod* [Internet]. 2015;21(3):176–86.
11. Nowzari H, Yorita FK, Chang H-C. Periodontally accelerated osteogenic orthodontics combined with autogenous bone grafting. *Compend Contin Educ Dent* [Internet]. 2008 May;29(4):200–6; quiz 207, 218.

12. Wilcko MT, Thomas Wilcko M, Wilcko WM, Bissada NF. An Evidence-Based Analysis of Periodontally Accelerated Orthodontic and Osteogenic Techniques: A Synthesis of Scientific Perspectives. *Semin Orthod* [Internet]. 2008;14(4):305–16.
13. Ferguson D, Mazumder U, Makki L, Wilcko M, Wilcko W. Mandibular incisor position changes do not explain increase in keratinized gingiva height after periodontally accelerated osteogenic orthodontics. *APOS Trends in Orthodontics* [Internet]. 2017;7(4):168.
14. Ferguson D, Machado I, Wilcko M, Wilcko W. Root resorption following periodontally accelerated osteogenic orthodontics. *APOS Trends in Orthodontics* [Internet]. 2016;6(2):78.
15. Ren A, Lv T, Kang N, Zhao B, Chen Y, Bai D. Rapid orthodontic tooth movement aided by alveolar surgery in beagles. *Am J Orthod Dentofacial Orthop* [Internet]. 2007 Feb;131(2):160.e1–10.
16. Mostafa YA, Fayed MMS, Mehanni S, ElBokle NN, Heider AM. Comparison of corticotomy-facilitated vs standard tooth-movement techniques in dogs with miniscrews as anchor units. *Am J Orthod Dentofacial Orthop* [Internet]. 2009;136(4):570–7.
17. Little RM. Stability and Relapse of Dental Arch Alignment. *Br J Orthod* [Internet]. 1990;17(3):235–41.
18. McFadden WM, Engstrom C, Engstrom H, Anholm JM. A study of the relationship between incisor intrusion and root shortening. *Am J Orthod Dentofacial Orthop* [Internet]. 1989 Nov;96(5):390–6.
19. Fischer TJ. Orthodontic treatment acceleration with corticotomy-assisted exposure of palatally impacted canines. *Angle Orthod* [Internet]. 2007 May;77(3):417–20.
20. Vanarsdall RL Jr. Transverse dimension and long-term stability. *Semin Orthod* [Internet]. 1999 Sep;5(3):171–80.
21. Yen SL-K, -K Yen SL, Yamashita D-D, Kim T-H, Baek H-S, Gross J. Closure of an unusually large palatal fistula in a cleft patient by bony transport and corticotomy-assisted expansion. *J Oral Maxillofac Surg* [Internet]. 2003;61(11):1346–50.
22. Kanno T, Mitsugi M, Furuki Y, Kozato S, Ayasaka N, Mori H. Corticotomy and compression osteogenesis in the posterior maxilla for treating severe anterior open bite. *Int J Oral Maxillofac Surg* [Internet]. 2007 Apr;36(4):354–7.
23. Moon C-H, Wee J-U, Lee H-S. Intrusion of overerupted molars by corticotomy and orthodontic skeletal anchorage. *Angle Orthod* [Internet]. 2007 Nov;77(6):1119–25.
24. Oliveira DD, de Oliveira BF, de Araújo Brito HH, de Souza MMG, Medeiros PJ. Selective alveolar corticotomy to intrude overerupted molars. *Am J Orthod Dentofacial Orthop* [Internet]. 2008 Jun;133(6):902–8.
25. Hwang HS, Lee KH. Intrusion of overerupted molars by corticotomy and magnets. *Am J Orthod Dentofacial Orthop* [Internet]. 2001 Aug;120(2):209–16.
26. Iino S, Sakoda S, Miyawaki S. An adult bimaxillary protrusion treated with corticotomy-facilitated orthodontics and titanium miniplates. *Angle Orthod* [Internet]. 2006 Nov;76(6):1074–82.
27. Spina R, Caiazzo A, Gracco A, Siciliani G. The use of segmental corticotomy to enhance molar distalization. *J Clin Orthod* [Internet]. 2007 Nov;41(11):693–9.
28. Lee J-K, Chung K-R, Baek S-H. Treatment outcomes

of orthodontic treatment, corticotomy-assisted orthodontic treatment, and anterior segmental osteotomy for bimaxillary dentoalveolar protrusion. *Plast Reconstr Surg* [Internet]. 2007 Sep 15;120(4):1027–36.

29. Harry MR, Sims MR. Root resorption in bicuspid intrusion. A scanning electron microscope study. *Angle Orthod* [Internet]. 1982 Jul;52(3):235–58.