

**Socket Shield Technique: Boon to Implant Dentistry –A Review**

<sup>1</sup>Dr. Rahul Sharma, MDS, Registrar Prosthodontics Saudi Commission of Health Specialities Prestige Dental Centre  
Hafar albatin Kingdom of Saudi Arabia

<sup>2</sup>Dr. Karunakar Shetty, MDS Associate Professor IBN Sina National College of Medical Studies Jeddah Saudi Arabia

<sup>3</sup>Dr Salem Elharazeen, BDS Clinical Supervisor Dental Clinics IBN Sina National College of Medical Sciences Jeddah,  
Saudi Arabia

<sup>4</sup>Zaher Tawfik Elshoubki, Intern Dentistry Program IBN Sina National College of Medical Sciences Jeddah, Saudi Arabia

<sup>5</sup>Abdulrahman Ahmed Almuntashiri, Intern Dentistry Program IBN Sina National College of Medical Sciences Jeddah,  
Saudi Arabia

**Corresponding Author:** Dr. Rahul Sharma, MDS, Registrar Prosthodontics Saudi Commission of Health Specialities  
Prestige Dental Centre Hafar albatin Kingdom of Saudi Arabia

**Type of Publication:** Review Paper

**Conflicts of Interest:** Nil

**Abstract**

Immediate implant placement is a routine procedure in modern implant dentistry. After extraction residual socket undergoes a series of changes leads to the resorption of hard and soft tissue contours ends with compromised aesthetics. Many socket preservation techniques have been practiced from decades. The new socket shield technique gains popularity which includes the sectioning of the remaining root and retaining of the buccal fragment aiming to reduce resorption. This review literature illustrate the procedure, classification, advantages and limitations of this technique based on the available evidences to judge its clinical outcomes and biological acceptability.

**Keywords:** socket preservation, immediate implant placement, tooth retention, socket shield

**Introduction**

Immediate implant placement poses many challenges to the clinician when comes in the aesthetic zone. Atraumatic extraction of a tooth with immediate

implant placement results in the loss of buccal bone, both vertically and horizontally as well as flattening of the interproximal bony scallop resulting in a complicated rehabilitation. The loss of supporting bone followed by the apical migration of soft tissue results in poor esthetic with black triangles between teeth. This presents a very challenging situation in restoring the missing tooth especially in the maxillary anterior region[1]. To overcome such situations, several techniques have been proposed, including minimally-traumatic tooth extraction, ridge preservation by socket grafting, immediate implant placement with provisionalization, augmentation of the hard- and soft-tissues, and so forth. However, each of these has their own benefits as well as limitations[2-3]. Thus, the concept of partial extraction therapy (PET) has been introduced as an attempt to preserve the patient's tooth or part intact with its attachment apparatus. Among this group of treatments, the socket-shield technique first reported by Hürzeler *et al.* proposed the intentional

preparation of a single-rooted tooth and immediate implant placement palatal to it, “shielding” the buccofacial ridge from resorbing and receding[4]. Also, modified socket shield technique is suggested where the shield is located in the interproximal area than the buccal area to preserve inter-implant papilla[5].

The application of socket shield technique involves the protection of buccal fragment of the tooth by modifying the root of the tooth indicated for extraction. The modification of the tooth should be performed in a fashion that remaining facial root fragment remain intact in situ with relation to buccal bone. The periodontal attachment apparatus along with vascularization, attachment fibers and cementum of root of the prepared tooth is intended to remain vital to prevent the post-operative hard and soft tissue loss[6]. This technique is indicated in the situation like immediate implant placement where buccofacial bone plate of extraction socket need to be preserved, in vertical fracture cases without underlying pathology and to preserve the papilla between the dental implants[5] and contraindications involves medically compromised patients, and situations when loss of buccal bone due to vertical fracture, loss of buccal bone due to periodontitis, lack of bone beyond the apex, Caries on root fragment[6].

#### **Classification of Socket Shield Technique [7]**

This classification has been proposed depending on the position of the shield in the socket.

##### **Type I: Buccal shield**

A case can be classified as buccal shield when the shield lies only in buccal part of the socket, (between proximal line angles of tooth). It is indicated in single edentulous site with both mesial and distal tooth present

##### **Type II: Full C buccal shield**

A case can be classified as Full C Buccal shield when the shield lies in buccal part and the interproximal part on both sides of the socket.

This shield design is recommended for the following clinical scenarios:

- Existing implant on either side of the proposed site
- Missing tooth on either side without an implant
- Having implant on one side and missing tooth on the other side.

##### **Type III: Half C buccal shield**

A case can be classified as half C buccal shield when the shield lies in buccal part and one of the interproximal part. This design is recommended when there is tooth on one side and implant or a missing tooth on the other side

##### **Type IV: Interproximal shield**

A case can be classified as interproximal shield when shield lies only in mesial or distal part of the socket. This design is indicated when there is buccal bone resorption requiring graft, and there is an adjacent side with missing tooth or an implant. Extraction of the complete tooth in such cases may lead to loss of the valuable interproximal bone.

##### **Type V: Lingual-palatal shield**

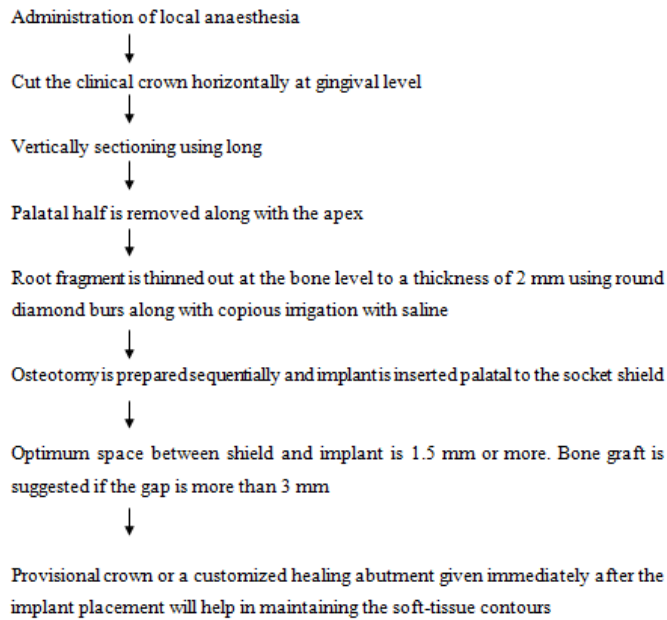
A case can be classified as Lingual-Palatal shield when the shield lies on the lingual or palatal side of the socket. This type of shield design has few indications but could be considered for maxillary molars.

##### **Type VI: Multiple buccal shields**

A case can be classified as multiple buccal shields when it has two or more shield in the socket. It is indicated in cases with a vertical root fracture. There is evidence to show bone deposition in between fractured roots which could assist in holding the two fragments in place.

##### **Procedure**

The surgical steps to perform socket shield technique summarized as follows [7,8].



### Advantages of socket-shield technique

This technique offers high degree of aesthetic outcome because of maintaining hard and soft profile by retaining a part of the root. It minimizes the additional cost of hard and soft tissue augmentation procedures. Intact buccal shield also guides in placing implants in correct position[7]. Moreover in the situations of adjacent implant, interdental papilla can be preserved by interdental proximal socket shield.

### Limitations of socket-shield technique

The case selection for this technique is very crucial if remaining root has any underlying pathology or mobility, can lead to further complications. The clinician needs to have a high degree of clinical skills. This procedure needs to be performed patiently to avoid mobility in the shield. If the shield becomes mobile during surgery, it is removed, and the conventional immediate implant placement or the grafting procedure is to be done. Long term behaviour of the buccal shield has not yet been completely clarified[9].

### Discussion

In the past it has been observed that retaining root fragments in situ and keeping them covered by mucosa

serves as an alternative technique for alveolar ridge preservation. Studies supported the fact that root fragments assisted in both the preservation of root volume as well as in vertical bone growth coronally. Thus, a planned preservation of root fragments appears to be an approach towards successful alveolar ridge preservation. From decades various histological experiments were carried out on both animals and human beings, to test the outcome of implants placed in proximity to alveolar bone. Parlar et al. were the first to place nine implants in the center of prepared hollow chambers of decoronated roots having slits at the periphery in nine mongrel dogs[10]. Four months later, histological examination of the specimens showed newly formed periodontal ligament, alveolar bone, and root cementum in the space between the implant and the wall of the dentin chamber. Cellular cementum was deposited on the surfaces of two out of nine implants as well as on the dentinal walls of the chamber. One implant had an exposed edge whereas two implants showed clinical signs of inflammation[10]. Hurzeler et al. intentionally left a buccal portion of the remnant root coated with enamel matrix derivative (Emdogain, Straumann), to preserve the buccal cortical plate from resorption during an immediate implant placement[4]. Baumer et al. further investigated this technique, his histologic evaluation showed osseointegration and bone formation between the fragments and the implants after 4 months of healing. They proposed that the socket-shield prevented the resorption of the buccal cortical plate after tooth extraction [11]. A case-control study on the socket-shield was carried out by Abadzhiev et al. where 26 implants were immediately placed in 25 patients. Though the socket-shield group had better results in terms of bone loss, esthetics and soft tissue volume, a mean bone loss of 0.8mm (2%) was noted at 24 months[12]. Kan and

Rungcharassaeng in 2013 carried out an immediate implant placement in a patient where the implant was in contact with the tooth fragment. The implant was immediately loaded and no adverse reaction was seen after 12 months[13]. Chen and Pan in 2013 published their clinical case report in which they carried out an immediate implant placement in proximity to remaining tooth fragment and delayed loading was done after 4 months. They observed 0.72mm horizontal loss on buccal alveolar bone after 12 months[14]. Troiano et al. in 2014 placed 10 implants in 7 patients immediately and in contact with the retained root fragment. Loading was delayed by 3 months. An average bone loss of  $1.3\pm 0.2$  mm was observed after 6 months of follow up [15]. In 2015 Wadhvani et al. mentioned in his case report the immediate placement of an implant following socket shield procedure. Loading was delayed by 4 months no negative result after 4 months of follow up[16]. Similar positive experience have been reported by, Mitsias et al[17], Lagas et al[18], Engelke et al[19], Al Dary & Al Hadidi[20].

The requirement was a simple economical technique which can be carried out with minimum surgical intervention. Socket shield technique allowed us to preserve the bone at the proposed implant site, while the thin and prone to resorption buccal bundle bone was retained[21,22]. The lingual portions of the bundle bone are thicker and less prone to atrophy. In addition, vital anatomical structures, such as blood vessels and nerves, are found especially in the lateral tooth area of the mandible. Thus, a lingual socket shield technique seems to be complicated as well as risky. The retained root fragment should be reduced to the level of the height of the alveolar ridge to prevent perforation of the healing buccal mucosa. The buccal shield should be attempted to achieve an implant position where all boundaries are formed by bone, accomplishing a

successful osseointegration. Recently, complications of infection and bone loss were also recorded when implants were placed in contact with left over root debris at the time of extraction. Therefore it will not be too early to think that the socket-shield is full proof and does pose a risk of infection to implants placed in proximity. Bone loss was also found in few cases, especially on the buccal aspect[15]. Failure of the socket-shield due to infection and deficiency of alveolar ridge was also reported leading to loss of the buccal bone that was to be preserved, exposing the implant surface. In spite of diverse implants, similar success results were observed establishing the fact that the implant surface or design may not be so critical in the success or failure of this technique [23].

### Conclusion

With the lack of sufficient literature and better histological study designs, the long-term prognosis and success of the socket-shield technique stands unclear. It seems that if appropriate case selection with good clinician expertise, the SST could minimize the resorption of the buccal tissues after the tooth extraction and helps in restoring the aesthetics after immediate implant placement.

### Reference

1. Salama H, Salama MA, Garber D, Adar P. The interproximal height of bone: A guidepost to predictable aesthetic strategies and soft tissue contours in anterior tooth replacement. *Pract Periodontics Aesthet Dent* 1998;10:1131-41
2. Glocker M, Attin T, Schmidlin R. Ridge preservation with modified "Socket-shield" technique: A methodological case series. *Dent J* 2014;2:11-21
3. Chereil F, Etienne D. Papilla preservation between two implants: A modified socket-shield technique to maintain the scalloped anatomy? A case report. *Quintessence Int* 2014;45:23-30.

4. Hürzeler MB, Zühr O, Schupbach P, Rebele SF, Emmanouilidis N, Fickl S, et al. The socket-shield technique: A proof-of-principle report. *J Clin Periodontol* 2010;37:855-62.
5. Glocker M, Attin T, Schmidlin PR. Ridge preservation with modified “socket-shield” technique: a methodological case series. *Dentistry Journal*. 2014 Jan 23;2(1):11-21.
6. Gluckman H, Du Toit J, Salama M. The socket-shield technique to support the buccofacial tissues at immediate implant placement. *Int Dentistry*. 2015;5:6-14.
7. Payal Rajender Kumar , Udatta Kher. Shield the socket: Procedure, case report and classification. *J Indian Soc Periodontol*.2018; 22(3): 266–272.
8. Samina Mujawar., Nihal Devkar., Akshay Vibhute., Mugdha Deshpande and Pradnya Mali. Socket shield technique: a review. *International Journal of Recent Scientific Research* 2018 ;9 6(F): 27612-27615,
9. Anas B, Shenoy KK. Socket Shield Technique-A Neoteric Approach in Ridge Preservation. *Sch. J. Dent.Sci.*, 2017; 4(3):125-8
10. Parlar, A, Bosshardt, DD., Unsal, B., Cetiner, D., Haytac, C. and Lang, NP. 2005. New formation of periodontal tissues around titanium implants in a novel dentin chamber model. *Clin Oral Implants Res.*, 16(3):259-67.
11. Baumer, D., Zühr, O., Rebele, S., Schneider, D., Schupbach, P. and Hurzeler, M. 2015. The socket-shield technique: first histological, clinical, and volumetrical observations after separation of the buccal tooth segment - a pilot study. *Clin Implant Dent Relat Res.*, 17(1):71-82.
12. Abadzhiev, MN, P. and Velcheva, P. 2014. Conventional immediate implant placement and immediate placement with socket-shield technique – Which is better. *Int J Clin Med Res.*, 1(5):176-80.
13. Kan, JY and Rungcharassaeng, K. 2013. Proximal socket shield for interimplant papilla preservation in the esthetic zone. *Int J Periodontics Restorative Dent.*, 33(1):e24-31.
14. Chen, C. and Pan, Y. 2013. Socket Shield Technique for Ridge Preservation: A Case Report. *J Prosthodont Implantol.*, 2(2):16-21.
15. Troiano, M., Benincasa, M., Sánchez, P. and Calvo-Guirado, J. 2014. Bundle bone preservation with Root-T-Belt: Case study. *Ann Oral Maxillofac Surg.*, 2(1):7.
16. Wadhvani, P., Goyal, S., Tiwari, S., Syed, S., Paul, T., Komal, A. 2015. Socket Shield Technique: A New Concept of Ridge Preservation. *Asian J Oral Health Allied Sci.*, 5(2):55-8.
17. Mitsias ME, Siormpas KD, Kontsiotou-Siormpa E, Prasad H, Garber D, Kotsakis GA. A Step-by-Step Description of PDL-Mediated Ridge Preservation for Immediate Implant Rehabilitation in the Esthetic Region. *The International journal of periodontics & restorative dentistry*. 2015;35(6):835 41.
18. Lagas LJ, Pepplinkhuizen JJ, Bergé SJ, Meijer GJ. Implanteren in de esthetische zone: de socketshieldschieldtechniek. *Ned Tijdschr Tandheelk*. 2015; 122:33-6.
19. Engelke W, Beltrán V, Decco O, Valdivia-Gandur I, Navarro P, Fuentes R. Changes in morphology of alveolar buccal walls following atraumatic internal root fragmentation.
20. Al Dary H, Al Hadidi A. The Socket Shield Technique using Bone Trepine: A Case Report. *International Journal of Dentistry and Oral Science*. 2015 Nov 5;5:1-5.

21. Schropp, L., Wenzel, A., Kostopoulos, L. and Karring, T. 2003. Bone healing and soft tissue contour changes following single-tooth extraction: a clinical and radiographic 12-month prospective study. *Int J Periodontics Restorative Dent.*, 23(4):313-323.
22. Araujo, M., Linder, E. and Lindhe, J. 2009. Effect of a xenograft on early bone formation in extraction sockets: an experimental study in dog. *Clinical Oral Implants Research*, 20, 1–6.
23. Angana pal, Dipanjit singh , Atul bhandari , Pratibha rawat, Tarun kumar Swarnakar, Arka Swarnakar . The socket shield technique. *International journal of current research* 2018;10(3):67200-67204.