

**CT Study of Development of Mandibular Third Molars in 18 Year Old North Indian Males**

Dr. Rishu Garg, MDS, Assistant Prof, Dept. of Dentistry, Maharaja Agrasen Medical College , Agroha.

Dr. Anoop Grover, MDS, Associate Prof and Head, Dept. of Dentistry, Maharaja Agrasen Medical College, Agroha.

Dr. Gazal Mehta, BDS, Resident, Dept. of Dentistry, Maharaja Agrasen Medical College, Agroha.

Dr. Pardaman Setia, MD, Associate Prof, Dept. of Radiology, Maharaja Agrasen Medical College, Agroha.

**Corresponding Author:** Dr. Anoop Grover, MDS, Associate Prof and Head, Dept. of Dentistry, Maharaja Agrasen Medical College, Agroha.

**Type of Publication:** Original Research paper

**Conflicts of Interest:** Nil

**Abstract**

There is an increased need in the legal and social systems to establish an efficient, reliable and safe process that is able to correctly estimate age when there are no genuine documents or date of birth records.

Legal consequences can be quite different if a subject of unknown age is judged to be a juvenile or an adult.

The aim of this study was to investigate development of third molars in 18 year old North Indian male population by means of CT scans and 3D software imaging.

A retrospective analysis of CT scans of 50 patients aged 18 years at the time of their scan was conducted, and the developmental stages of the left third molars were evaluated using Demirjian's classification. Demirjian's classification system distinguished eight stages of crown and root development (Stages A-H). The percentile distributions were recorded for each stage of development and variations for different stages were noted. The developmental and physiological changes of the tooth can be correlated to chronological age. The aim of the present study was to investigate the developmental stages of permanent mandibular third molars in 18 year old North Indian male population.

**Keywords:** Root formation, third molars, children, odontology, dental age, tooth formation, age

determination, juvenile. Forensic, orthopedic, pediatric, Demirjian's classification, tooth development, North Indian.

**Introduction**

Many studies have been conducted utilizing the degree of mineralization and development of the third molars as a predictive element of age [1,2]. Age of young children can be assessed with greater accuracy because more teeth are undergoing formation and the intervals between morphologic stages are shorter and more precise [3]. One of the most daunting challenges for the forensic experts is that the suspect in the court of law is an adult or a minor. In India, age estimation of the legal adult age of 18 years is critical as a large section of population of India especially of lower socio economic background and of the rural areas there is a stark lack of birth records and verifiable documents for proof of age

Late in adolescence, after formation of the premolars and canines, only the third molars continue to form. [4]. The single compelling reason to rely on third molar formation to estimate chronological age is that there are very few alternative methods during the interval roughly between the middle teens and early 20s. All of the other teeth have erupted and completed root formation [5,6]

The development of teeth can be broadly divided into two parts: Formation of crowns and roots and emergence of teeth. The formation of teeth is much more resistant to environmental factor than the emergence.[7] The root formation is not complete when the crown emerges and formation of root dentin and enamel continues. Since delay in ossification of hand and wrist bones often coincide with arrest in tooth formation a simple dental radiograph maybe useful in detection and diagnosis of pediatric orthopedic conditions. The development and formation of the teeth occur in a constant and gradual manner over a period of time, starting in the foetal stage and lasting up to the beginning of the third decade of life. It is a constant and universal process among populations of different origins, although there may be cross-population variations in the progress or delay of the mineralization process.[8,9]Teeth show great resistance to postmortem alterations caused by humidity, high temperature, microbial activities, and mechanical forces.[10] Also, developmental and physiological changes of the tooth can be correlated to chronological age. Hence, for all of these reasons teeth can be better predictors of age compared to bone. [11] Dental age estimation has gained acceptance because it is less variable when compared to other skeletal and sexual maturity indicators.[ The highest reliability for dental age estimation occurs when several teeth are in development (until the age of 18-14 years), and the most common methods in use have been tested by several researchers both theoretically and in practice. For accuracy in age estimation it is required to precisely stage the chronological development of teeth in various ethnic populations. This study aims to investigate the developmental stages of mandibular third molars in 18 year old north Indian population

## **Materials and methods**

### **Study design**

This was a retrospective cross sectional study of CT scans of mandibular third molars of eighteen year old patients. These were good quality scans of sections of left mandibular third molars in CT scans taken from Department of Radiology at Maharaja Agrasen Medical College, Agroha. Haryana. Sample size of 50 males who age was stated as eighteen years at the time of CT scan were selected. CT scan sections that were unclear or that showed gross pathology or previous treatment were excluded. Inclusion criteria were clear image of third molar and availability of age of patient at time of scan. Teeth with metal restorations were excluded on CT because of the possibility of artifacts. The teeth were scanned and stage of development was assessed with 3D software imaging.(figures1 and 2)

### **Scoring**

We scored the degree of third molar development using the Demirjian's classification. Demirjian's classification system distinguished eight stages of crown and root development (Stages A-H). Stages A, B, C, and D represented crown formation from the appearance of the cusp to the crown completion, and Stages E, F, G, and H showed representative root formations from radicular bifurcation to apical closing (figure 3). The stages proposed by Demirjian were based on changes in shape rather than length measurements.[12]

In stage A cusp tips are mineralized but have not yet coalesced. Stage B mineralized cusps are united so the mature coronal morphology is well-defined. Stage C: end of the formation of enamel and beginning of the deposition of dentine. D: Formation of the crown to the enamel-cement junction. E: The longitude of the root is shorter than the latitude of the crown. F: The longitude of the root is equal to or greater than that of the crown. G:

The growth of the root has ended; the apical orifice remains open. Stage H is closure of the apical orifice.

**Results and Discussion**

We investigated the development of the third molars in 18-year-old north Indian population by using the Demirjian’s classification. For evaluating the degree of maturation of teeth Demirjian’s method [13], have been widely used by many researchers because of its superior objectiveness by using only anatomical features.

Olze et al. validated five common classification systems for assessing the mineralization of third molars and concluded that Demirjian’s stages should be used to evaluate third molars[14]. The various stages of root development of left mandibular third molars in our sample of 50 male subjects of age 18 is recorded in Table 1. According to Thevissen et al the estimation of dental age, particularly in young individuals, should be based on data collected from an appropriate population.[15] In our current study despite variability, there was a clear correspondence between the developmental stage. A high percentile of third molars roots in our sample population are seen to be in stages E and F of Demirjian’s Classification. (Figure 4)

**Figures and Tables**

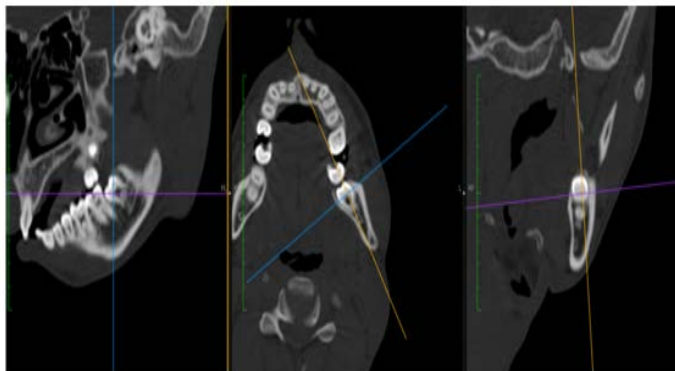


Figure1: 3D CT scan imaging of third molar with various axes

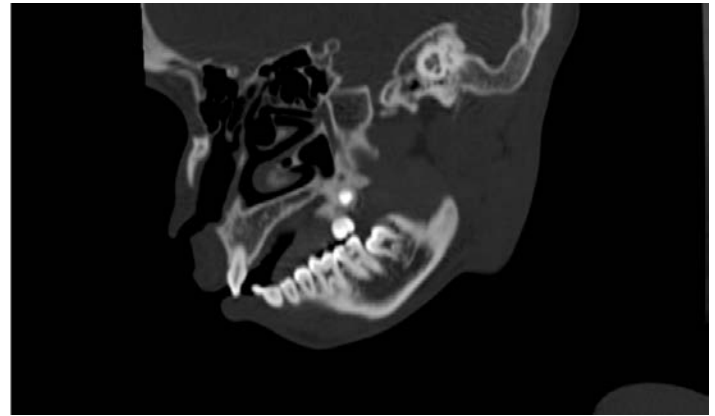

Figure 2: 3D CT scan imaging of third molar.

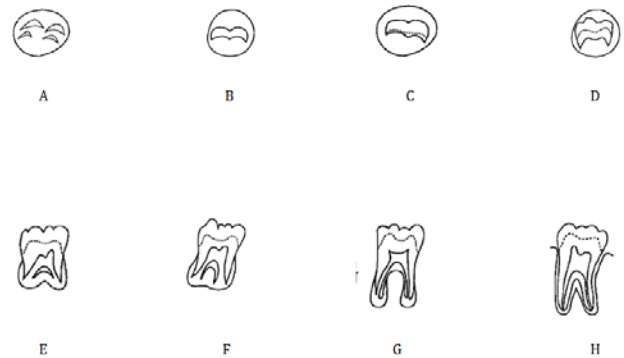


Figure 3. Demirjian's classification system distinguished eight stages of crown and root development (Stages A-H).

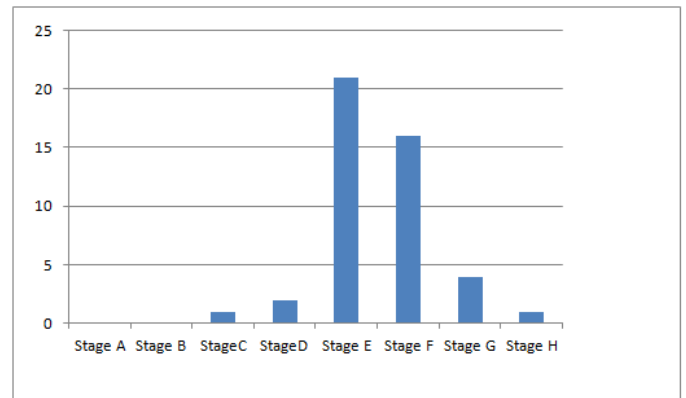


Figure 4: Distribution Graph

Stage	A	B	C	D	E	F	G	H	NR
(n=30)	0	0	1	2	21	16	4	1	6

Table 1: Distribution of number of subjects (n=50) in various stages of Demirjian’s Classification for development of left mandibular third molar. NR= not recorded.

## Conclusion

The developmental stage of the third molars clearly showed a high degree of uniformity in this age group and this may be used for correlation with age. In conclusion, the present investigation could provide reference data for third molar development in the North Indian population and maybe used in wider studies of tooth development and age prediction using dental radiographs for forensic and medico-legal purposes.

Limitations include the possible influence of external factors such as climate, environment, ethnic variation, socioeconomic status and internal factors like genetics, hormonal influences and nutritional deficiencies during growth.

## References

1. Martin-de las Heras S, García-Fortea P, Ortega A, Zodocovich S, Valenzuela A. Third molar development according to chronological age in populations from Spanish and Magrebian origin. *Forensic Sci Int.* 2008;174:47-53.
2. Bolaños MV, Moussa H, Manrique MC, Bolaños MJ. Radiographic evaluation of third molar development in Spanish children and young people. *Forensic Sci Int.* 2003;133:212-9.
3. Hagg, U. and Matsson, L., "Dental Maturity as an Indicator of Chronologic Age: The Accuracy and Precision of Three Methods," *European Journal of Orthodontics*, Vol. 7, No. 1, 1985, pp. 25-34
4. Hellman, M., "Our Third Molar Teeth, Their Eruption, Presence, and Absence," *Dental Cosmos*, Vol. 78, No. 7, 1936, pp. 750-762.
5. Demirjian, A., Goldstein, H., and Tanner, J. M., "A New System of Dental Age Assessment," *Human Biology*, Vol. 45, No. 2, 1973, pp. 211-227.
6. Moorrees, C. F. A., Fanning, E. A., and Hunt, E. E., Jr., "Age Variation of Formation Stages in Ten Permanent Teeth," *Journal of Dental Research*, Vol. 42, No. 6, 1963, pp. 1450-1502.
7. Ash M, Nelson SJ. *Wheeler's Dental Anatomy, Physiology and Occlusion*. Eighth Ed.
8. Mincer HH, Harris EF, Berryman HE. The ABFO study of third molar development and its use as an estimator of chronological age. *J Forensic Sci.* 1993;38:379-90.
9. Martin-de las Heras S, García-Fortea P, Ortega A, Zodocovich S, Valenzuela A. Third molar development according to chronological age in populations from Spanish and Magrebian origin. *Forensic Sci Int.* 2008;174:47-53.
10. Meinel A, Huber CD, Tangl S, Gruber GM, Teschler-Nicola M, Watzek G. Comparison of the validity of three dental methods for the estimation of age at death. *Forensic Sci Int* 2008;178:96-105.
11. Reppien K, Sejrsen B, Lynnerup N. Evaluation of post-mortem estimated dental age versus real age: A retrospective 21-year survey. *Forensic Sci Int* 2006;159S: S84-8
12. Olze A, van Niekerk P, Schmidt S, Wernecke KD, Rösing FW, Geserick G, et al. Studies on the progress of third-molar mineralisation in a Black African population. *Homo.* 2006;57:209–217
13. Demirjian A, Goldstein H, Tanner JM (1973) A new system of dental age assessment. *Hum Biol* 45:211–217
14. Olze A, Bilang D, Schmidt S, Wernecke KD, Geserick G, Schmeling A (2005) Validation of common classification systems for assessing the mineralization of third molars. *Int J Leg Med* 119:22–26
15. Thevissen PW, Pittayapat P, Fieuws S, Willems G. Estimating age of majority on third molars developmental stages in young adults from Thailand using a modified scoring technique. *J Forensic Sci.* 2009;54:428–432.